

## CENTRAL RETINAL ARTERY OCCLUSION FOLLOWING PERIBULBAR ANESTHESIA FOR PTERYGIUM EXCISION

M. E. GYASI<sup>1</sup>, R. A. KODJO<sup>1</sup> and W. M. AMOAKU<sup>2</sup>

<sup>1</sup>Emmanuel Eye Centre, Accra, Ghana. <sup>2</sup>Ophthalmology and Vision Sciences, University of Nottingham, Nottingham, United Kingdom

*Corresponding Author: Dr Michael E. Gyasi*

*Email: mikegyasi@yahoo.co.uk*

*Conflict of Interest: None declared*

### SUMMARY

Pterygium is a common ocular surface pathology in tropical environments. In the early stages, it may be managed medically with topical anti-inflammatory agents and ocular lubricants. However as the disease progresses, surgical excision becomes necessary and several anaesthetic methods may be used to assist this. We share our experience of a 30-year old woman who underwent uneventful pterygium excision using peribulbar lignocain injection with adrenaline. She developed sudden blindness due to central retinal artery occlusion with macular infarction. While peribulbar anaesthesia is generally safe, a remote risk of retinal vascular accident exists and its routine use should be done with caution. Where possible topical anaesthesia with or without intra-lesional injection be employed.

**Keywords:** Central retinal artery occlusion, macular infarction, peribulbar anaesthesia, pterygium, retinal ischemia

### INTRODUCTION

Effective anaesthesia for major intraocular and to some extent ocular surface procedures in the past had been achieved using retrobulbar anaesthesia. This technique however has an increased risk of direct damage to the optic nerve. Such damage includes central retinal artery occlusion (CRAO), combined CRAO and central retinal vein occlusion (CRVO) and Anterior Ischemic Optic Neuropathy (AION). These complications are thought to be due to direct needle penetration of the optic nerve, mechanical compression, drug toxicity, or from the effects of adjunct vasoconstrictor agents used in anaesthetic solutions, among other causes.<sup>1,2</sup>

To reduce the incidence of such anaesthesia-related complications, retrobulbar anaesthesia has become largely replaced with other modalities such as topical, intracameral and peribulbar anaesthesia. While these new modalities are much safer than retrobulbar anaesthesia, a handful of complications have been reported in the literature.

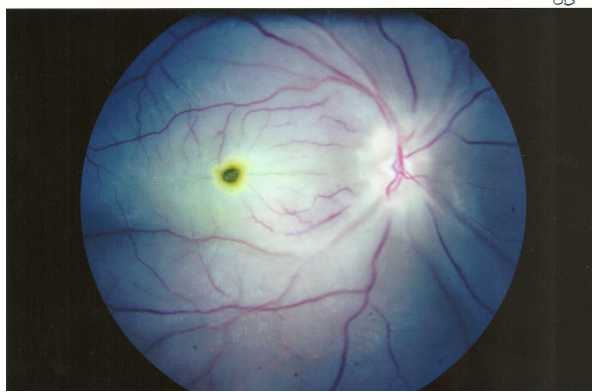
In this report, we present a case of CRAO in a young female patient who underwent uneventful pterygium excision, under peribulbar anaesthesia and caution the use of such anaesthetic techniques in minor procedures.

### Case Report

A 30year old woman presented with prickly pains, ocular discomfort and a wing-shaped conjunctival mass extending onto the medial aspects of her right cornea. The best corrected visual acuities (BCVA) were 6/6, and the intraocular pressures (IOP) 16mmHg in each eye. Tear break-up time in the affected eye was 8 seconds and the apex of the mass estimated between the limbus and pupillary margin. Fundus assessment and other ocular examination findings were all normal; her general medical history was unremarkable and physical examination normal. A diagnosis of Stage-2 pterygium was made and the patient was scheduled for pterygium excision with adjunctive Mitomycin-C, using sponge application technique.

Before surgery, topical ciprofloxacin 0.3% was applied and a preparation of 4ml lidocaine 2% in 1:100,000 adrenaline was injected through a single point in the lower eyelid immediately above the inferior orbital rim at the junction of the medial two thirds and lateral one third and running parallel to the orbital floor, 1cm into the peribulbar space, using 25G needle. The eye was compressed for 10 minutes using a pressure-reducing 'pinky ball'; the ocular surface was irrigated with 5 % povidone iodine and a Barraquer wire speculum inserted. Pterygium excision using the bare sclera procedure was performed and topical application of Mitomycin-C 0.2% applied for 3minutes and thereafter irrigated with 20cc of Ringers Lactate.

After the surgery, topical 2.5% Betadine Iodine was used, a strip of Dexamycin ointment applied and the eye lightly padded with eye shield (routine procedure for all surgical cases).



**Figure 1** Right eye showing macular infarction with a Cherry Red spot

At the first post-operative day, the patient complained of loss of vision in the operated eye. Her BCVA was measured at Hand Motion (HM) close to face and the IOP 20mmHg in the affected eye with the conjunctiva mildly hyperaemic. Funduscopy by indirect biomicroscopy showed a whitened retina at the posterior pole, a classical cherry red spot and sluggish arterial blood flow. No peribulbar haemorrhage, lid haemorrhage nor proptosis was observed and extra ocular muscle movements were full. Patient was put on routine topical Maxitrol every two hours and tapered off gradually. Patient's haemogram, fasting blood sugar and lipid profiles were all within normal limits. No fundus fluorescein angiogram, echocardiogram or carotid Doppler ultrasound could be done due to unavailability and limited interest by the patient.

## DISCUSSION

Pterygium excision, by all measures is a minor ocular surface procedure and can safely be done under topical anaesthesia or with a combined topical and intralesional injection of local anaesthetic. This however, requires a cooperative patient to achieve a good ocular akinesia, as the extra ocular muscles are not blocked. To prevent globe movement and avoid inadvertent surgical mistakes a number of surgeons prefer to give either retrobulbar or peribulbar anaesthetic block to the eye.

Peribulbar anaesthesia is known to be safer but it still has the tendency to cause damage to the optic nerve through the remote effects of the anaesthetic agent, amount injected, and speeds of injection and use of post-injection mechanical compression. Concurrent use of adrenaline in anaesthetic agents is also known to cause vasoconstrictive effects that may lead to CRAO.<sup>1,2</sup> In our patient, the CRAO might have been coincidental. However, its temporal occurrence with peribulbar injection suggests a relationship.

Reporting on two cases of CRAO during phacoemulsification procedure under peribulbar anaesthesia with and without adrenaline, Vinerovsky and co-workers suggested that while the event was likely to be caused by the vasospastic effects of Adrenaline, it was also entirely possible to be caused by potential vasospasms in response to the anaesthetic injection rather than the effects of the adrenaline.<sup>1</sup> Such vasospastic effects of anaesthetic agents used in local and regional blocks have been established in a number of other studies.<sup>2,3</sup> In a 1999 paper, Findl et al reported a decrease in retinal blood flow velocity by 10 to 15%, one and five minutes respectively following peribulbar anaesthesia without a vasoconstrictive agents like adrenaline.<sup>1</sup> The group also established that such effect lasted between one to three days following peribulbar injection for cataract surgery.<sup>2</sup>

Occlusion of the central retinal artery may also be caused by increased IOP secondary to globe compression by the anaesthetic agent and a subsequent weight placement on the globe. It is, however, known that extreme and prolonged increase in IOP (over the systolic arteriolar pressure) is needed to produce such retinal artery occlusion. Such scenario is hardly achieved in pterygium surgeries as the procedure hardly goes beyond 30 minutes even among cases requiring conjunctival auto grafting. In the Findl report, no correlation was found between high IOP and a decrease in retinal blood flow following peribulbar injection for cataract surgery.<sup>6</sup> In this current report, the IOP remained within normal limits after completion of surgery as measured the following day. In addition, the patient being reported on did not complain of post-operative pain which normally would normally accompany acute rise in the IOP.

Similar cases of retinal infarction with macular Cherry Red spot have been reported following intraocular injection of gentamycin and other amino glycosides aimed at preventing post-operative endophthalmitis. Many of such cases have had to do with either intravitreal injection or direct injection near areas of sclera thinning or laceration. This scenario is unlikely as Gentamycin was not used.<sup>8,9</sup>

The incidence of CRAO following peribulbar anaesthesia suggests that damage to the optic nerve may occur even when the injection is away from the nerve. Immediate post-operative evaluation of retinal blood flow following peribulbar injection may help early detection and prompt treatment of CRAO. This is however difficult in practice due to the high number of cases of peribulbar anaesthesia/surgery undertaken in most centres and the rarity of such damage.

We suggest that whenever possible minor surgeries like pterygium excision should be done under topical anaesthesia and where necessary, with adjunctive intralesional infiltration. This is especially so in elderly patients or in patients with high risk factors for arteriosclerotic cardiovascular disease.

## REFERENCES

1. Klein ML, Jampol LM, Condon PI, et al. Central retinal artery occlusion without retrobulbar haemorrhage after retrobulbar anaesthesia. *Am J Ophthalmol* 1982; 93:573–577.
2. Sullivan KL, Brown GC, Forman AR, et al. Retrobulbar anaesthesia and retinal vascular obstruction. *Ophthalmology* 1983; 90:373–377.
3. Vinerovsky A, Rath EZ, Rehany U, Rumelt S. Central retinal artery occlusion after peribulbar anaesthesia. *J Cataract Refract Surg* 2004;30: 913-5.
4. Fruhstorfer H, Wagener G. Effects of intradermal lignocaine and mepivacaine on human cutaneous circulation in areas with histamine induced neurogenic inflammation. *Br J Anaesth* 1993; 70:167-72.
5. Wienzek H, Freise H, Giesler I, Van Aken HK, Sielenkaemper AW. Altered blood flow in terminal vessels after local application of ropivacaine and prilocaine. *Reg Anesth Pain Med* 2007;32:233-9.
6. Findl O, Dallinger S, Menapace R, et al. Effects of peribulbar anaesthesia on ocular blood flow in patient undergoing cataract surgery. *Am J Ophthalmol* 1999; 127:645–649
7. Rainer G, Kiss B, Dallinger S, et al. Effect of small incision cataract surgery on ocular blood flow in cataract patients. *J Cataract Refract Surg* 1999; 25:964–968
8. Thomas T.G.D, Brod, R.D. Gentamycin and other antibiotic toxicity. *Ophthalm Clin North Am* 2001. 14(4): 611-24.
9. Hancock, H. A., Guidry, C., Read, R. W., Ready, E. L. & Kraft, T. W. Acute Amino glycoside Retinal Toxicity In Vivo and In Vitro. *Investigative Ophthalmology and Visual Science*. 2005; 46:4804-4808