

RETROCAVAL URETER: TWO CASE REPORTS

M. Y. KYEI¹, E. D. YEBOAH², G. O. KLUFIO², J. E. MENSAH², S. GEPI-ATEE², L. ZAKPAA³,
B. MORTON¹, and B. ADUSEI¹

¹Department of Surgery, Korle Bu Teaching Hospital, PO Box 77, Accra, Ghana ²Department of Surgery,
Urology Unit, University of Ghana Medical School, PO Box 4236, Accra, Ghana

³Police Hospital, Accra, Ghana

Corresponding author: Dr Matthew Kyei

E-mail: matkyei@yahoo.com

Conflict of interest: None declared

SUMMARY

Retrocaval ureter also referred to as pre-ureteral vena cava is a rare congenital anomaly with the ureter passing posterior to the inferior vena cava. Though it is a congenital anomaly, patients do not normally present with symptoms until the 3rd and 4th decades of life from a resulting hydronephrosis. We present the first two cases to be reported in Ghana; a 36-year-old male and a 40-year-old female both with right flank pains and associated right hydronephrosis. Diagnoses were confirmed with retrograde ureteropyelogram and both had an open surgical repair of the anomaly.

Keywords: Retrocaval ureter, flank pain, hydronephrosis, retrograde ureteropyelogram, pyeloureteric anastomosis

INTRODUCTION

Retrocaval ureter also referred to as circumcaval ureter or preureteral vena cava is a rare congenital anomaly with the ureters passing posterior to the inferior vena cava. The ureter classically course medially behind the inferior vena cava winding around it and then passes laterally in front of it to then course distally to the bladder. Though it is a congenital anomaly, patients do not normally present with symptoms until the 3rd and 4th decades of life, from a resulting hydronephrosis. The hydronephrosis may be due to kinking of the ureter, a ureteric segment that is adynamic or compression against the psoas muscle. It was initially considered as aberration in ureteric development; however current studies in embryology have led to it being considered as an aberration in the development of the inferior vena cava.^{1,2,3} Hence it is being suggested that the anomaly be referred to as a pre-ureteral vena cava.^{4,5} It is of interest, as these happen to be the first symptomatic cases to be reported in Ghana.

Case histories

The first is a 36 year old male diagnosed with hypertension four years prior to presentation and being managed with anti-hypertensives (felodipine and atenolol)

who presented with a three month history of right flank pain that was of sudden onset and initially colicky but had become constant. There was no haematuria. The blood pressure at presentation was 140/80mmhg. There were no significant findings on physical examination.

Full blood count, urinalysis and blood urea and creatinine were normal. Abdominal ultrasonography revealed a right hydronephrosis. An intravenous pyelography showed delayed function of the right kidney and subsequently a right hydronephrosis and hydroureter of the proximal ureter with non-visualization of the rest of the right ureter. (Figure 1)

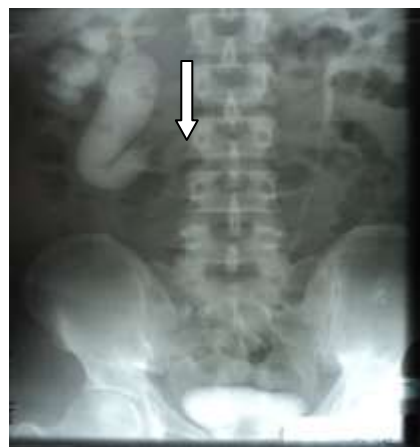

Figure 1 Intravenous pyelogram with non-visualization of right ureters (arrow)

A retrograde ureteropyelogram showed an “S” shaped or “fish hook” right uretero-pelvic region with an associated hydronephrosis and medially deviated middle and distal right ureter. (Figure 2)

A CT Scan of the abdomen revealed a high grade obstruction of the ureter with associated hydronephrosis. It excluded any extrinsic lesion as a possible cause of the above findings. A diagnosis of a symptomatic right retrocaval ureter was made.

The patient had an open surgery through a midline abdominal incision. The intraoperative findings confirmed the diagnosis of right retrocaval ureter and associated hydronephrosis. The procedure carried out involved dividing the ureter at the medial and lateral borders of the inferior vena cava. The redundant distal right renal pelvis was excised and the ureter coursing behind the inferior vena cava was removed. A pyeloureteric anastomosis using vicryl 4-0 suture was carried out anterior to the inferior vena cava without tension with placement of a double-J ureteric stent. (Figures 3 and 4)

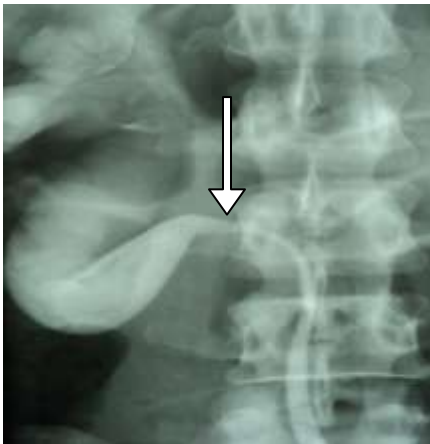


Figure 2 Right retrograde ureteropyelogram showing an "S" shaped right uretero-pelvic region (arrowed)

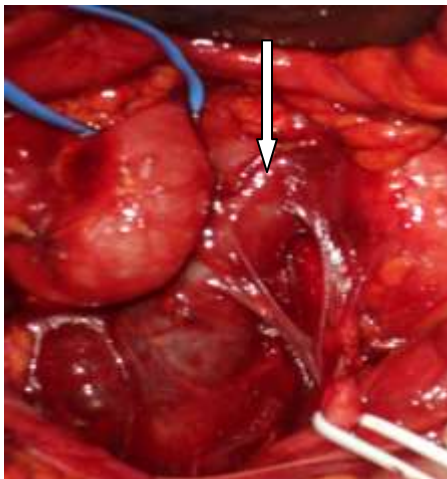

Figure 3 Tapes around the right ureter with the ureter coursing behind the inferior vena cava (arrowed)

The patient made an uneventful recovery and was discharged on post operative day 5. The double-J ureteric stent was removed on postoperative day 32. Postoperative IVU done revealed correction of the anomaly with good drainage.

The patient has since not experienced the right flank pain though he is still on antihypertensive medication to maintain a normal blood pressure.

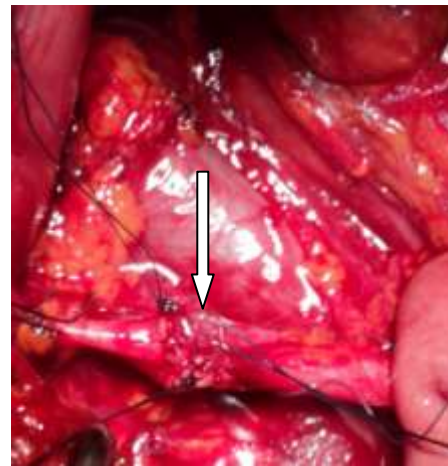


Figure 4: Right pyeloureteric anastomosis (arrowed) with the ureters positioned in front of the inferior vena cava

The second case was a 40-year-old female who also presented with right flank pain with associated right hydronephrosis. A right retrocaval ureter was confirmed by retrograde ureteropyelogram. She also had an open surgical exploration and uretero-ureterostomy correcting the anomaly. A concurrent abdominal incisional hernia from a previous myomectomy was also repaired. She had a resolution of the right flank pains and hydronephrosis but has since been lost to follow up.

DISCUSSION

Retrocaval ureter is a rare congenital anomaly occurring with incidence of about 1 in 1500 people with a three to four times male predominance in autopsy studies.⁶ Though similar male to female ratios are seen in clinical practice, few clinical cases have been reported world wide.⁷

The first observed case of retrocaval ureters was described by Hochstetter in 1893.⁸ Though initially thought of as an anomaly of ureteric development studies in embryology has revealed an anomaly related to the development of the inferior vena cava.^{4,5,9} The appropriate term giving the correct description of the anomaly is preureteral vena cava.

The anomaly predominantly involves the right ureter, as was observed in these reported cases. If it involves the left ureter then it is usually associated with either partial or complete situs inversus or duplication of the inferior vena cava (IVC).^{10,11}

The ureter typically deviates medially behind the inferior vena cava, winding about and crossing in front of it from a medial to a lateral direction, to resume a normal course, distally, to the bladder. The renal pelvis and upper ureter typically appear elongated and dilated in a "J" or fishhook shape before passing behind the vena cava.

Although it is a congenital anomaly it normally presents in the third and fourth decade of life as typified by the ages of the presented cases. Majority of patients presenting with symptoms, present with flank or abdominal pain that can be intermittent, dull and aching and is commonly due to ureteric obstruction and associated hydronephrosis. Some patients may present with recurrent urinary tract infection and haematuria. Renal calculi and pyonephrosis may complicate the condition. Some cases are found incidentally during radiographic imaging for other conditions.

Retrocaval ureters are classified into two clinical types. Type 1 is commonest and has moderate to severe hydronephrosis in about 50% of cases with extreme medial deviation of middle ureteric segment and the ureter assuming an S or 'fish hook' deformity. Type 2 has less medial deviation of the ureter with mild or no associated hydronephrosis and forms about 10% of cases.^{12,13} Surgical management is reserved for the type 1 cases that are usually symptomatic. Retrocaval ureter has hence been defined as a rare congenital anomaly that requires surgical correction in the symptomatic patient.^{14,15}

Abdominal ultrasound demonstrates hydronephrosis. IVU usually does not demonstrate the middle and distal ureter requiring a retrograde ureteropyelogram to demonstrate the ureter and hence confirm the diagnosis. Spiral CT scan may define the ureter and inferior vena cava anomalies obviating the need for a retrograde ureteropyelogram and is considered an investigation of choice.¹⁶ MRI can nicely demonstrate the course of a pre-ureteral vena cava and may be a more detailed and less invasive imaging modality, without exposure to radiation, when compared with CT and retrograde ureteropyelography.¹⁷

Treatment is surgical and involves division of the ureter and repositioning it anterior to the inferior vena cava. This may be achieved through an anastomosis between the renal pelvis and the ureter or a uretero-ureteric anastomosis over a double-J stent. The segment behind the inferior vena cava which may be aperistaltic is either excised or left in situ. In these reported cases, the segments were excised. Surgical intervention is for symptomatic cases. Patients with minimal caliceal dilatation and no significant symp-

toms do not need surgery but need to be followed up. Transperitoneal and retroperitoneal laparoscopic repair of the retrocaval ureter has been described offering advantages of a shorter hospital stay and early recovery.^{18,19} Important differential diagnosis includes retroperitoneal fibrosis and retro peritoneal masses displacing the ureters from its normal course. Abdomino pelvic CT Scan is helpful in excluding these conditions.

CONCLUSION

Retrocaval ureter is a congenital anomaly that presents clinically late in the third and fourth decades of life. Very few clinically symptomatic cases have been reported worldwide with these two cases being the first to be reported in Ghana. Treatment is surgical allowing for correction of the anomaly with resolution of symptoms. There is the need to research into the autopsy incidence among Ghanaians.

REFERENCES

1. Chuang VP, Mena CE, and Hoskins PA. Congenital anomalies of the inferior vena cava. Review of embryogenesis and presentation of a simplified classification. *Br J Radiol.* 1974; 47: 206–213.
2. Schlüssel RN, Retik AB. Preureteral Vena Cava. In: Kavoussi LR, Novick AC, Partin AW, Peters CA editors. *Campbell-Walsh Urology*. 9th ed. Elsevier Saunders; 2007. p 3418-3420.
3. Lesma A, Bocciardi A, Rigatti P. Circumcaval Ureter: Embryology. *European Urology* 2006; (supplements 5):444 – 448
4. Dreyfuss W. Anomaly simulating a retrocaval ureter. *J Urol.* 1959; 82:630.
5. Lerman I, Lerman S, Lerman F. Retrocaval ureter: Report of a case. *J Med Soc N J.* 1956; 53:74.
6. Heslin JE, Mamonas C. Retrocaval ureter: Report of four cases and review of literature. *J Urol* 1951;65:212-22.
7. Xiaodong Z, Shukun H, Jichuan Z, Xiaofeng W, Guangdong M, Xingke Q. Diagnosis and treatment of retrocaval ureter. *Eur Urol* 1990;18:207–10.
8. Olson RO, Austen G, Jr. *N Engl J Med* 1950; 242:963-968
9. Peisojovich, MR, Lutz SJ. Retrocaval ureter-a case report and a successful repair with a new surgical technique. *Mich Med* 1969 Nov;68(21):1137-41.
10. Watanabe M, Kawamura S, Nakada T, et al. Left preureteral vena cava (retrocaval or circumcaval ureter) associated with partial situs inversus. *J. Urol* 1991;145: 1047-8.
11. Rubinstein I, Calvacanti AG, Canalini AF, Freitas MA, Accioly PM. Left retrocaval ureter associated

- with inferior vena cava duplication. *J. Urol* 1999; 162:1373-4.
12. Kenawi MM, Williams DI. Circumcaval ureter: a report of 4 cases in children with a review of the literature and a new classification. *Br J Urol* 1976; 48: 183-192.
 13. Bateson E, Atkinson D. Circumcaval ureter: a new classification. *Clin Radiol* 1969;20:173-7.
 14. Shown TE, Moore CA. Retrocaval ureter: 4 cases. *J Urol* 1971;105:497-501.
 15. Salonia A, Maccagnano C, Lesma A, Naspro R, Suardi N, Guazzoni G, et al. Diagnosis and Treatment of the Circumcaval Ureter. *European Urology* 2006 ;Supplements 5:449-462.
 16. Bass FE, Redwine MD, Kramer LA, Huynh PT, Harris JH. Spectrum of congenital anomalies of the inferior vena cava: cross-sectional imaging findings. *RadioGraphics* 2000;20:639-52.
 17. Uthappa MC, Anthony D, Allen C. Case report: Retrocaval ureter: MR appearances. *Br J Radiol* 2002; 75:177-179.
 18. Bhandarkar DS, Lalmalani JG, Shivde S. Laparoscopic ureterolysis and reconstruction of a retrocaval ureter. *Surg Endosc* 2003; 17:1851-1852.
 19. Tobias-Machado M, Lasmar MT, Wroclawski ER. Retroperitoneoscopic surgery with extracorporeal uretero-ureteral anastomosis for treating retrocaval ureter. *Int Braz J Urol* 2005; 31:147-150.
-