

SPECIAL ARTICLE

THE ZOONOTIC IMPLICATIONS OF PENTASTOMIASIS IN THE ROYAL PYTHON (*PYTHON REGIUS*)A.B. AYINMODE¹, A.O. ADEDOKUN¹, A. AINA² and V. TAIWO³¹Department of Veterinary Microbiology and Parasitology, University of Ibadan, Ibadan, Nigeria²Department of Zoology, University of Ibadan, Ibadan, Nigeria ³Department of Veterinary Pathology, University of Ibadan, Ibadan, Nigeria*Corresponding Author: Dr A. B. Ayinmode**E-mail: ayins2000@yahoo.com**Conflict of interest: None declared*

SUMMARY

Pentastomes are worm-like endoparasites of the phylum *Pentastomida* found principally in the respiratory tract of reptiles, birds, and mammals. They cause a zoonotic disease known as pentastomiasis in humans and other mammals. The autopsy of a Nigerian royal python (*Python regius*) revealed two yellowish-white parasites in the lungs, tissue necrosis and inflammatory lesions. The parasite was confirmed to be *Armillifer spp* (Pentastomid); this is the first recorded case of pentastomiasis in the royal python (*Python regius*) in Nigeria. This report may be an alert of the possibility of on-going zoonotic transmission of pentastomiasis from snake to man, especially in the sub-urban/rural areas of Nigeria and other West African countries where people consume snake meat.

Keywords: Zoonosis, Pentastome, *Armillifer*, Python, Lungs.

INTRODUCTION

Pentastomes, endoparasites of reptiles, birds, and mammals^{1, 2} are worm-like, possess morphologic characteristics of annelids and arthropods, and form their own phylum, the *Pentastomida*.³ Adult pentastomes are worm-like and are found principally in the respiratory tract of reptiles. In snakes, the parasites are found in the lung or air sac distal to the lung.³ Pentastomiasis is a zoonotic disease of humans and other mammals.^{4, 5}

Mammalian hosts like rodents get infested by the ingestion of the egg contained either in faeces or in the sputum of the snake; eggs hatch to larva in the mammalian intermediate host and then burrow to the abdominal cavity through the gut wall. The arthropod-like larvae mature to nymphs and get attached to the viscera in an encysted form. Snakes become infected on consumption of the intermediate host containing the encysted nymphs.

The nymphs excyst in the intestine and migrate by various routes to the respiratory tract.⁶ The infestation can be diagnosed by the identification of the characteristic thick-shelled eggs containing an embryo with rudimentary legs. Human pentastomiasis was first reported by Pruner in 1847 and Wyman subsequently identified the parasite in the nasopharynx of the African python in 1848.^{5, 7}

Armillifer brumpti (a Pentastomid) was described from an unknown host in Madagascar⁸ and subsequently from *Boa madagascariensis* and *Corallus madagascariensis*.⁹ Since then, several *Armillifer* species have been reported in reptiles and mammals of Asia and Africa.^{5, 10, 11, 12, 13} This study presents the first evidence of *Armillifer spp.* infestation in the royal python (*Python regius*) in Nigeria.

Case Report

A royal python (*Python regius*) was brought to the Zoological Garden, University of Ibadan, Nigeria. Upon arrival, the snake was isolated at the quarantine section and received reared domestic chicken (*Gallus gallus domesticus*) as the sole diet. On the second day of arrival, the python was observed to vomit after eating; it later became anorexic, lethargic and restless with signs of dyspnoea.

The animal became progressively weak and died on the third day before any veterinary intervention. A necropsy was performed the same day it died. Faecal samples and worm-like structures found in the lung were sent to the parasitology laboratory for identification.

Pathology

The body condition of the carcass was fair with slightly pale oral and conjunctival mucous membranes. Two yellowish-white live arthropod larvae (each with about

3cm thick and 15cm long with annulated body and tortuous anterior portion) (Figure 1) were found; one at the anterior portion of the trachea (about 15cm from the oral cavity) associated with muco-haemorrhagic exudates extending about 8cm in length, while the other was found at the terminal portion of the proximal air-bag associated with a severe and expansive mucohaemorrhagic area on the surface of the lungs.

The liver, kidneys, heart, spleen were observed to be apparently normal grossly. Histopathology of the lungs reveals severe widespread pulmonary congestion, oedema, and haemorrhage and the presence of large numbers of alveolar macrophages laden with haemosiderin (Figure 2). Other lesions include multifocal coagulative hepatic necrosis associated with calcified segments of arthropod parasites (Figure 3), moderately severe glomerular degeneration, vacuolar degeneration of renal tubules and presence of pinkish casts in tubular lumen.



Figure 1 Adult *Armillifer* spp. isolated from the trachea and lung of the royal python (*Python regius*) (x1-magnification).

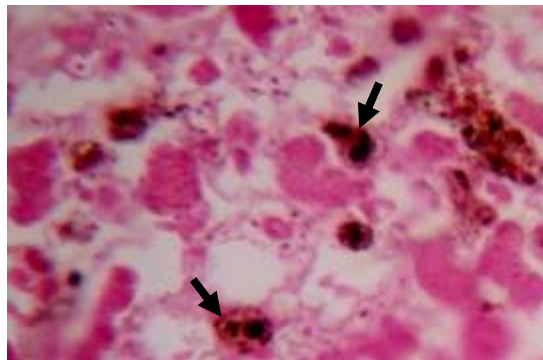


Figure 2 The lung of the royal python (*Python regius*) showing severe widespread pulmonary congestion, haemorrhage and oedema, with alveolar macrophages (arrows) laden with haemosiderin (H&E; x500).

Parasitological findings

The two parasites with well-defined concentric annular rings (“strings of beads appearance” over the entire length of the body (50-70mm) in length (Figure1) were identified to be Pentastomid of the genus *Armillifer*.³ Faecal examination showed numerous (1200 egg per gram of faeces) pentastomid eggs (Fig. 4a), which were thick-shelled, oval, approximately 140x130 μ and contained embryo with rudimentary arthropod-like legs (Fig. 4b).

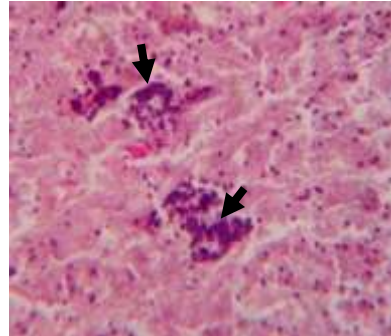


Figure 3 The liver of the royal python (*Python regius*) showing focal areas of coagulative necrosis associated with calcified segments of arthropod parasites (arrows) (H&E; x500)

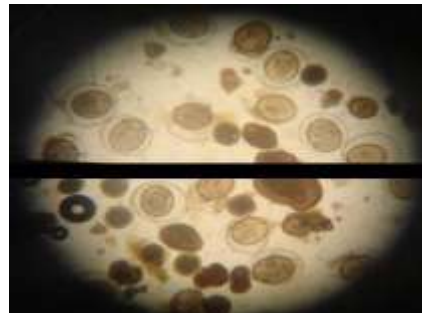


Figure 4 A. Numerous Pentastomid eggs in faeces of royal python (X 10 - magnification)

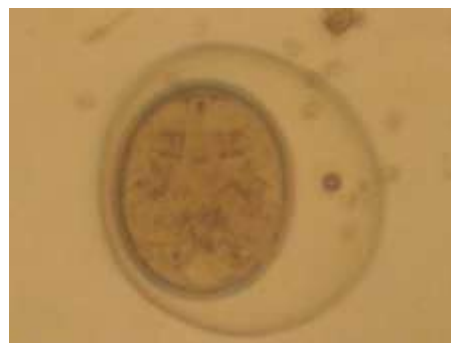

Figure 4 B An egg of *Armillifer* spp. isolated from the faecal sample of the royal python (*Python regius*) (x 40 Magnification)

DISCUSSION

The two isolated parasites were identified as pentastomids belonging to the genus *Armillifer* in line with their "strings of beads" characteristic feature.³ The ova found in the faeces recovered from the cadaver of the python that has the previously described characteristic thick shell with flexible outer membrane suggest the parasite belongs to genus *Armillifer*.^{7,14}

Personal communication with taxonomy experts confirms that the parasite belongs to the genus *Armillifer armillatus*. The pentastomids were found attached to the tracheal mucosa and parietal surface of the lungs at necropsy. Although little is known about the effect of the pentastomids in the lungs of snakes, it has been suggested that the adults can cause trachea occlusion¹⁵; destruction and impairment of the lung function by tissue perforation producing haemorrhage.¹² The adult parasites were found tenaciously attached to the lung tissue; this observation is consistent with other findings that showed *Armillifer spp.* in African snakes are difficult to remove from the lung tissue where they cause considerable hypersecretion of mucus, blockage and perforation of the lungs.¹²

The multifocal hepatic necrosis and calcification of arthropod segments in the liver suggests that the parasite may have larval migrans stage. The extent of pulmonary haemorrhage and oedema, accompanying heart failure cells (alveolar macrophages laden with hemosiderin pigment), and degenerative lesions in the kidneys may also be as a result of the larval migrans. The cause of death of the python is unknown, although chronic irritation of the lung tissue by parasites could lead to secondary bacterial infection and subsequent septicaemia.

It is also possible that the stress induced by the sudden captivity could suppress the immune system for opportunistic infection, which might be sub-clinical if the python was still in the wild. Although it is unlikely that the pentastomid ova shed by the quarantined snake could be consumed by a rodent intermediate host in the zoo premises, however, measures to conduct surveillance for the presence of the larva in intermediate hosts and check up for the zoo keepers for possible infestation as a result of handling have been recommended.

Pentastomiasis can be transmitted to humans through direct contamination from handling or consuming the flesh of infected snakes and also through the ingestion of infective eggs acquired via soil, vegetation or water contaminated with faeces or secretion from the respiratory tracts of snakes and other hosts¹⁶. Human

pentastomiasis reported in China were often associated with the ingestion of poorly cooked snakes.¹⁷

Few reports of human cases in Ghana was associated to the socio-cultural practices of clans that have pythons as their totem and allow them in their homes thus giving room for probable transmission of the parasite to humans.¹⁸ The significance of the isolation of pentastomes in the Nigerian snake population cannot be overemphasized, as prior reports had described human cases of pentastomiasis in Nigeria^{19, 20} and in Nigerians that immigrated to Canada²¹ and South Africa.²²

Hence, this may be an alert of the possibility of on-going zoonotic transmission of pentastomiasis from snake to man, especially in the sub-urban/rural areas where people consume snake meat. In addition to transmission of pentastomiasis to human from snakes, it has also been documented that the consumption of Marrara (a popular Sudanese dish consisting of raw liver, lungs, trachea and rumen of goats and sheep) infested with *Linguatula serrata* (a pentastome) resulted in hypersensitivity reaction of the upper respiratory tract and buccopharyngeal mucosa in humans (Marrara syndrome).^{23, 24}

Sheep and goat are thought to have acquired the parasite from eggs of the adult worms that are found in the nasal passages of dogs.²³ In conclusion, our report on the presence of pentastomids (*Armillifer* species), for the first time in the Nigerian royal python along with previous reports from the tropics and sub-tropical area (such as west and central Africa and southeast Asia^{25, 26} suggests that proper surveillance be conducted to ascertain the epidemiology of the parasite and the associated zoonotic disease in these regions.

It is also imperative that veterinarians and parasitologists should conduct further study on all possible mode of transmission of pentastomes to humans given that the parasite has the ability to utilize a wide range of domestic and wild animals as both intermediate and definitive host.

REFERENCES

1. Hazen TC, Aho J M, Murphy T M, Esch G W, Schmidt G D. The parasite fauna of the American alligator (*Alligator mississippiensis*) in South Carolina. *J Wildl Dis* 1978; 14: 435 - 439.
2. Hendrix CM. Pentastomiasis: a possible emerging zoonosis. *Comp Cont Ed Pract Vet* 1988; 10: 46 - 51.
3. Self TJ. Biological relationships of the Pentastomida; A bibliography on the Pentastomida. *Exp Parasitol* 1969; 24: 63 -119.

4. Drabick JJ. Pentastomiasis. *Rev Infect Dis* 1987; 9: 1087-1094.
5. De Meneghi D. Pentastomes (Pentastomida, *Armillifer armillatus* Wyman, 1848) in snakes from Zambia. *Parassitologia* 1999; 41(4): 573–574.
6. Page LA. Diseases and infections of snakes *Bull Wild Dis Assoc* 1966; 2:111-126
7. Meyers WM, Neafie RC, Connor DH. Pentastomiasis. In: Binford CH and Connor DH (ed). *Pathology of Tropical and extraordinary diseases*. Washington DC: Armed Forces Institute of Pathology. 1986. Pp 284-308.
8. Giglioli G. *Armillifer brumpti* N. Sp., Nouvelle espece de Linguatulide de Madagascar. *Bull de la Soc de Path Exot* 1922; 15: 565 - 572.
9. Heymons Ruh, Vitzthum G. Bietrage Zur Systematik der Pentastomiden. *Zietschr Parasitenkunde* 1936; 8: 1-104
10. Sambon LW. A synopsis of the family Linguatulidae. *J Trop Med Hyg* 1922; 24; 391-428.
11. Hill HR. The occurrence of linguatulids in Pythons. *Bull So Calif Acad Science* 1934; 33: 117- 122.
12. Fantham HB, Porter A. The endoparasites of certain South African snakes together with some remarks on their structure and effects on their host. *Proc Zool Soc Lond* 1950; 120: 599 - 647
13. Junker K, Boomker J. Check-list of the pentastomid parasites crocodilians and freshwater chelonians. *Onderstepoort J Vet Res* 2006; 73(1): 27- 36.
14. Fain A. Les Pentastomides de l'Afrique Centrale. *Ann hlus Roy Afr Centr* 1961; 92 : 1 - 115.
15. Telford SR. Parasitic diseases of reptiles. *J Am Vet Med Ass* 1971; 159: 1644 - 1652.
16. Ma KC, Qiu M H, Rong Y. L. Pathological differentiation of suspected cases of pentastomiasis in China. *Trop Med Int Health* 2002; 7: 166–177
17. Min HY, Fang W, Lan FT. Human pentastomiasis in China: Case report and Literature Review. *J Parasitol* 2008; 94 (6): 1295-1298.
18. Dakubo J C B, Naaeder S B, and Kumodji R. Totemism and the transmission of human pentastomiasis. *Ghana Med J* 2008; 42 (4): 165-168
19. Azinge NO, Ogidi-Gbegbaje EG, Osunde J A, Oduah D. *Armillifer armillatus* in Bendel State (Midwest) Nigeria (a village study in Ayogwu village, near Auchi, 120 kilometres from Benin City) phase I. *J Trop Med Hyg* 1978; 81(5):76 - 79.
20. Nzeh Da AJ, Nzeh, GC. Incidence of *Armillifer armillatus* (Pentastome) calcification in the abdomen *Central Afr J Med* 1996; 42: 29 - 31.
21. Guardia S N, Sepp H, Scholten H, Morava-Protzner T. Pentastomiasis in Canada. *Arch Pathol Lab Med* 1991; 15(5): 515 - 517.
22. Du Plessis V, Birnie Aj, Eloff I, Reuter H, Andronikou S. Pentastomiasis (*Armillifer armillatus* infestation). *South Afr med J* 2007; 97(10): 928 – 930.
23. El-Hassan AM, Eltoum IA, El-Asha BM. The Marrara syndrome: isolation of *Linguatula serrata* nymphs from a patient and the viscera of goats. *Trans R Soc Trop Med Hyg* 1991; 85(2): 309
24. Yagi H, El Bahari S, Mohamed H A, Ahmed E S, Mustafa B, Mahmoud M, Saad M B.A., Sulaiman S M, El Hassan A M. The Marrara syndrome: a hypersensitivity reaction of the upper respiratory tract and buccopharyngeal mucosa to nymphs of *Linguatula serrata*. *Acta Tropica* 1996; 62: 127-134
25. Ranque P, Amy D, Discamps G, Mattei X, Quilici M. Pentastomiasis by *Armillifer armillatus*. *Zeitschrift fu`r Parasitenkunde* 1974; 44: 329–338
26. Faisy C, Boye B, Blatt A, Boutes P, Iloumbou J. Porocephalosis, A little known parasitosis: literature review and a Congolese case report. *La Medicina Tropical* 1995; 55: 258–262.