

## ADVERSE EFFECTS OF MOSQUITO COIL SMOKE ON LUNG, LIVER AND CERTAIN DRUG METABOLISING ENZYMES IN MALE WISTAR ALBINO RATS

\*L.K.N. OKINE, A.K. NYARKO<sup>1</sup>, G.E. ARMAH<sup>1</sup>, B. AWUMBILA<sup>2</sup>, K. OWUSU, S. SETSOAFIA AND M. OFOSUHENE<sup>1</sup>

Department of Biochemistry and <sup>2</sup>Animal Science University of Ghana, P.O. Box LG54, Legon, Accra and <sup>1</sup>Noguchi Memorial Institute for Medical Research, Legon, Ghana.

### SUMMARY

The adverse effects of chronic 8-hour daily inhalation of mosquito coil smoke for 6 weeks were investigated in male Wistar albino rats. Specific serum and urine biochemical parameters and tissue morphology were used as indices of toxicity. Activities of specific isozymes of microsomal monooxygenase (MFOs) were used to assess the potential effects of inhalation of mosquito coil smoke on drug metabolism. The animals that inhaled mosquito coil smoke had significantly elevated (23%) serum bilirubin ( $p=0.015$ ) but lower (16%) albumin levels ( $p=0.009$ ). Serum creatinine and urinalysis data were comparable to control levels. Gross pathology and histopathological studies revealed severe lung damaged evidenced by increased lung wet weight (26%), interstitial oedema, bronchopneumonia and emphysema in the coil smoke-exposed rats. Inhalation of mosquito coil smoke did not affect kidney cells but fatty infiltration and proliferation of liver cells were observed. Mosquito coil smoke inhalation significantly inhibited hepatic pentoxoresorufin O-deethylase (PROD) activity by 27%, lung PROD and p-nitrophenyl hydroxylase (PNPH) activities by 43% and 48%, respectively, and kidney ethoxyresorufin-O-deethylase (EROD) activity by 37% ( $p=0.002$ ). These are consistent with the observed 33% increase in pentobarbital-induced sleeping time in the mosquito coil smoke exposed group. These findings indicate that inhalation of mosquito coil smoke induced selective pulmonary and hepatic damage accompanied by inhibition of drug metabolising enzymes in the rats. It is possible that chronic inhalation of mosquito coil smoke could have significant health implications for humans.

**Keywords:** Toxicity, mosquito coil, smoke, male rats, enzymes.

### INTRODUCTION

Mosquito coil is used extensively in tropical and subtropical areas as an insect repellent or insecticide. It contains allethrin, the active substance, which is a synthetic analogue of the natural pyrethrum insecticides obtained from the flower heads of the plant *Chrysanthemum cinerariaefolium* known to act by immobilizing the insect through poisoning of its nervous system<sup>1</sup>. Most mosquito coils sold in Ghana contain 0.1-0.3% allethrin (Okine LKN et al. unpublished survey).

Studies in female albino rats exposed to mosquito coil smoke indicated that, there were signs of toxicity to liver and lung but none to the kidney<sup>2</sup>. It has been suggested that the toxicity of mosquito coil smoke is caused by its combustion products such as sub-micron particles coated with heavy metals, allethrin and a wide range of organic vapour like phenol, o-cresol, benzene and toluene<sup>2,3</sup>. Chronic exposure of high doses of allethrin (50-200 mg/kg/day for two years) produced signs of toxicity such as increased liver and kidney weights and adverse morphological changes in liver tissue in female rats but not in dogs<sup>4,5</sup>. There was however, no observation of carcinogenic or teratogenic and/or developmental effects in exposed rats<sup>4,5</sup>.

Chemical-induced organ toxicity may manifest as tissue or organ damage and/or derangement of cellular metabolism culminating in cell death and subsequently, organ failure<sup>6,7</sup>. Certain chemicals may exert their adverse effects through modulation of tissue microsomal mixed function oxidases (MFO) that metabolise endogenous substances like steroid hormones and xenobiotics leading to drug

\* Author for correspondence

interactions and possible toxicological consequences<sup>1,8,9</sup>.

In this paper, we report on the toxic effects of mosquito coil smoke inhalation on male rats and on some isozymes of the MFO in these animals. This is in view of the fact that, most studies on the toxicity of mosquito coil smoke inhalation have been conducted in female rats, and there is no readily available empirical data on the effects of mosquito coil smoke inhalation on MFO, which are responsible for the metabolism of important endogenous substances and xenobiotics.

## MATERIALS AND METHODS

### Chemicals and Reagents

Mosquito coils containing 0.3% allethrin were obtained from MIA Co. Ltd., Indonesia. Ames Reagent Strips for Urinalysis were purchased from Bayer-Sankyo Co. Ltd., Japan. NADPH, pentoxyresorufic, ethoxyresorufin, p-nitrophenol and resorufin were obtained from Sigma Chemicals Co., St. Louis, MO, USA. Bilirubin, albumin and creatinine reagent kits were purchased from Randox Laboratories Ltd., Co. Antrim, UK. Folin-Ciocalteu reagent was obtained from Hopkins-Williams, Essex, England. All other chemicals were obtained from Fluka Chemicals, Buchs, Switzerland or BDH Chemicals Ltd., Poole, UK.

### Animals and Treatment

Adult male Wistar albino rats weighing about 250g obtained from the Animal Facility, Korle Bu Teaching Hospital, Korle Bu, Accra Ghana. The animals were housed in stainless steel cages and fed with pelleted food from GHAFCO Ltd. (Tema, Ghana) and distilled water *ad libitum*. The rats were divided into groups of five animals. Three groups of animals served as controls while three others were assigned as test groups. The test animals were exposed to mosquito coil smoke produced by burning two mosquito coils for 8hr/night, 7days/week for 6 weeks, in a partially ventilated room of size 4m x 3.5m x 3.5m. The control animals were kept in a room of similar ventilation and size without mosquito coil smoke for the period of time. One set of control and test animal groups were used for tissue morphological studies. Another set of control and test animal groups were used for plasma biochemical analyses, urinalysis and selected tissue MFO activity studies. A third set of control and test animal groups were used for pentobarbital sleeping time determination. The body weights of control and test animals were determined at baseline and at various time intervals during the course of the study.

### Blood and Urine Sampling

Blood samples were collected from all animals prior to commencement of the studies and also at termination (6 weeks). The blood samples, collected into eppendorf tubes, were placed on ice and allowed to clot and centrifuged at 4,500g for 5 minutes to obtain serum. The serum was separated and stored at -20°C for biochemical analyses.

### Serum Biochemical Analyses and Urinalysis

Serum bilirubin, albumin and creatinine were determined spectrophotometrically (Shimadzu UV-190, Japan) with commercially available kits (Randox Laboratories Ltd., Co. Antrim, UK). Urinalysis was performed on spot urine samples. The test strip was wetted with sample of urine and the colour changes compared with those of a standardised scale to give a semi-quantitative measure of protein, pH, glucose and blood in the urine.

### Pentobarbital-induced Sleeping Time and Tissue Microsomal Enzyme Assays

Each animal from the third set of control and smoke-inhaled animal groups underwent the pentobarbital-induced sleeping time test<sup>10</sup>. For microsomal studies, each animal from the second set of control and smoke-inhaled animal groups was weighed at termination and euthanized by cervical dislocation. The kidneys, lung and liver of each animal were excised, blotted and weighed. The different organs from each animal were separately minced and homogenised and microsomes prepared by standard methods<sup>11,12</sup>. The microsomal pellets were each suspended in 2 ml of storage buffer made up of Na<sub>2</sub>HPO<sub>4</sub>/NaH<sub>2</sub>PO<sub>4</sub> buffer pH 7.6, containing KCl (0.15M), EDTA (1mM) and glycerol (10%), and stored at -40°C for protein and enzyme assays. Protein determination was done on day of tissue enzyme assay by the Lowry method<sup>13</sup>, using bovine serum albumin as standard following which the protein content of each microsomal preparation was adjusted to 1.0 mg/ml and the activities of p-nitrophenol hydroxylase (PNPH), ethoxyresorufin-O-deethylase (EROD) and pentoxyresorufin-O-deethylase (PROD) were determined<sup>10</sup>.

### Histology

One animal each from the first set of control and mosquito coil smoke-inhaled animals was euthanized by cervical dislocation at baseline and two animals each from each treatment group thereafter at 3 and 6 weeks. Lungs, liver and kidneys were excised and fixed in formaldehyde and dehydrated with alcohol. The tissues were cleared with xylene and impregnated with paraffin wax and sections

cut and stained with haematoxylin and eosin, and mounted on slides for light microscopic examination<sup>14</sup>.

### Statistical Analysis

One-way analysis of variance was conducted to determine statistical significance. The 0.05 level of probability was used as the criterion of significance in all instances. All statistical tests were performed with Jandel SigmaStat. Statistical Software Version 2.0 (1992-95).

## RESULTS

There were no significant differences in the mean body weights between smoke-inhaled and control animals over the initial 2 week period of study. However, by week 5 there was a significant decrease ( $p < 0.042$ ) in the mean body weight of the smoke-inhaled animals compared to controls (results not shown).

The effects on inhalation of the mosquito coil smoke on some organ weights at termination are shown in Table 1. When compared to controls, lung wet-weight of smoked-inhaled animals increased (26%) significantly ( $p = 0.038$ ). Kidney weights of the smoke-inhaled animals decreased by 8% ( $p = 0.062$ ) but there was no change in liver weight.

**Table 1** Effects of mosquito coil smoke inhalation on organ weights at termination<sup>a</sup>

Organ	Organ wet weight			
	Actual		% Body weight	
	Control	Test	Control	Test
Lung	1.60 ± 0.07	2.01 ± 0.15 (125.6)*	0.57 ± 0.02	0.72 ± 0.05 (126.3)*
Liver	7.80 ± 0.30	0.09 ± 0.29 (103.7)	2.83 ± 0.11	2.91 ± 0.09 (102.8)
Kidney	1.32 ± 0.04	1.22 ± 0.03 (92.4)	0.48 ± 0.02	0.44 ± 0.01 (91.6)

<sup>a</sup>For details of animal treatment see "materials and methods".

Values are means ± SEM of n=5.

Value in parenthesis represents percent of control

\*Value significantly different from control;  $p = 0.038$

Table 2 shows the effects of mosquito coil smoke inhalation on some serum biochemical parameters at termination. Compared to controls, serum albumin decreased (16%) significantly ( $p = 0.009$ ) in the smoke-inhaled animals. Conversely, serum albumin in these animals showed a significant increase (23%) ( $p = 0.015$ ). There was however no differences in urine pH, glucose and protein levels or presence of blood between the two groups (data not shown).

**Table 2** Effects of mosquito coil smoke inhalation on serum biochemical parameters at termination<sup>a</sup>

Serum parameter	Control	Test
Albumin (g/l)	50.7 ± 0.46	42.2 ± 2.46 (84)*
Bilirubin (µmol/l)	9.05 ± 0.41	11.1 ± 0.52 (123)**
Creatinine (µmol/l)	172 ± 3.60	179 ± 2.80 (104)

<sup>a</sup>For details of animal treatment see Material and Methods section.

Values are means ± SEM of n=5

Value in parenthesis represents percent of control.

\*Value significantly different from control;  $p = 0.009$

\*\*Value significantly different from control;  $p = 0.015$ .

The effects of mosquito coil smoke inhalation on monoxygenases activities in lung, liver and kidneys at termination are shown in Table 3. Liver and lung PROD activities were significantly lower in animals exposed to mosquito coil smoke (27% and 43%, respectively) compared to control levels ( $p < 0.001$ ). Kidney EROD activity in smoke-inhaled animals decrease by 37% ( $p = 0.002$ ). Similarly, only coil smoke exposed lungs showed a significant reduction (48%) in PNPH activity ( $p < 0.001$ ). Pentobarbital-induced sleeping time was increased (33%) significantly ( $p < 0.034$ ) in the smoke-inhaled animals (255 ± 18 min) compared to controls (192 ± 17 min).

The morphological changes in control lungs, livers

and kidneys and those from animals exposed to mosquito coil smoke are represented in Figures 1-3. The results indicated that there was Clara cell hyperplasia and thickening of the bronchiolar epithelial wall as well as inflammatory response in alveolar areas with alveolar septa thickening and hypercellularity in the smoke-inhaled animals at weeks 3 and 6 post-exposure. However, lung morphology of control animals at weeks 3 and 6 (results not shown) were similar to those of baseline controls, which showed normal alveolar areas and Clara cells lining a normal bronchiolar epithelial wall (Figure 1a, b & c).

**Table 3** Effects of mosquito coil smoke inhalation on tissue microsomal mono-oxygenases activity at termination<sup>a</sup>

Enzymes Parameter	Enzyme specific activity (nmol/min/mg protein)					
	Control	Liver Test	Control	Lung Test	Control	Kidney Test
PROD	0.79 ± 0.03	0.58±0.02(73%)*	0.65±0.04	0.37±0.03(57%)*	0.37±0.02	0.42±0.01(114%)
EROD	0.30 ± 0.01	0.27±0.02(90%)	0.31±0.07	0.34±-.07(110%)	0.56±0.04	0.35±0.02(63%)*
PNPH	0.70 ± 0.08	0.59±0.10(84%)	0.33±0.02	0.17±0.02(52%) <sup>§</sup>	0.96±0.10	0.71±0.10(74%)

<sup>a</sup>For details of animal treatments see "materials and method"

PNPH=p-Nitrophenol hydroxylase; PROD = Pentoresorufin-O-deethylase; EROD=Ethoxyresorufin-O-deethylase.


Values are means ± SEM of n=5

Value in parenthesis represents percent of control.

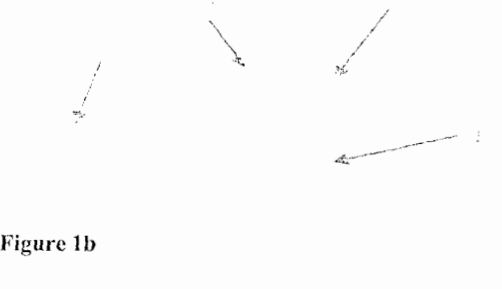
\*Value significantly different from liver or lung control; p<0.001

\*Value significantly different from kidney control; p=0.002

<sup>§</sup>Value significantly different from lung control; p<0.001.



**Figure 1a**




**Figure 1b**



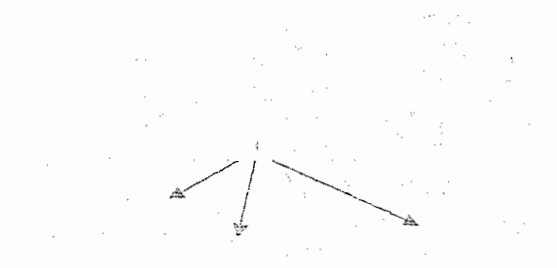
**Figure 1c**

**Figure 1** Histological appearance of lung tissue of control animals showing normal alveolar areas (1) and Clara cells (2) lining normal bronchiolar epithelial wall (3), and animals exposed to mosquito coil smoke for three and six weeks showing inflammatory response, septa thickening and hypercellularity and consolidation in alveolar areas (1), Clara cell hyperplasia (2), thickening

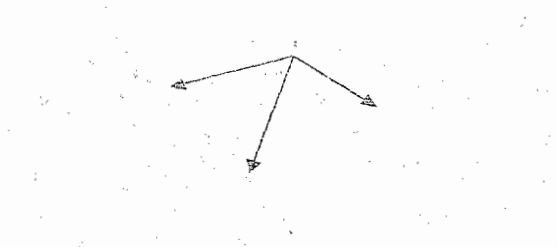
of bronchiolar epithelial wall (3) and interstitial oedema (4). Magnification x 132.



**Figure 2a**



**Figure 2b**



**Figure 2c**

**Figure 2** Histological appearance of liver tissue of control animals showing normal hepatocytes, and animals exposed to mosquito coil smoke for three and six weeks

showing gross morphological changes characterised by cell proliferation and fatty infiltration of cells (1). Magnification x66.

Smoke exposed animals at weeks 3 and 6 showed gross morphological changes of liver characterised by proliferation and fatty infiltration of cells when compared to baseline controls (Figure 2a, b, & c).

There were no observable differences in kidney morphology of control and smoke-inhaled animals by week 6 (Figure 3a & b).



Figure 3a



Figure 3b

**Figure 3** Histological appearance of kidney tissue of control animals (a) and animals exposed to mosquito coil smoke for six weeks (b) showing no differences in appearance of cells between the two treatment groups. Magnification x132.

Liver and kidney morphology of control animals at week 3 and 6 (results not shown) were similar to baseline controls.

## DISCUSSION

Previous studies using female Wistar albino rats exposed to mosquito coil smoke showed that the smoke caused morphological changes in lung; and changes in some lung and plasma biochemical parameters but none in the kidney<sup>2,3</sup>. In the present study we investigated the effects of mosquito coil smoke on serum bilirubin, albumin and creatinine levels in male Wistar albino rats, and determined the effects of the smoke on tissue microsomal mono-oxygenase activities, which are likely to

affect the metabolism of other xenobiotics and hence cause drug interactions.

Some biochemical indices used in this study to assess hepatotoxicity are elevated levels of serum bilirubin and reduced levels of serum albumin and/or globulins. These and others like elevated activities of enzymes like aspartate aminotransferase (AST), alkaline phosphatase (ALP) and alanine aminotransferase (ALT) are used as indices of hepatic damage or dysfunction<sup>6</sup>. Albumin, which is involved in the transport of substances like drugs and lipids<sup>6</sup> is synthesised by the liver. Therefore, the significantly lower level observed in the mosquito coil smoke inhaled rats would suggest that exposure to the coil smoke decreased the protein biosynthetic activity of the liver. This could affect capacity of serum protein-mediated transport of various substances, and may explain the fatty infiltration of some hepatocytes. The reasons for the elevated bilirubin levels cannot be explained at this time since RBC counts and direct and indirect bilirubin levels were not determined. However, it is known that some possible causes of increased serum bilirubin levels are the impairment of the biliary excretory system or an increased red blood cell haemolysis<sup>6</sup>.

Morphological studies of the lung, liver and kidney in the male rat indicate that while the smoke did not affect the kidneys it caused damage to the lungs and liver as observed previously in female rats by others<sup>2</sup>. However, unlike the previous studies where signs of lung toxicity were observed at 60 days, lung and liver toxicity in the present study manifested as early as 21 days. This may be due to sex differences or to differences in experimental conditions such as the number of coils burn/day, the number of days the animals were exposed to the mosquito coil smoke/week, the size of room and the degree of room ventilation used in each study. A comparative study between male and female rats under identical experimental conditions are currently under investigations and may help to confirm sex differences in the expression of organ toxicity induced by mosquito coil smoke.

The lung tissue of smoke-inhaled rats in the study, showed Clara cell hyperplasia, thickening of the bronchiolar epithelial wall, alveolar septal thickening and hypercellularity, and consolidation in alveolar areas after 3 and 6 weeks of exposure (Figure 1a,b, & c), which are indicative of toxic lung insult. These were accompanied by signs of pulmonary oedema, fibrosis, emphysema and bronchopneumonia, as well as increase in mean lung

wet weight (Table 1) and attenuation of some mono-oxygenase activities like PROD and PNPB (Table 3). These findings are consistent with observations made when mice were exposed to pneumotoxicants like naphthalene, butylated hydroxytoluene and 1,1-dichloroethylene (DCE), which caused time-dependent damage to Clara and alveolar cells of the lung with concomitant reductions in some mono-oxygenase activities and increase in lung wet weight<sup>15-17</sup>.

In animals and man, the liver is the organ mainly responsible for general cellular metabolism including the biosynthesis of proteins. Hepatocellular damage indicated by gross morphological changes such as proliferation and fat infiltration of liver cells of the smoke exposed animals could affect the normal function of liver such as the metabolism of xenobiotics, which are mainly catalysed by isozymes of cytochrome P450. Toxic agents are known to cause degranulation of the endoplasmic reticulum (ER) with consequent reduction in enzyme protein synthesis and thus general cellular metabolism<sup>18</sup>. This may therefore explain the inhibition/reduction of liver microsomal mono-oxygenase activities (Table 3) as well as the reduction in the growth of the smoke-inhaled rats by termination. Induction or inhibition of microsomal mono-oxygenase activities by chemicals can affect the metabolism of other chemicals leading to either beneficial or deleterious drug interactions. For example the pre-treatment of animals with allylisopropylacetamide, an inhibitor of cytochrome P450, resulted in significant increases in both hexobarbital-induced sleeping and zoxazolamine-induced paralysis time<sup>8</sup>. Furthermore the pre-treatment of animals with phenobarbital, an inducer of CYP2E1 and CYP1B1/2B1, increased the metabolism of Paracetamol to toxic metabolites<sup>9</sup>. Pentobarbital is a hypnotic drug, whose metabolism is catalysed by the same cytochrome P450 isozymes that catalyse the metabolism of Phenobarbital<sup>8</sup>. Thus the inhibition of hepatic PNPB and PROD activities, enzymes catalysed by CYP2E1 and CYP1B1/2B1, respectively in smoke-inhaled rats (Table 3), may explain the observed increase in pentobarbital sleeping time in these animals when compared to controls. This suggests that chronic inhalation of mosquito coil smoke may affect the metabolism and excretion of ingested compounds or xenobiotics.

One of the main functions of the kidney is the excretion of waste productions of cellular metabolism, like urea and creatinine. When the kidneys become dysfunctional as a result of cellular dam-

age, glomerular filtration and tubular secretion of waste products are impaired and their levels in the blood become elevated above normal<sup>6</sup>. Substances like proteins and glucose which normally do not pass out into urine begin to appear in it. The kidneys also lose their ability to regulate blood pH<sup>6</sup>. In this study, there was no morphological evidence of renal damage in the smoke inhalation group. This is corroborated by the normal serum creatinine and urinalysis. These findings are similar to those observed in female Wistar albino rats<sup>2</sup>. However, there was a significant reduction in renal microsomal CYP1A1/2A1-dependent EROD activity, which may suggest inhibition of specific protein biosynthesis or inhibition of enzymes catalytic activity. It has been suggested that binding of certain substances to cytochrome P450 isozymes inhibits their catalytic activity<sup>15,19,20</sup>.

In conclusion, the inhalation of mosquito coil smoke by male Wistar albino rats caused selective damage to the lung and liver as observed previously in female rats by others. The observed toxicity was accompanied by inhibition of specific isozymes of the mixed function oxidase system, which are responsible for the metabolism of endogenous substances and xenobiotics. It is possible that chronic inhalation of mosquito coil smoke in humans may also be harmful and this must be investigated.

#### ACKNOWLEDGEMENTS

The authors are thankful to Messrs AK Ayim and SY Amelor of the Noguchi Memorial Institute for Medical Research, for their excellent technical assistance.

#### REFERENCES

1. Craig RC and Stitzel RE. Modern Pharmacology, sixth edition. Little brown and Company, USA 1994 ; 33-39, 73-82.
2. Liu WK, Wong MH and Mui YL. Toxic effects of mosquito coil (a mosquito repellent) smoke on rats II: Morphological changes of the respiratory system. *Toxicol Lett* 1987; 39(2-3): 231-239
3. Liu WK and Sun SE. Ultra structural changes in tracheal epithelium and alveolar macrophages of rats exposed to mosquito coil smoke. *Toxicol Lett* 1988; 41(2): 45-157.
4. World Health Organization. Alletrins: Allethrin, D-allethrin, Bioallethrin, S-biollethrin-

- Environmental Health Criteria 87. International Programme on Chemical Safety, Geneva, Switzerland 1989; 2-20.
5. US Environmental Protection Agency. Pesticide Fact Sheet Number 158: Allethrin Stereoisomers. Office of Pesticides and Toxic Substances, Washington, DC 1988, 2-8.
  6. Gaw A, Cowan RA, O'Reilly DStJ, Stewart MJ and Shepherd J. Clinical Biochemistry: An illustrated colour text, Churchill Livingstone, Edinburgh, UK 1998; 12-55: 120-123.
  7. Hodgson E and Levi PA. Introduction to Biochemical Toxicology, second ed. Appleton and Lange, Norwalk, USA 1994.
  8. Gibson GG and Skett P. Introduction to drug metabolism, second edition, Chapman and Hall Publishers, UK 1994; 1-24, 37-68, 78-104, 166-172, 220.
  9. Hoyumpa Am and Schenker S. Major Drug Interaction: Effect of liver disease, alcohol and malnutrition. *Ann Rev Med* 1983; 33: 113.
  10. Nyarko AK, Ankrah N, Ofosuhene M and Sittie AA. Acute and sub-chronic evaluation of *Indigofera arrecta*: Absence of both toxicity and modulation of selected cytochrome P 450 isozymes in ddY mice. *Phytother Res* 1999; 13: 666-668.
  11. Lake BG. Preparation and characterization of microsomal fractions for studies in xenobiotic metabolism. In *Biochemical Toxicology, A Practical Approach*. Snell K and Mullock B (ed), IRL Press, Oxford 1987; 182-215.
  12. Anjum F, Raman A, Shakori AR and Gorrod JW. An assessment of cadmium toxicity on cytochrome P450 and flavin mono-oxygenase-mediated metabolic pathway of dimethylaniline in male rabbits. *J Environ Pathol Toxicol Oncol* 1992; 11: 191-195.
  13. Lowry OH, Rosenbrough NN, Farr AL and Randall RJ. Protein measurement with the Folin reagent. *J Biol Chem* 1951; 193:265-275.
  14. Baker FJ and Silverton RE. Introduction to Medical Laboratory Technology, Sixth edition, Bitterworth and Co. Ltd., London 1985; 172-221.
  15. Okine LK, Goochee JM and Gram TE. Studies on the distribution and covalent binding in vivo. *Biochem Pharmacol* 1985; 34(22): 4051-4057.
  16. Krijgsheld KR, Lowe MC, Mimnaugh ED, Trush MA, Ginsburg E and Gram TE. Lung-selective impairment of cytochrome P450-dependent mono-oxygenases and cellular injury by 1,1-dichloroethylene in mice. *Biochem Biophys Res Comm* 1983; 110(2): 675-681.
  17. Tong SS, Hirokata YT, Trush MA, Mimnaugh EG, Ginsburg E, Lowe MC and Gram TE. Clara cell damage and inhibition of pulmonary mixed-function oxidase activity by naphthalene. *Biochem Biophys Res Comm* 1981; 100: 944-950.
  18. Massey ED and Butler WH. Zonal changes in the rat liver following and acute dose of phenobarbitone: An ultra-structural, morphometric and biochemical correlation. *Chem Biol Interac* 1981; 34: 31-38.
  19. Timbrell JA. Principles of Biochemical Toxicology, Taylor and Francis, London 1991; 172-188.
  20. Correia MA. Drug Biotransformation. In *Chemical Pharmacology*, Kantsung BG (ed), Appleton and Lange, Norwalk, USA 1995; 46-59.