

ANAPLASTIC EPENDYMOMA OF THE FOURTH VENTRICLE CAUSING OBSTRUCTIVE HYDROCEPHALUS

M.I. IDRISU, *T.K. DAKURAH AND G.K. WEPEBA

Department of Surgery, College of Health Sciences, University of Ghana Medical School,
Accra, Ghana.

SUMMARY

Ependymomas are relatively uncommon and present with a spectrum of biological and clinical characteristics that make specific recommendations regarding their treatment difficult and assignment of prognostic factors controversial. The case of fourth ventricular anaplastic ependymoma in a four-year-old child is reported in which the initial presentation was deterioration of the level of consciousness secondary to acute obstructive hydrocephalus. An initial insertion of a ventriculo-peritoneal shunt (V-P) to deal with the acute intracranial hypertension was done. Subsequently, sub-occipital craniectomy and sub-total resection of the tumour were performed successfully. Post-operative radiotherapy was also undertaken on the patient. The pertinent literature is reviewed. At one year follow up our patient had clinically improved with no signs of recurrence. The most important prognostic factors are tumour grade and the presence of residual tumour on post operative imaging studies. A median survival of 31 months is noted in children with infratentorial ependymomas and one year survival is quoted as 81%.

Keywords: Ependymoma, fourth ventricle, obstructive hydrocephalus, ventriculo-peritoneal shunting, radiotherapy, CT Scan.

INTRODUCTION

Ependymomas are glial neoplasms arising from the ependymal cells of the cerebral ventricles, central canal of the spinal cord, and the cortical rests. These lesions are relatively uncommon and present with a spectrum of biological and clinical characteristics that makes specific recommendations regarding their treatment difficult, and the assignment of prognostic factors controversial. Ependymomas of the fourth ventricle are mostly responsible for varying degree of ventricular enlargement.

Ideally, tumour removal should cure the hydrocephalus. It does indeed happen in some of the cases. It may also be necessary, under very specific conditions (to gain time) to control the intracranial hypertension prior to tumour surgery^{1,2}.

We report the case of a four year old child with 4th ventricular anaplastic ependymoma associated with obstructive hydrocephalus.

CASE REPORT

A four-year old child was first examined in the Pediatric Department of the Korle Bu Teaching Hospital (KBTH) with a two-week history of neck pain and unsteady gait. The family had noticed a head tilt to the left and occasional vomiting. The child was later transferred to the Neurosurgical Unit following sudden deterioration in the level of consciousness.

Examination

On examination, the patient was found to be drowsy but could follow verbal commands. The neurological examination revealed papilloedema, truncal ataxia, broad based gait and sixth cranial nerve palsy involving the left eye. There was also nuchal rigidity. The results of all laboratory investigations including white blood cell count, erythrocyte sedimentation rate and serum chemistry were within normal limits.

Imaging studies

Cerebral computerized tomography (CT scan) revealed a posterior fossa mass of 4.3 x 3.4 cm with moderate contrast enhancement. The CT scan also revealed gross tri-ventricular hydrocephalus (enlargement of lateral and third ventricles) as shown in figure 1.

* Author for correspondence

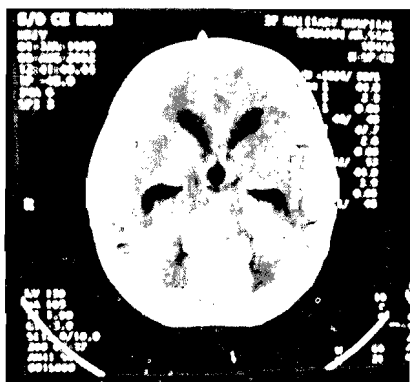


Figure 1 Pre-operative brain CT scan

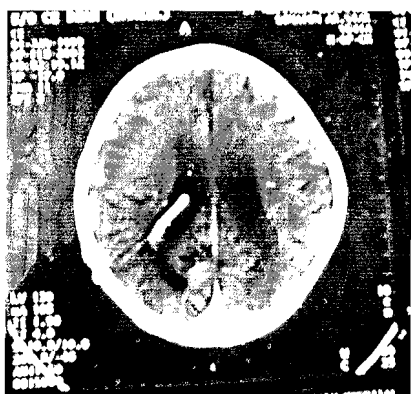


Figure 2 Post-V-P shunting

Figure 2 shows the ventricular catheter in the right lateral ventricle with narrowing of the ventricles as compared to the pre-operative image.

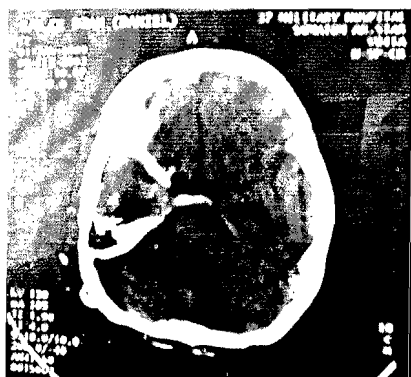


Figure 3 Post-excision via sub-occipital craniectomy

Figure 3 shows the posterior fossa after excision of the tumour where there is no visible remnant tumour.

Operation

The patient’s symptoms improved slightly after administration of systemic steroids. He subsequently underwent ventriculo-peritoneal shunting followed by sub-total resection (90%) of the tumour via sub-occipital craniectomy a week later. Prior CSF diversion before opening the posterior fossa reduces the risk of downward herniation. The removal was done piece-meal. Intra-operatively, a rubbery grayish tumour, solid in consistency, about 4cm by 3cm by 2.5cm was found involving and infiltrating the fourth ventricle and also attached to the brainstem. The histo-pathology revealed a cellular neoplasm with perivascular pseudorosettes, moderate mitosis, cellular pleomorphism and neovascularization.

Post-operative course

The post-operative course was uneventful. Ataxia, vomiting and nuchal rigidity improved drastically but the improvement of the sixth cranial nerve palsy was rather slow. Diet and physiotherapy were stepped up to prepare him for adjuvant radiotherapy.

Radiotherapy

The patient was treated with conventional external beam irradiation, four weeks post-resection, and no chemotherapy was given. Between 1st March 1999 and 31st May 1999, 60Gy of radiation was administered in fractions of 20Gy per month to whole brain followed by focal irradiation of 15Gy to the posterior fossa, which was also fractionated.

At 13 months post-surgical resection (12 months post-irradiation therapy) the patient made an excellent functional recovery with clearing of her sixth cranial nerve palsy. Her mentation became normal and her gait was only mildly ataxic.

DICUSSION

Ependymomas represent 10-12% of pediatric central nervous system tumors¹. Seventy-five percent (75%) are benign, with 25% anaplastic. About fifty percent (50%) occur before five years of age. Two-thirds of ependymomas are located infratentorially^{2,3,4,5,6}. The optimal management of fourth ventricular ependymomas remains controversial⁷. At present the standard therapy is initial attempt at total resection followed by irradiation. With surgery alone, a 17-27% of long-term survival^{8,10,11,12} can be expected. If following total resection, radia-

tion is added, survival statistics improve to 40-87%^{13,14,15}. Complete resection of fourth ventricle ependymomas may not be possible at initial surgery. In the series presented by Healey et al⁸, in approximately half the patients who underwent postoperative imaging, residual tumour was present. High rates of complete macroscopic resection at initial surgery have been reported but with high morbidity rates⁹. These tumours, which are often large at diagnosis, may often occupy the entire fourth ventricle, and also invade its floor^{3,15}. The patients are often unfit for major surgery at presentation due to raised intracranial pressure caused by blockage of the cerebrospinal fluid pathways. It is therefore not surprising that complete resection cannot safely be achieved at initial operation in a substantial number of patients^{7,12,18,16}. In our patient, an attempt at total macroscopic resection was abandoned because the tumour was adherent to the floor of the fourth ventricle as well as extending to the brain stem where they usually draw their blood supply. In one surgical series 53% of the patients with fourth ventricle ependymomas experienced worsening of neurologic deficits after surgery¹⁴. This may be partly caused by the surgical removal of tumour attached to the floor of the fourth ventricle³. Clinical variables, like adult age group, hemispheric location, benign pathology and total surgical resections seem to favour long-term survival. Survival rates for children with posterior fossa ependymomas have been reported in recent series to be 20%¹⁶, 44.6%⁷, 56%²⁰ and 52%¹⁷ at 5 years. Young adults with fourth ventricle ependymomas may have a better prognosis¹⁸ than children, although in some series, this difference has not been statistically significant^{19,20,21}.

CONCLUSION

The combination of surgical removal with prior insertion of ventriculo-peritoneal shunt and post-surgical radiation therapy represents a valuable alternative to the treatment of patients with fourth ventricle anaplastic ependymomas. This allows patients improved quality of life and longer life expectancy. Insertion of ventriculo-peritoneal shunt should be considered as the first-line treatment in fourth ventricular ependymomas associated with acute hydrocephalus, especially in our environment where, in most cases, immediate surgical intervention and the appropriate technology are not readily available.

ACKNOWLEDGEMENT

We are very grateful to the Neurosurgical house staff for retrieving the data from the clinical notes.

To the nursing staff for taking care of the patient. We are also thankful to our anaesthetic team for their support. Finally, we wish to thank Faustina and Nii-Noi Adumuah for their secretarial support.

REFERENCES

1. Kun LE, Kovnar EH, Sanford RA. Ependymomas in children. *Pediatr Neurosurg* 1998; 14 : 57-63.
2. Barone BM, Elvidge AR. Ependymomas : A clinical study. *J Neurosurg* 1970 ; 33 : 428-438.
3. Cohen ME, Duffner PK. (Eds) Brain tumours in children : Principles of diagnosis and treatment. New York, Raven Press 1994 ; 2 : 219-239.
4. Coulon RA, Tilly K. Intracranial ependymomas in children : A review of 43 cases. *Child's Brain* 1977; 3: 154-168.
5. Healey EA, Barnes PD, Kupsky WJ, Scott RM, Sallan SE, Blank PMCL, Trabel NJ : The prognostic significance of postoperative residual tumour in ependymomas. *Neurosurg* 1991; 28 : 666-672.
6. Pierce-Kahn A, Hirsch JF, Roux FX, Renier D, Sainte-Rose C. Intracranial ependymomas in children : Survival and functional results of 47 cases. *Child's Brain* 1983 ; 10 : 145-156.
7. Nazar GB, Hoffman HJ, Becker LE, Jenkin D, Humphrey RP, Hendrick EB. Infratentorial ependymomas in childhood : Prognostic factors and treatment. *J Neurosurg* 1990 ; 72 : 408-417.
8. Gilles FH, Leviton A, Hedley-White ET et al. Childhood brain tumour update. *J Neuropathol* 1987 ; 14 : 834-845.
9. Cochrane DD, Gustavsson B, Paskitt KP, Steinbok P, Kestle JR. The surgical and natural morbidity of aggressive resection for posterior fossa tumours in childhood. *Pediatr Neurosurg* 1994 ; 20 : 19-29.
10. Cushing H. Intracranial ependymomas : Notes upon a series of two thousand verified cases with surgical mortality percentage pertaining thereto. 1932 ; 56.

11. Fokes EC Jr, Earle KM. Ependymomas : Clinical and pathological aspects. *J Neurosurg* 1969; 30: 585-594.
 12. Ringertz N, Reymond A. Ependymomas and choroids plexus papillomas. *J Neuropathol Exp Neurol* 1949; 8: 355-380.
 13. Bloom HJG. Intracranial tumours : Response and resistance to therapeutic endeavours. 1970 -1980. *Int J Radiat Oncol Biol Phys* 1982 ; 8 : 1083-1113.
 14. Dorhman GJ, Farwell JR, Flannery JT. Ependymomas and ependymoblastomas in children. *J Neurosurg* 1976 ; 45 : 273.
 15. Leible SA, Sheline GE. Radiation therapy of neoplasm of the brain. *J Neurosurg* 1987 ; 66 : 1-22.
 16. Tomita T. Miscellaneous posterios fossa tumours. *J Neurosurg* 1995; 3 : 383-391
 17. Perilongo G, Massimino M, Scotti G, Gianaspero F, Sainti L, Madon E. Are there 'bad' and 'good' Ependymomas in children? *Med Pediatr Oncol* 1994; 23: 214.
 18. Ferrante L, Mastronardi L, Schettine G, Lunandi P, Fortuna A. Fourth ventricle ependymomas. A study of 20 cases with survival analysis. *Acta Neurochir (Wein)* 1994 ; 131 : 67-74.
 19. Shaw EG, Evans RG, Scheithawer BW, IL Strup DM, Earle JB. Postoperative radiotherapy of intracranial ependymomas in pediatric and adult patients. *Int J Radiat Oncol Biol Phys* 1987 ; 13 : 1457-1462.
 20. Vanustel LJ, Bassel EM, Ashley SE, Bloom HJ, Brada M. Intracranial ependymoma : Long-term results of a policy of surgery and radiotherapy. *Int J Radiat Oncol Bio Phys* 1992 ; 23 : 313-319.
 21. Julian R, Youmans. WB Saunders , Philadelphia. 4th Edition *Neurolog Surg* 1996 ; 2 : 902-907.
-