

## SPECIAL ARTICLE

## A SIMPLE TISSUE MODEL FOR PRACTICING ULTRASOUND GUIDED VASCULAR CANNULATION

H. BADDOO, R. DJAGBLETEY and C. OWOO

Department of Anaesthesia, Korle-Bu Teaching Hospital, Korle-Bu, Accra

DOI: <http://dx.doi.org/10.4314/gmj.v48i1.8>*Corresponding Author: Dr Henry Baddoo**Email: hbaddoo@yahoo.com**Conflict of Interest: None declared***SUMMARY**

**Introduction:** The use of ultrasound in anaesthetic practice continues to be more established and the use of ultrasound guidance in establishing vascular access is recommended by various groups. We have developed a tissue model for the practice and skills development in ultrasound vascular access.

**Method:** The tissue model consist of a piece of “pork belly”, a longitudinal shaped balloon inserted between two muscle layers at a chosen depth of the tissue model (mimics a blood vessel), a bag of intravenous fluid (e.g. Ringer’s Lactate) together with a giving set and a short piece of extension tubing connected to a three-way tap used to expel air from the system. One end of the balloon is tied to the giving set with the intravenous fluid. The other end is tied to the short tubing with the three-way tap

**Results:** Ultrasound images of the fluid filled balloon mimic a blood vessel. It is possible under ultrasound guidance to puncture the balloon several times (>10times) and still be able to distend the balloon with fluid.

**Interpretation:** Ultrasound guided techniques require practice to improve hand-eye coordination. The “pork belly” tissue model allows multiple needle puncture without losing its functional integrity.

**Conclusion:** We believe the “pork belly” tissue model adds to the range of models that can be used to practice ultrasound guided vascular access. The components required for this model are readily available locally and affordable.

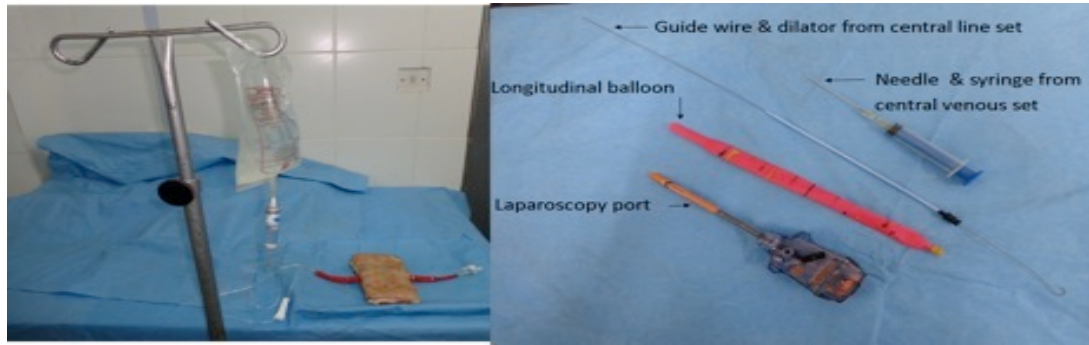
**Keywords:** Ultrasound-guided, vascular access, tissue model, pork belly, training, skills acquisition.

**INTRODUCTION**

The use of ultrasound in anaesthetic practice continues to become more established. The use of ultrasound guidance in establishing vascular access is recommended by various groups.<sup>1,2</sup> As with any practical procedure, there is a learning curve. Simulators and models provide conditions under which the skills in a technique can be developed prior to using the technique in patients. We have developed a tissue model that can be used to practice and develop the skill of ultrasound guided vascular cannulation.

**METHOD**

The basic component for the model is a piece of ‘pork belly’, which consists of skin, subcutaneous tissue, and three muscle layers. Other components are a bag of fluid (e.g. Ringer’s lactate) together with a giving set, a longitudinal shaped balloon, a short piece of extension tubing and a three-way tap. The components are shown in Figure 1. Gadgets needed to make up this model include a syringe, needle, guide wire and dilator from a central venous pressure line set, and a used laparoscopy port. The balloon is used to mimic a blood vessel. More than one balloon can be used and placed at different depths from the skin, in between two muscle layers

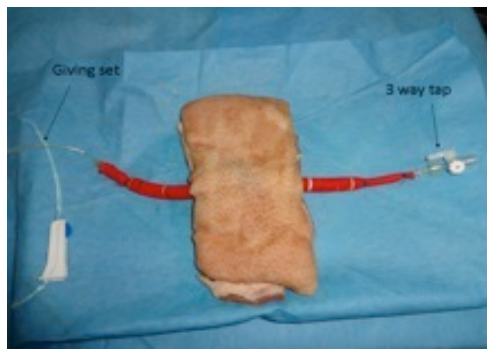

**Figure 1 Components of tissue model**

The depth of insertion is chosen and the CVP needle with syringe attached is passed in between two muscle layers, from one side of the specimen to the other. A Seldinger wire is then passed through the needle, the needle removed and the dilator passed over the Seldinger wire. A track between the muscle layers is thus formed. The guide wire and dilator are now removed and the laparoscopy port is passed through the track from one side of the specimen to the other.

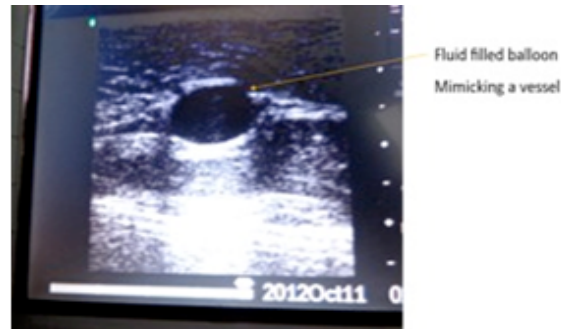
The balloon is passed through the laparoscopy port, and the port is then removed, leaving the balloon in the track formed. Using a piece of thread, the giving set (attached to the hanging bag of fluid), is attached to one end of the balloon. To the other end is attached to a short extension line attached to a three-way tap. The purpose of this three-way tap is to make it possi-

-ble to expel air from the system. The giving set is opened, allowing fluid to distend the balloon. Figure 2 shows the setup of the tissue model. Ultrasound gel is placed on the surface of the tissue model and a linear ultrasound probe (12MHz) is placed on the model to identify the “vessel”.



**Figure 2 Completed tissue model**

Figure 3 shows the ultrasound image of the tissue specimen with the fluid filled balloon mimicking a blood vessel.



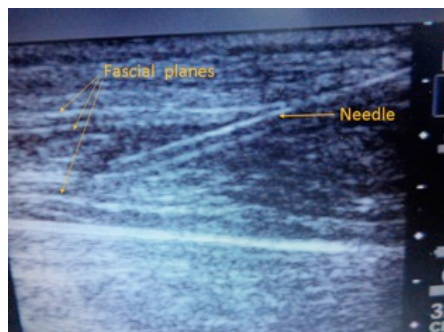**Figure 3 Ultra Sound scan of image of tissue specimen showing fluid-filled balloon**

The probe is adjusted to bring the “vessel” to the centre of the image and using an out-of-plane technique, the “vessel” is punctured using a CVP needle and fluid aspirated as would have been done for a normal CVP cannulation. Because the skin of the pig is quite thick, needle puncture was facilitated by making a small nick in the skin at the planned puncture site using a pointed scalpel blade.

**RESULTS**

Ultrasound images of the fluid-filled balloon in the model mimic a blood vessel (Figure 3). One was able, using a syringe and needle from a CVP set, to puncture the balloon (and aspirate fluid) under ultrasound guidance. Indeed one was able to puncture the same balloon several times (>10 times) and still be able to distend the balloon with fluid. Any fluid that leaked from the tissue drained into a tray into which the tissue model was placed.

Incidentally, the same piece of ‘pork belly’ can be used for practicing (under ultrasound guidance) injecting fluid between two muscle layers, as one would do when carrying out ultrasound guided Transverses Abdominis Plane (TAP) block as seen in Figure 4.



**Figure 4** Ultra sound image of tissue with needle in situ

## DISCUSSION

Establishing central venous access is a routine part of the anaesthetist's and intensivist's work. Several blind techniques, relying on anatomical landmarks have been described, for example, for cannulating the internal jugular vein. In experienced hands, the complication rate for central line placement is low, but complications still do occur.<sup>3,4</sup> Ultrasound guided vascular cannulation has been shown to reduce the complication rate.<sup>1</sup> With ultrasound guidance, practice is needed to improve hand-eye coordination. Commercial synthetic models are available to use for practicing ultrasound guided vascular access.

A homemade model has been described<sup>5</sup>, as well as a tissue model using a chicken.<sup>6</sup> The "pork belly" model described allows multiple needle puncture without losing its functional integrity. The probability is that the surrounding tissue provides a tamponade preventing excessive leakage of fluid from the puncture sites in the balloon.

## CONCLUSION

The "pork belly" tissue model described is a suitable alternative to commercial synthetic models for gaining expertise in ultrasound-guided techniques. The components required for this model are readily available locally and affordable. The model also lends itself to multiple puncture while maintaining its functional integrity. We believe the model we describe, made using 'pork belly, adds to the range of models that can be used in practicing ultrasound guided vascular access.

## REFERENCES

1. Wigmore TJ, Smythe JF, Hacking MB, Raobaikady R, MacCallum NS Effect of implementation of NICE guidelines for ultrasound guidance on the complication rates associated with central venous catheter placement in patients presenting for routine surgery in a tertiary referral centre. *Br. J. Anaesth* 2007; 99(5) : 662-665.
2. Troianos CA, Hartman GS, Glas KE, Skubas NJ et al. Guidelines for performing ultrasound guided vascular cannulation: Recommendations of the American Society of Echocardiography and the Society of Cardiovascular Anaesthesiologists. *Anesth Analg* 2012 ; 114 : 46-72.
3. Wilkie M, Hughes M Complications of central venous cannulation. *British Medical Journal* 1988; 297: 1126.
4. Kaye CJ, Smith DR Complications of central venous cannulation. *British Medical Journal* 1988; 297: 572
5. Kendall JL, Faragher JP Ultrasound-guided central venous access : a homemade phantom for simulation. *Canadian Journal of Emergency Medicine* 2007 ; 9(5) : 371-373.
6. Ault MJ, Rosen BT, Ault B The use of tissue models for Vascular Access Training. *J Gen Intern Med* 2006 ; 21(5) :514-517. ☺