

INFLUENCE OF CRUDE EXTRACT OF ROOT OF TELFAIRIA OCCIDENTALIS (FLUTED PUMPKIN) ON THE CYTOARCHITECTURE OF THE RAT KIDNEY AND BODY WEIGHT

T. B. EKANEM, A. O. EKEOMA, M. A. ELUWA AND A. O. AKPANTAH

(Received 7, August 2007; Revision Accepted 10, December 2009)

ABSTRACT

The effect of crude extract of root of *Telfairia occidentalis* (fluted pumpkin) was investigated on the kidney of adult wistar rats. The crude extract of pumpkin root were given both intraperitoneally and orally to rats respectively. The control group received distilled water throughout the duration of experiment. The administration lasted for seven days and on the eight day, the animals were sacrificed. Morphologically, there was decrease in the body weight, loss of appetite, weakness and death of some animals in the experimental groups. Histologically, the architecture of the kidneys in the experimental animals treated with pumpkin root extract orally and intraperitoneally showed enlarged tubules, distorted glomeruli and Bowman's capsule, shrinking of proximal and distal convoluted tubules compared with the control. These results suggest that the root of *Telfairia occidentalis* may be nephrotoxic in wistar rats.

KEYWORDS: crude extract, root, *Telfairia occidentalis*, kidney

INTRODUCTION

Telfairia occidentalis is a plant named after an Irish botanist- Charles Telfairia (1778-1885). It belongs to the family- Cucurbitaceae that consist mostly of herbs or rarely under shrubs with watery juice. It is popularly known as fluted pumpkin (English), ikong ubong (Efik), uguwu (Igbo) and egusi iroko (Yoruba) (Gbile, 1984). The leaves are common vegetables used for preparation of soup in Efik, Ibibio and Igboland. It contains proteins, vitamins and minerals such as calcium, phosphorus and iron (Sofowora, 1986). Oil from the seed is suitable for manufacturing soap, vegetable oil (Irvine, 1969), paints, varnishes and emulsions (Asiegbu, 1987; Odemena and Onyeneke, 1988).

Telfairia occidentalis is popular among the herbal practitioners and its leaves are said to be useful in maintenance of high degree of blood alkalinity, provision of roughage which stimulates peristalsis and proper elimination of waste matter from the colon thus assisting in preventing constipation with all its associated problems like colitis, appendicitis, haemorrhoid and fissure (Iwu, 1983). It is useful in the remedy of all cases of anaemia (Ajayi et al, 2000). The leaves have been documented to stimulate bone marrow to produce blood cells and maintain body resistance to infection (Kafaruk, 1998). Phytochemical study carried out on the root of *Telfairia occidentalis* showed that it contains alkaloids, saponins, flavinoid,

phlobatanin, tannins, anthraquinone, glycosides and terpene. Ekanem et al (2005) reported that the crude extract of the root of *Telfairia occidentalis* is hepatotoxic and should be used with great caution. The root of the fluted pumpkin could be used as an antibacterial agent. It contains poisonous compound, which makes it useful as rodenticide and ordeal poison (Odemena and Essien, 1988). Though the root however has been documented to be poisonous, there is hardly any information in literature regarding the effect of root *Telfairia occidentalis* on any organ system. This study was therefore undertaken to investigate the effect of crude extract of *Telfairia occidentalis* on the kidney using wistar rats as models. This study will create more awareness about the poisonous nature of the root of *Telfairia occidentalis* so that it should not be ignorantly used for treatment of various ailment by herbalist especially the untrained ones.

MATERIALS AND METHODS

Preparation of aqueous crude extract

Fresh roots of *Telfairia occidentalis* were obtained from a farm in Ibiono L.G.A. in Akwa Ibom State. The roots were washed free of soil and debris. 10g of the roots were pounded into paste using a pestle and mortar. 40ml of water was then added to the paste and filtered with Whatman filter paper No. 1. The filtrate obtained was then administered to the rats. The crude extract was prepared on daily basis.

T. B. Ekanem, Department of Anatomy, Faculty of Basic Medical Sciences, University of Calabar, P.M.B. 1115, Calabar, Cross River State, Nigeria.

A. O. Ekeoma, Department of Anatomy, Faculty of Basic Medical Sciences, University of Calabar, P.M.B. 1115, Calabar, Cross River State, Nigeria.

M. A. Eluwa, Department of Anatomy, Faculty of Basic Medical Sciences, University of Calabar, P.M.B. 1115, Calabar, Cross River State, Nigeria.

A. O. Akpantah, Department of Anatomy, Faculty of Basic Medical Sciences, University of Calabar, P.M.B. 1115, Calabar, Cross River State, Nigeria.

Procedures

Twenty-five adult wistar rats weighing about 180-200g were used in this study. They were divided into four groups labeled A, B, C, D and E, with each group consisting of five rats. The filtrate obtained was administered to the rats both orally with the aid of orogastric tube and intraperitoneally with the aid of a syringe and needle.

The rats in groups A and B were given 0.38mg/Kg body weight (1.5ml) of the crude extract intraperitoneally and orally respectively. The rats in groups C and D were given 0.75mg/Kg body weight (3.0ml) of the extract intraperitoneally and orally respectively. The group E rats (control) were given equal volumes of distilled water daily. The administration lasted for seven days. The rats were then sacrificed on the 8th day using chloroform inhalation method. The

body weight of rats in each group was taken before and during the experimental period.

Histological analysis

The kidneys were removed, fixed in 10% buffered formalin for 48 hours, then processed, sectioned at 5µm and stained using haematoxylin and eosin staining method (Drury and Wallington, 1978).

Data analysis

The data obtained from body weight measurements was subjected to the statistical analysis using student t-test. The values were expressed as mean± standard error of mean. Values of $p > 0.05$ was taken as significant. Percentage decrease or increase in body weight was calculated.

RESULTS

Morphological changes

There was decrease in weight of the animals in the experimental groups as shown in table 1

Table 1: Effect of crude extract of the root of *Telfairia occidentalis* on body weight (BW) of rats.

Groups	Dosage g/kg body weight and route of administration	Number of rats	Initial mean body weight (g)	Mean BW (g) after seven days	% BW gain or loss
A	0.38mg/Kg Intraperitoneal	4	173±2.17	123.3±40.4*	-28.9
B	0.38mg/Kg Oral	5	2.70±22.1	180±35.0*	-33.3
C	0.75mg/Kg Intraperitoneal	1*	300±0	270±0*	-10
D	0.75mg/kg Oral	4	220±2.45	180±14.2*	-18.2
E	Control Distilled water	5	220.9.4	235±5.8*	+6.8

* = $p > 0.05$

* 4 animals died before the end of the study

The percentage decrease in weight was significantly ($p > 0.05$) greater in the oral groups than in the intraperitoneal groups (Table 1). There was reduction in food and water intake and the rats were dull throughout the experimental period of seven days. Some rats died during the experiment. In group A animals that received 0.38mg/kg body weight of the crude extract intraperitoneally, one animal died, and group B animals that received 0.38mg/kg of the extract orally, all the animals survived till the last day of administration. In group C animals that received 0.75mg/kg body weight of the extract intraperitoneally, four animals died out of five, one was sacrificed on the fifth day of administration because it was very weak. In group D that received 0.75mg/kg orally, one animal died while all the animals in group E (control) survived till the last day because they were given distilled water.

Histological study

Histological study of the kidney of the control group, E, using haematoxylin and eosin staining method showed the renal corpuscles made up of glomeruli and Bowman's capsules. Also seen were the proximal convoluted tubules, loops of Henle and distal convoluted tubules (plate 1).

In the group A animals administered 0.38mg/kg body weight of the crude extract intraperitoneally, the glomeruli were slightly enlarged with reduced Bowman's spaces and the tubules are dilated (plate 2).

In the group B animals administered 0.33mg/kg body weight of the crude extract orally, the histological features of the kidney showed distorted glomerulus compared to the control. The Bowman's spaces were

smaller and discontinuous. The tubules were dilated compared to the control (plate 3).

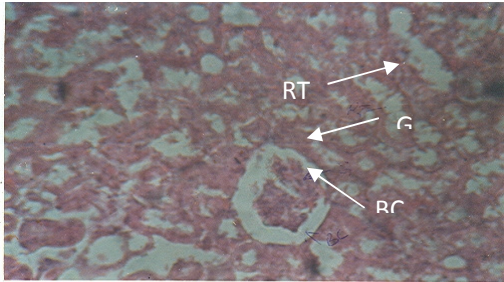
In group C animals that administered 0.75mg/kg body weight of crude extract intraperitoneally, there was

degeneration of the glomeruli and dilation of the tubules (plate 4).

In group D animals administered 0.75mg/kg body weight of the crude extract orally, there was total distortion of the renal cytoarchitecture (plate 5).

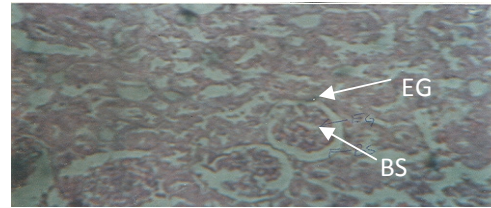
PHOTOMICROGRAPHS

Plate 1



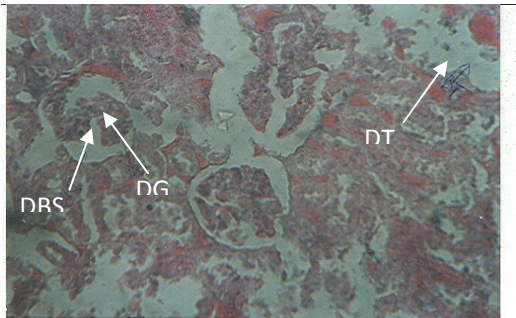
Photomicrograph of the kidney section of Group E (control), showing renal corpuscle consisting of glomeruli (G) and Bowman's capsule (BC) and the renal tubules (RT). Mag x 100 (H/E).

Plate 2



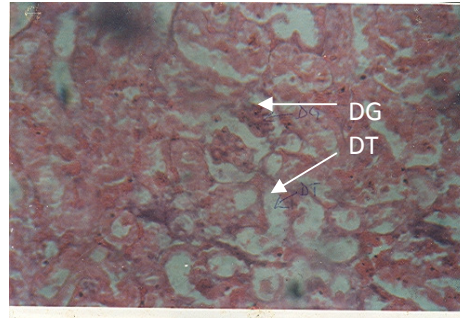
Photomicrograph of the kidney section of group A that received 0.38g/kg body weight of crude extract of *Telfairia occidentalis* intraperitoneally showing enlarged glomeruli (EG), reduced Bowman's space (BS). Mag x 100 (H&E).

Plate 3



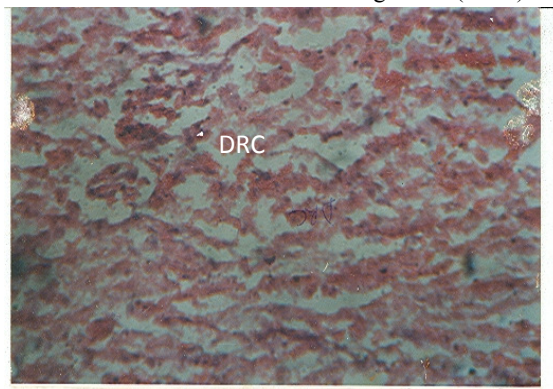
Photomicrograph of the kidney section of group B that received 0.38g/kg body weight of crude extract of *Telfairia occidentalis* orally showing distorted glomerulus (DG), distorted Bowman's space (DBS) and dilated tubules (DT). Mag x 100 (H&E).

Plate 4



Photomicrograph of the kidney section of group C that received 0.75g/kg body weight of crude extract of *Telfairia occidentalis* intraperitoneally showing degeneration of glomeruli (DG) and dilated tubules (DT). Mag x 100 (H&E).

Plate 5



Photomicrograph of the kidney section from group D that received 0.75g/kg body weight of crude extract of *Telfairia occidentalis* orally showing total distortion of renal cytoarchitecture (DRC).

DISCUSSION

The observation of significant reduction in weight of the animals, loss of appetite and death of some rats may be associated with the lethal effect of the alkaloids, saponin and glycoside content of the crude extract of the root of *Telfairia occidentalis*. Saponins when taken orally are relatively harmless as they are only slightly absorbed by the digestive tract (Tyler et al, 1981). Saponins have hemolytic properties and when injected into the blood stream are largely toxic especially to cold blooded animals and many saponins are used as fish poisons (Tyler et al, 1981) and many glucosides have formerly been used for poisoning arrows (Tyler et al, 1981).

Histologically, renal corpuscles, proximal and distal convoluted tubules were adversely affected by the oral and intraperitoneal administration of the crude extract of root of *Telfairia occidentalis* to rats in a manner similar to the report of Samter and Parker (1972), that the morphological sites for the adverse effect of drugs include, the tubules, interstitium, glomeruli and blood vessels. In the present study, dilation of the tubules and enlarged glomeruli seen in animals that received the crude extract of the root of *Telfairia occidentalis* orally and intraperitoneally may be due to increased tubular secretion, a mechanism employed to clear harmful toxins and drugs from the blood (Guyton and Hall, 1996).

Distortion and degeneration of glomeruli and total distortion of the kidney cytoarchitecture observed in the study may have been due to the effect of some components of the root of *Telfairia occidentalis* like the anthraquinone. Anthraquinone is not excreted by the kidney, on resorption stimulates calcium-binding proteins in the kidney to bind calcium. This therefore deposits calcium in the renal interstitium causing lithiasis. Lithiasis destroyed the interstitium, blood vessels and nephrons (Robbins et al, 2005).

The death of rats observed may have been due to renal failure. It has been reported that toxins and drugs may cause subtle but cumulative injury to the tubules, this might take years to become manifest resulting in chronic renal insufficiency. Renal failure is therefore a manifestation of cumulative effect of injury to the morphological sites of the kidney and may eventually lead to death (Guyton and Hall, 1996).

From this work, it can be concluded that the crude extract of the root of *Telfairia occidentalis* is nephrotoxic, effect being more pronounced in the animals, which were administered intraperitoneally.

REFERENCES

Ajayi, T. C., Omakaro, E. U. and Halin, N. K. D., 2000. Erythropoietic values of pumpkin leave extract *Telfairia occidentalis* in rabbits- a preliminary study. *Nig J Physiol Sciences*; (16): 1-2.

Asiegbu, J. E., 1987. Some Biochemical Evaluation of Fluted pumpkin seed. *J Food Science Agric*; vol 40: 151-155.

Arthur C. G., and John E. H., 1996. Textbook of Medical Physiology. 10th edition. W. B. Saunders Company. A Harcourt Health Sciences Company. Philadelphia, London, New York, St. Louis, Sydney. Pp 280-375.

Drury, R. A. B and Wallington, E. A., 1978. Carlton's Histological Techniques. 5th edition. Oxford University Press, London. Pp.98.

Ekanem, T. B., Ekwere, P. A., Eluwa, M. A., 2005. The effect of crude extract of root of *Telfairia occidentalis* (fluted pumpkin) on the histology of the liver of Wistar rats. *J Biomed Afric*; vol 3 no. 2: 30-33.

Eluwa, M. A., Otung, G. O., Udoaffah, G., Ekanem, T. B., Mesembe, O. E., Aligwekwe, A. U., 2006. Teratogenic effect of maternal administration of aloe vera extraction foetal morphology and histology of the fetal kidney. *Global Journals of Medical Sciences*; vol 5 no. 1: 41-44.

Gbile, Z. O., 1984. Vernacular names of Nigerian Plants. Forestry Research Institute of Nigeria. Ibadan. Conton Press W/A Ltd.

Irvine, F. R., 1969. Woody Plant of Ghana. Oxford University Press, London. pp 39-90, 406.

Iwu, M. N., 1983. Traditional Igbo Medicine. Report of a sponsored project by the Institute of African Studies, UNN, Nsukka. Pp 23

Kafaruk, E., 1998. Medicinal values of fluted pumpkin leaves. *The Guardian*. Thursday, July 20. pp. 26.

Odemena, C. S. and Essien, J. P., 1995. Antibacterial activity of the root extract of *Telfairia occidentalis* (fluted pumpkin). *West African Journal of Biology and Applied Chemistry*; 40: 1-4, 29-32.

Odemena, C. S. and Onyeneke, E. C., 1988. Lipids of fluted pumpkin (*Telfairia occidentalis*) seeds. First African Conference on Biochemistry of Lipids. Pp. 147-151.

Kumar, V. F. N. and Abbas, A., 2005. Robbins and Cotran Pathological Basis of Diseases. W. B. Saunders Company. 7th ed. Pp.469-995.

Samter, M. and Parker, W. C., 1972. International Encyclopaedia of Pharmacology and Therapeutics. 9th ed. New York. Pergamon Press Ltd. Pp. 243-249.

Sofowara, A., 1986. Medicinal Plants and Traditional Medicine in Africa. John Wiley and Son. Pp. 112.

Tyler, V; Vans, N; Bradt, R; Lynno, O., 1981. "Pharmacognosy" 5th ed. Philadelphia. Tee and Febiyer.

Telfairia occidentalis orally showing distorted glomeruli (DG), distorted Bowman's space (DBS) and dilated tubules (DT). Mag. X100. (H/E).

LIST OF PLATES

Plate 1: Photomicrograph of the histology of the kidney section of Group E (control) animal showing renal capsule consisting of glomeruli (G) and Bowman's capsule (BC) and the renal tubules (RT). Mag. X100 (H/E).

Plate 2: Photomicrograph of the histology of the kidney section of group A animals treated with 0.38mg/kg body weight of crude extract of *Telfairia occidentalis* intraperitoneally showing enlarge glomeruli (EG), reduced Bowman's space (BC). Mag. X100. (H/E).

Plate 3: Photomicrograph of the histology of the kidney section of group B animals treated with 0.38mg/kg body weight of crude extract of

Plate 4: Photomicrograph of the histology of the kidney section of group C animals treated with 0.75mg/kg body weight of crude extract of *Telfairia occidentalis* intraperitoneally showing degeneration of glomeruli and distal tubules (DT). Mag. X100. (H/E).

Plate 5: Photomicrograph of the histology of the kidney section of group A animals treated with 0.75mg/kg body weight of crude extract of *Telfairia occidentalis* orally showing total distortion of renal architecture (DRC). Mag. X100. (H/E).