

HISTOLOGICAL STUDIES OF THE PANCREAS OF WISTAR RATS FOLLOWING ADMINISTRATION OF NICOTIANA TABACUM (SNUFF)

M. A. ELUWA, N. O. IFEGWU, T. B. EKANEM AND A. O AKPANTAH

(Received 24 January 2006; Revision Accepted 25 February 2008)

ABSTRACT

This study was to find the probable effect of *Nicotiana tabacum* (snuff) on the histological features of the pancreas of adult wistar rats. *Nicotiana tabacum* is a product of smokeless tobacco which contains many toxins and high levels of nicotine. Twenty male wistar rats weighing 200-210g were used for this study. The control group received distilled water, while the experimental groups received 0.4mg/ml to 0.8mg/ml of snuff solution respectively for 6 weeks, orally with the aid of orogastric tube. Behavioral changes observed includes; polydipsia, polyuria, rapid discharge of faecal droppings, tremor, restlessness, and hyperpnoea. These observations were more intense in the group of animals that received 0.80mg/ml of snuff solution. Histological changes showed degeneration, vacuolation and necrosis of pancreatic acinar cells, hyperplasia of islet of Langerhans in the group that received 0.8mg/ml of snuff. These changes may be attributed to one or more constituents of snuff such as nicotine which has cytotoxic activity.

KEYWORDS: *Nicotiana tabacum*, histology, pancreas, wistar rats

INTRODUCTION

Nicotiana tabacum (snuff) is a term widely used for powdered tobacco (Plaide and Hoffmann, 1980). Snuff is one of the smokeless tobacco. Users in Nigeria take a pinch and place it between the lower lip or cheek and gum and suck on it. Some people in Nigeria prefer to sniff it. Although the major alkaloid in tobacco is nicotine, there are other alkaloids in tobacco which may be of pharmacological importance. These include nornicotine, anabasine, myosine, nicotinine and anatabine. These substances make up 8 to 12% of the total alkaloid content of tobacco product (Plaide and Hoffmann, 1980).

Routes of entry of nicotine into the body are via the oral, inhalation and dermal. Oral is through chewing tobacco leaves, sucking the flowers, eating as cooked green or ingesting infusion of tobacco leaves. Inhalation is by smoking or sniffing dried tobacco leaves. Dermal route of entry occurs through acute nicotine precutaneous absorption as has been reported in tobacco harvesters (Benowitz, 1987; Gehlbach, 1974). Most smokers use tobacco regularly because they are addicted to nicotine. Addiction is characterized by compulsive drug-seeking and use, even in the face of negative health consequences (NIH publication, 2004).

Smokeless tobacco delivers a high dose of nicotine. An average dose for snuff is 3.6mg, for chewing tobacco, 4.6mg compared to 1.8mg for cigarettes (Plaide and Hoffmann, 1980). Blood levels of nicotine throughout the day are similar among smokers and those of nicotine throughout the day are similar among smokers and those who use smokeless tobacco (Plaide and Hoffman, 1980). The stop in the use of tobacco cause symptoms of nicotine withdrawal that are similar to those smokers get when they quit such as depression, difficulty in concentration, restlessness, headache, tiredness and increased appetite (Plaide and Hoffmann, 1980).

Despite the wide consumption of tobacco by smoking, inhalation of dust and chewing in our society, still there is much to be known about its action on different organs, tissues and hormones. One of such is the pancreas. The pancreas is soft lobulated and elongated organ that lies more or less transversely across the posterior abdominal wall, at the level of the first and second lumbar vertebrae. It is partly exocrine and

partly endocrine. The exocrine part secretes digestive pancreatic juice; and the endocrine part secretes hormones (Chaurasia's, 2004). The hormones are synthesized in clusters of endocrine epithelial cells known as islets of Langerhans (Janqueira and Carneiro, 2003). It plays an essential role in the regulation of carbohydrate metabolism of the body (Copenhaver *et al*, 1979). The histological features of the pancreas may be altered due to some disease conditions or ingestion of toxic substances. The nicotine alkaloid content of *Nicotiana tabacum* is toxic to the body organs. The aim of this study therefore was to find out the effect of *Nicotiana tabacum* on the histological features of pancreas of adult wistar rats which has not been previously reported.

MATERIALS AND METHODS

Twenty adult male wistar rats weighing between 200-210g were procured and breed in the animal house of the Department of Anatomy, University of Calabar. They were kept under standard room temperature of 25-27°C. The animals were divided into four groups designated A, B, C and D, each consisting of five rats. The group A animals were the control and groups B, C and D were the experimental animals. They were fed with growers mash and water was provided *ad libitum*.

Drug preparation

Tobacco (snuff) was purchase from a snuff merchant at Ugep in Cross River State, Nigeria. 200mg of the snuff which was in powdered form was dissolved in 200mls of distilled water to form a solution which was administered orally with the aid of orogastric tube at various doses of 0.4mg/ml, 0.6mg/ml and 0.8mg/ml to the animals in the experimental groups B, C and D for a duration of six weeks. The animals in the control group A received equal volume of distilled water for the same duration. The solutions were prepared daily, left over after administration was discarded. The lethal dose (LD₅₀) of the snuff given to the rats orally is 50mg/kg (RTECS, 1986), so the doses were given based on LD₅₀ of 200g rats.

At the end of six weeks, the rats were sacrificed and pancreas dissected out, fixed in 10% buffered formalin and stained using Haematoxylin and Eosin method.

M. A. ELUWA, Department of Anatomy, Faculty of Basic Medical Sciences, University of Calabar, P.M.B 1115, Calabar, Cross River State, Nigeria

N. O. IFEGWU, Department of Anatomy, Faculty of Basic Medical Sciences, University of Calabar, P.M.B 1115, Calabar, Cross River State, Nigeria

T. B. EKANEM, Department of Anatomy, Faculty of Basic Medical Sciences, University of Calabar, P.M.B 1115, Calabar, Cross River State, Nigeria

A. O AKPANTAH, Department of Anatomy, Faculty of Basic Medical Sciences, University of Calabar, P.M.B 1115, Calabar, Cross River State, Nigeria

RESULTS

At the end of six weeks, there was significant effect of the snuff on the weights of the experimental rats as compared with the control. However increased intake of water (polydipsia) and urine output (polyuria) were observed in groups B, C and D, especially in group D. After daily administration of snuff, other observations made included: rapid discharge of faecal droppings, tremor, restlessness and increased respiratory rate (hyperpnoea). These signs decreased as the day of administration prolonged.

Histological observations

Histological study of the pancreas using Haematoxylin and Eosin staining method showed in the control group A, prominent and normal pancreatic acinar cells and islet of Langerhans (plate 1). The pancreas of group B animals that received 0.4mg/ml of snuff solution showed, hypertrophy of pancreatic acinar and hyperplasia of the islet of Langerhans (plate 2). Sections of the pancreas from group C animals treated with 0.6mg/ml of snuff solution showed degeneration of pancreatic acinar, necrosis and hyperplasia of the islet of Langerhans (plate 3). The pancreas of group D animals that received 0.8mg/ml of snuff solution showed vacuolation of degenerating pancreatic acinar and hyperplasia of the islet of Langerhans with many areas showing degenerate (plate 4).

PHOTOMICROGRAPHS

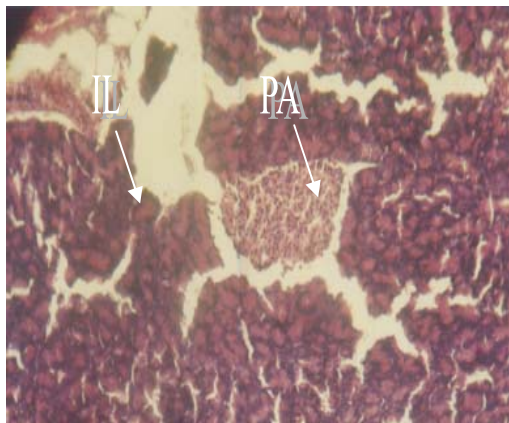


Plate 1

Photomicrograph showing pancreatic section of group A (control) having normal and prominent pancreatic acinar (PA) and islet of Langerhans (IL).

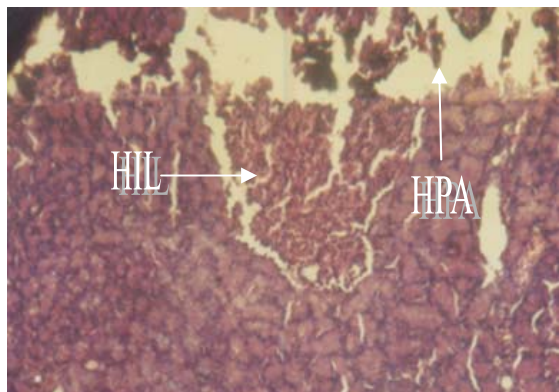


Plate 2

Photomicrograph showing effects on the pancreatic section of group B that received 0.4mg/ml of snuff solution with hypertrophy of pancreatic acinar (HPA) and hyperplasia of islet of Langerhans (HIL)

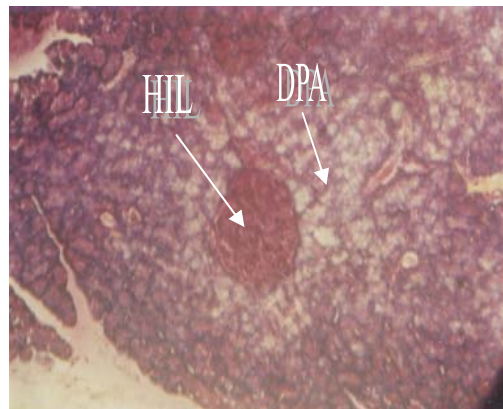


Plate 3

Photomicrograph showing the effects on the pancreatic sections of group C that received 0.6mg/ml of snuff solution showing degeneration of pancreatic acinar (DPA) and hypoplasia of the islet of Langerhans (HIL)

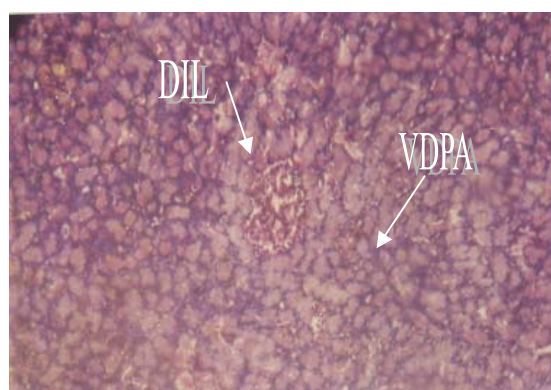


Plate 4

Photomicrograph showing the effects on the pancreatic section of group D that received 0.8mg/ml of snuff solution showing vacuolation of the degenerating pancreatic acinar (VDPA), hypoplasia and degeneration of the islet of Langerhans (DIL)

LEGEND

PLATE I: Histology of pancreas from control rats showing normal and prominent pancreatic acinar and islet of Langerhans. Mag X500 (H & E).

PLATE II: Histology of pancreas from rats treated with 0.4mg/ml of snuff solution showing hypertrophy of pancreatic acinar and hyperplasia of islet of Langerhans. Mag X500 (H & E).

PLATE III: Histology of the pancreas from rats treated with 0.6mg/ml of snuff solution showing degeneration of pancreatic acinar and hypoplasia of the islet of Langerhans. Mag X500 (H & E).

PLATE IV: Histology of pancreas from rats treated with 0.8mg/ml of snuff solution showing vacuolation of the degenerating pancreatic acinar, hypoplasia and degeneration of the islet of Langerhans. Mag X500 (H and E).

DISCUSSION

In this study, polydipsia and polyuria observed in groups B, C and D was due to the stimulating action of nicotine content of snuff on the exocrine portion of the pancreas leading to secretion of large quantities of pancreatic juice, water and bicarbonate ions. These findings are in correlation

to the findings of Osim (2002) who reported that if the pancreas is stimulated, large quantities of pancreatic juice, large quantities of water and bicarbonate ions are secreted. The rapid discharge of faecal droppings may be due to the parasympathetic stimulation of the gastrointestinal tract triggered by the nicotine content of the snuff. Kikendall (1984) stated that the effect of nicotine on the gastrointestinal tract was due largely to parasympathetic stimulation. The combined action of the parasympathetic ganglia and cholinergic nerve endings result in increased tone and motor activity of the bowel.

The tremor, restlessness and increased respiratory rate (hyperpnoea) observed in the treated group may be due to the stimulatory action of nicotine on the adrenal gland resulting in the discharge of epinephrine (adrenaline). NIH publication (2004) reported that nicotine can act both as a stimulant as well as sedative. According to the publication, immediately after exposure to nicotine, there is "kick" caused in part by the drug's stimulation of the adrenal glands and resulting in discharge of adrenaline. The rush of the adrenaline stimulates the body and causes a sudden release of glucose as well as increase in blood pressure, respiration and heart rate. The central nervous system according to the report of USDHHS (1988) is affected, initially by the stimulation resulting in tremors and convulsions progressing to depression.

The vacuolation and degeneration of the pancreatic acinar, hyperplasia of the islets of Langerhans showing areas of degeneration may be due to the damage areas causing degeneration and vacuolation of the pancreatic acinar cells. Guyton and Hall (1996) in their work on the pancreas observed that when pancreas is severely damaged or when the duct is blocked, large quantities of pancreatic secretion becomes pooled in the damaged areas of the pancreas, under this condition the effect of trypsin inhibitor secreted by proteolytic enzymes is overwhelmed in which case the pancreatic secretion rapidly becomes activated and literally digest the entire pancreas. The vacuolation, degeneration and hyperplasia of the islet of Langerhans, whose cells produce insulin indicates adverse effect on insulin production. The work of NIH publication (2004), reported that nicotine suppresses insulin output from the pancreas, which means that smokers are always slightly hyperglycemic and likely to suffer from diabetes mellitus. From our results, it can be concluded that snuff ingestion affects the histological features of the pancreas and as such is capable of inducing pancreatic necrosis, pancreatitis, and diabetes mellitus. Hence snuff intake is dangerous to health and its effect is dose-duration dependent, thus its use should be discouraged.

REFERENCES

- Benowitz, N. L., 1987. The pharmacology of nicotine proceeding, satellite symposium of the tenth International Congress of Pharmacology, Gold Coast, Queensland, IRL press, Washington DC, pp. 11-14.
- Chaurasia's, B. D., 2004. Human Anatomy, Vol. 2, 4th Ed, CBS Publishers and Distributors
- Copenhaver, W. M.; Kelly, D. E.; Wood, R. L., 1979. Bailey's Textbook of Histology, 6th Ed., William and Wilkins, Baltimore/London,
- Gehlbach, S. H., 1974. Green tobacco sickness. An illness of tobacco harvesters. J. Am. Med. Assoc. 229: 1880-8.
- Guyton, A. C. and Hall, J. E., 1996. Textbook of Medical Physiology, 9th Ed. W. B. Saunders Company, Philadelphia, pp. 824.
- Janqueira, L. C. and Carneiro, J., 2003. Basic Histology Text and Atlas, 10th Ed., Lang International Edition, London.
- Kikendall, J. W., 1984. Effect of cigarette smoking on the gastrointestinal physiology and non-neoplastic digestive disease. J. Clin. Gastroenterol, 6: 65-79.
- NIDA, 2004. Research Report. Nicotine Addiction, NIH publication NO. 98-4342.
- Osim, E. E., 2002. Elements of gastrointestinal tract physiology. Helimo Associates, Calabar.
- Plaide, J. J. and Hoffmann, D., 1980. Chemical studies on tobacco smoke by liquid chromatography. J. Liquid Chromatography 3 (10): 1505-1515.
- Registry of toxic effects of chemical substances, 1986. RTECS. NOSH (Vol. 3A) 3060-424.
- United States Department of Health and Human Services, 1988. USDHHS. Nicotine addiction. The health consequences of smoking. A report on the surgeon general, 32-33; 601-602.