

# EFFECT OF *CARICA PAPAYA* (PAW-PAW) SEEDS ETHANOLIC EXTRACT ON THE PITUITARY, THYROID and PARATHYROID GLANDS OF MALE WISTAR RATS.

P. UDOH, R. NJU and F. UDOH

(Received 6 October, 2003; Revision Accepted 25 March, 2004)

## ABSTRACT

Activities of *carica papaya* seeds extract on the pituitary, thyroid and parathyroid glands of rats were investigated. The ethanol extract of *C. papaya* seeds (50 and 200 mg/kg) was administered orally daily to sexually mature male wistar rats for one and eight weeks. Histology of pituitary and thyroids were prepared. The thyrotrophs (TSH cells) of anterior pituitary showed progressive hypertrophy and degranulation at high dose levels of 200 mg/kg for one and eight weeks respectively. Acidophils somatotrophs (STH cells) and Lactotrophs or prolactin cells (LTH/PRL cells) showed no significant changes in both the experimental groups as compared to control. However, the thyroid glands of rats that were treated with 200 mg/kg extract showed pronounced hypertrophy, hyperplasia and degranulation with many empty follicles devoid of colloid. The parathyroid glands appeared normal. These observations showed possible side-effects of the *C. papaya* seeds in rats.

**KEY WORDS:** *Carica papaya*, pituitary, thyroid, parathyroid, wistar rats

## INTRODUCTION

*Carica papaya* (Caricaceae) is a fruit plant commonly called pawpaw. The plant is cultivated throughout the tropics by seeds.

In Nigerian traditional medicine, roots, fruits, seeds and leaves of *C. papaya*. *C. papaya* are used for the treatment of various ailments like hypertension, malarial fever, typhoid fever, diabetes mellitus, hypoglycemia and so forth. The seed extract of *C. papaya* has been studied for its activity on male reproductive system (Udoh and Kehinde, 1999). It has been found that the seed extract of *C. papaya* induced suppression of spermatogenesis and infertility in male rats (Lohiya et al, 1994).

The *C. papaya* seeds also contain protein, carbohydrates, fatty acids, an enzyme carpapain, a plant growth inhibitor caricacin (Casey, 1969) and benzylisothiocyanate (Georges and Pandelaj, 1949). They also contain oleanolic glycoside (76-78% of oleic acid in oil of seeds). This particular constituent is known to cause infertility in male rats (Das, 1980).

The aim of the study was to examine the histological changes of the pituitary-thyroid and parathyroid axes as a result of possible side effects of the seeds extract. This could aid in determining the possible mechanism of action of the seeds extract. We have conducted a similar investigation on the pituitary-gonadal axis (Udoh et al, 2003) of the seeds extract.

## MATERIALS AND METHODS

Ripe fruits of *Carica papaya* were obtained from Watt market in Calabar South Local Government Area of Cross River State, Nigeria within the months of January and May 1999.

## EXTRACTION PROCEDURE

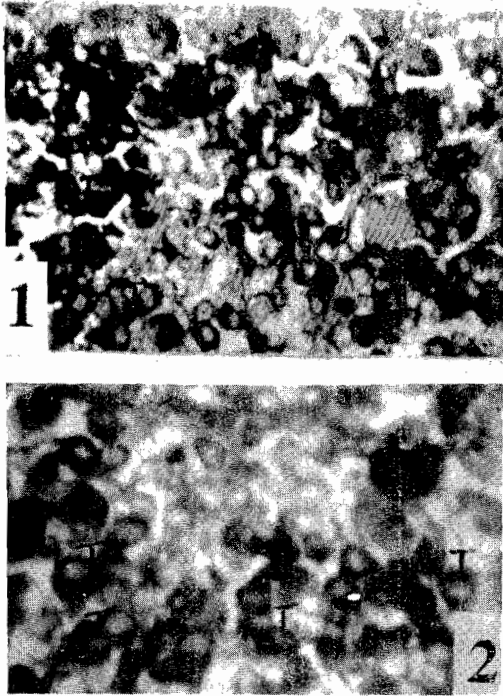
The ripe seeds were removed and oven dried at 80°C for 48hrs. they were milled into fine powder using kitchen blender (Osterizer). Ethanol extraction with Bulk's method was used. One litre of 96% ethanol was mixed with the dry powder and allowed to stand for 24hrs. The brown coloured mixture was then filtered and the liquid was left for 48hrs to evaporate the ethanol completely. The final product was a thick brown syrup with sharp smell and pepperish taste. This served as ethanol extract of *Carica papaya* seeds.

## TREATMENT OF ANIMALS

Sexually mature male wistar rats ranging from 6-8 months old, weighing 150-350g and of proven fertility were used. They were divided into 3 groups: Control (group 1) and two experimental group 2 and 3 of 6 animals per group. All animals were housed in cages in a hygienic well-lighted and ventilated room. They were fed food pellets (Top Feeds Ltd, Sapele, Nigeria) and water was provided *ad libitum*. Weighed doses of the extract, 50 and 200 mg/kg body weight were mixed with corn oil as vehicle and fed to the animals by oral intubation, for 1 and 8 weeks. The control group was fed the vehicle only.

At the end of the treatment periods the animals were sacrificed by cervical dislocation 24hrs after the last treatment, i.e half of the animals in each group were sacrificed at the end of one week while the other half were sacrificed at the end of 8 weeks.

The thyroids with parathyroids were dissected out and fixed in Bouin's fluid, while pituitaries were fixed in formal sublimate for 24hrs, washed in running tap water for 6-8 hrs. All tissues were preserved in 70% alcohol and processed for microthomy. Sections of thyroids with parathyroids were stained with hematoxylin and eosin (H&E). Pituitary sections were stained with



Figs 1, 2: Anterior Pituitary of control and treated rats showing thyrotrophs (T Cells). Fig 2 shows progressive hypertrophy and degranulation in both the experimental groups (50 and 200 mg/kg) (x 200, AF/LG/OG stain).

Halmi (1952) and Crossmon (1937) techniques to identify TSH, STH and LTH/PRL cells.

#### RESULTS: HISTOPATHOLOGY

With aldehyde fuchsin- light green-orange G staining techniques (AF/LG/OG) (Halmi, 1952), AF<sup>+</sup> cells were identified as thyrotrophs (TSH cells). Two types of acidophils (STH and LTH cells) were differentiated with Crossmon (1937) staining techniques. With this technique, STH cells were yellow (OG<sup>+</sup>) while LTH/PRL cells were red (acid fuchsin positive). Identification of these cell types in the rat and other mammals was confirmed by previous investigators on the basis of the changes observed during the different physiological state of the animals and immunohistochemistry (EL Etreby et al. 1972); Baker, 1974 and Patil, 1976).

The thyrotrophs showed progressive hypertrophy and degranulation in both the experimental groups from low to high dose (Figs. 1-2). STH and PRL cells showed no significant changes in both the experimental groups as compared to controls.

#### Thyroid

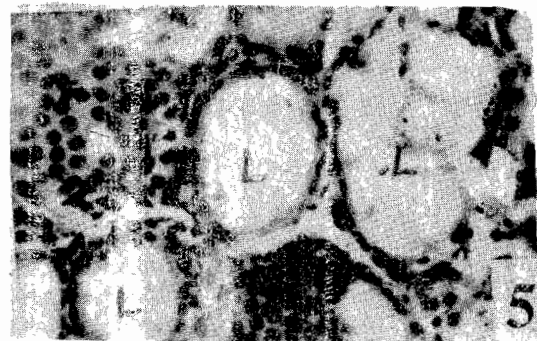
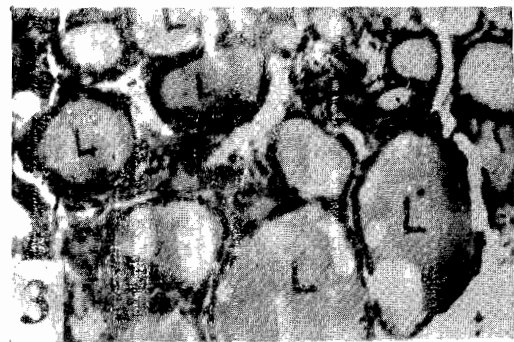The thyroid follicles showed pronounced hypertrophy, hyperplasia and degranulation at high dose, while the lumina were devoid of colloid. The parathyroid glands appeared normal.

#### DISCUSSION

In our previous work (Udoh and Kehinde, 1999), we reported similar effects on gonads (testes and

epididymes). Here we have observed further similar effects on thyroid and parathyroid glands.

In the present study the extract induced hypertrophy, hyperplasia and degranulation of the thyroid follicles and reduction of colloid. The seeds extract also caused hypertrophy and degranulation of the anterior pituitary TSH cells. These effects were similar to those of goitrogen compounds. The findings were in accord with those of Lin et al (1990) and Udoh and Patil (1992). It appeared the mechanism of action of the extract on thyroid was similar to goitrogen compounds which caused deficiency of thyroxine synthesis. Deficiency of circulating thyroxine elicited an augmented output of TSH by anterior pituitary which caused hypertrophy, hyperplasia and degranulation of the thyroid epithelium and loss of colloid



Figs 3, 4 and 5: The thyroid follicles of control and treated rats. Figs 4 and 5 show pronounced hypertrophy, hyperplasia and degranulation at 200 mg/kg. The lumina (L) are also devoid of colloid as compared to control (fig 3) (x 200 H & E stain).

(hypothyroidism), (Turner, 1966). Thyroid regulates male reproduction by maintaining gonadal biochemical homeostasis and synergizing the action of gonadotrophins for steroidogenesis (Panda and Jindal, 1980). Thyroidectomy inhibits spermatogenesis and development of Leydig cells in rats (Choudhary *et al*, 1985). These antithyroid activities of the extract augmented its antifertility action.

It can be concluded from this study that *C. papaya* extracts is a potent male antifertility agent with serious endocrine side effects. However further study is require to determine its minimal effective dose without the side-effects.

## REFERENCES

- Baker, B. L., 1970. Functional cytology of the hypophyseal pars distalis and par intermedia: in Hand book of Physiology, Section 7, vol IV Pp 45-80. Greep, R. O. and Astwood, E. B. eds. Washington, D. C. American Physiological Society.
- Casey, R. D. C., 1969. Alleged antifertility plants of India, Indian J. Med Sci. 14: 590 – 600
- Choudhary, D. W., Singh, J. N., Verma, S. K. and Sing, B. P., 1990. Antiferility effects of leaf extracts of some plants in male rats. Indian J. Exp. Biol 28: 714 – 16.
- Crossmon, G. C., 1937. A modification of Mallory's connective tissue stain with a discussion of principle involved Anat. Rec. 69: 33 – 38
- Das, R. P., 1980. Effect of papaya seeds on the genital organs and fertility of male rats. Indian J. EXP. Biol 18: 408 - 409
- El Etreby, M. F., Richter, R. K. and Gunzel, P., 1972. Histological and histochemical differentiation of the glandular cells of anterior pituitary in various experimental animal. Excerpt. Med Intern. Congress Sereis N0 228.
- Georges, M. and Pandelai, K. M., 1949. Investigation on plants antibiotics IV. Further search for antibiotic substances in Indian Medicinal Plants. Indian J. of Med. Res, 37: 169 -18.
- Halmi, N. S., 1952. Two types of basophils in rats pituitary: thyrotrophs and gonadotrophs viz. beta and delta cells. Endocrinol. 50: 140 – 42.
- Lin, Y. C., Chitchareonnthum, M. and Rikihisa, Y., 1990. Effect of gossypol on thyroid hormones in young female rats. Contraception 41(4): 431 – 40
- Lohiya, N. K., Goyal, R. B., Jaya Prakash, D., Ansari, A. S and Sharma, S., 1994. Antifertility effects of equeous extracts of *C. papaya* seeds in male rats. Planta Medical, 60(5): 500 - 504.
- Nadkarni, K. M., 1954. India Materia Medica, 3<sup>rd</sup> ed Popular Book Deport, Dhorth a papeshwar Prakashan, Bombay, Pp. 273 – 277.
- Panda, J. N. and Jindal, S. K., 1980. Effect of thyroidectomy and adrenalectomy on the physiochemical status of rats testes. Andrologia 12 (5): 444 - 47
- Patil, D. R., 1976. Cytology of the pituitary gland of plains viscacha (*Lagostomus Maximus*) J. Zool. London. 178: 189 - 208.
- Turner, C. D., 1966. General Endocrinology (4th ed.) W. B. Saunders Co. Philadelphia, London.
- Udoh, P and Patil, D. R., 1992. The effect of gossypol acetate on pituitary - thyroid and parathyroid gland of male albino rats. Indian J. Comp. Animal Physiol. 10 (2): 66 – 72
- Udoh, P. and Kehinde, A., 1999. Studies on antitertility of paw paw seeds (*carica papaya*) On the gonads of male albino rats. Phytotherapy Research 1(3): 226 – 28
- Udoh, P., Essien, I. and Udoh, F., 2003. Effect of carica papaya (paw paw) seed extract on the morphology of pituitary – gonadal axis of male wister rats. Phytotherapy Research 9 accepted, in press).