

# PERFORATED PEPTIC ULCER DISEASE IN CHRONIC NSAID USE: CASE OF A PATIENT WITH LONG-STANDING DENTAL INFECTION

Boamah M.O.<sup>1,2</sup>, \*Blankson P.K.<sup>1,2</sup>, Ametefe E.<sup>3</sup>, Appiah B.D.<sup>2</sup>, Afram D.<sup>2</sup>, Parkins G.E.<sup>1,2</sup>

<sup>1</sup> Department of Oral and Maxillofacial Surgery, University of Ghana Dental School

<sup>2</sup> Oral and Maxillofacial Surgery Unit, Korle Bu Teaching Hospital

<sup>3</sup> Department of Surgery, Korle Bu Teaching Hospital

\*Corresponding Author: Paa Kwesi Blankson, Oral and Maxillofacial Surgery Unit, Korle-Bu Teaching Hospital, Accra, Ghana.

Correspondence e-mail: [pkblankson@yahoo.com](mailto:pkblankson@yahoo.com), [p.blankson@kbth.gov.gh](mailto:p.blankson@kbth.gov.gh).

DOI: <https://dx.doi.org/10.4314/gdj.v21i1.10>

## ABSTRACT

Non-steroidal anti-inflammatory drugs (NSAIDs) account for the largest group of over-the-counter medicines used for self-medication, as dental infections account for one of the common symptoms that leads to self-medication in Africa. We report and discuss a patient who presented to our facility on account of perforated peptic ulcer disease and concomitant bilateral submandibular and submental abscesses from a chronic tooth infection. Medical history revealed long-standing use of NSAIDs as self-medication for the toothache. With the known role of NSAIDs in the pathogenesis of peptic ulcer disease, the public should be educated on its potential complications and should NSAIDs be overly relied on rather than seeking appropriate oral care.

**KEYWORDS:** Peptic Ulcer Disease, Odontogenic infection, NSAID, Ghana.

## INTRODUCTION

Non-steroidal anti-inflammatory drugs (NSAIDs) have a significant role in pain management and therapy universally and constitute one of the largest groups of pharmaceutical agents used all over the world<sup>1,2</sup>. NSAIDs mitigate pain, fever, and inflammation through the interference of the Cyclooxygenase (COX) pathway, resulting in the inhibition of prostaglandin and other eicosanoid synthesis.<sup>3</sup> Through this mechanism, however, there is the risk of gastrointestinal mucosal lesions, bleeding, peptic ulcer, inflammation, perforations, and strictures from prolonged NSAID use.<sup>4</sup> Though NSAIDs do not all carry the same risk for mucosal damage, it is reported that 30-50% of NSAID users have endoscopic lesions, many without clinical manifestations. Peptic ulcer disease (PUD) presents a typical demonstration of such mucosal damage in the alimentary canal.

It is estimated that some two billion people globally suffer from dental caries of permanent teeth, with the prevalence likely to increase.<sup>5</sup> Despite the high prevalence, many cases of dental infections remain untreated, especially in low-resourced communities due to the high cost of treatment and access to services.<sup>6</sup> It is not surprising, therefore, that many people resort to self-medication to mitigate the pain associated with extensive dental caries.<sup>7</sup> While toothache experience is very common in many communities, the prevalence of self-medication is reported to range from 25.2%-94.2% among different populations in Ghana.<sup>8</sup> NSAIDs have been reported to account for the largest group of over-the-counter medications used for self-medication<sup>9</sup>, as dental infections account for one of the common symptoms that resulted in self-medication in Africa.<sup>10</sup>

We report here a patient who presented at our emergency unit on account of perforated peptic ulcer disease and concomitant bilateral submandibular and submental abscess from a chronic tooth infection. Medical history revealed long-standing use of NSAIDs as self-medication for the toothache.

## CASE REPORT

A 54-year-old man presented to the Emergency Department of our facility with severe abdominal pain,

which had gradually started a week prior to the presentation. The pain, which was initially intermittent and localized to the epigastric and left hypochondriac region, later became generalized and constant. The patient also had swelling in the lower jaw. He had experienced episodes of fever and constipation (4 days) but had no symptoms of vomiting, melena stools, or abdominal distension. He had recurrent incidents of toothache for 2-year's duration. Over the period, he had frequently used various over-the-counter pain medications for the toothache, with the common one being a Diclofenac, which he had on him at presentation. He estimated his daily intake to be about 2-4 tablets of what he had on him for the periods he experienced toothache. He did not seek professional medical or dental consultation prior to the presentation, and had no known systemic illness.

On examination, the patient looked acutely ill with mild pallor, moderate dehydration, bilateral submandibular and submental swelling which was more pronounced on the right side, with purulent discharge, and trismus. There was also an associated area of fasciitis in the right submandibular region (Figure 1). Intra-oral examination revealed extensive caries of the right first mandibular molar with intraoral sinus discharging pus (Figure 1a and b).

The abdomen was tensed, distended, tender with rebound tenderness, and absent guarding. A digital rectal examination revealed hemorrhoids in the 3-o'clock position, enlarged prostate, and greenish stool. Routine hematological and biochemical investigations (Full Blood Count, Blood urea, electrolytes, creatinine, Liver Function Test) showed normal values other than a hemoglobin count of 9g/dL. The chest radiograph showed evidence of subdiaphragmatic gas collection (Figure 2). Dental radiograph services were not available late in the patient's presentation.

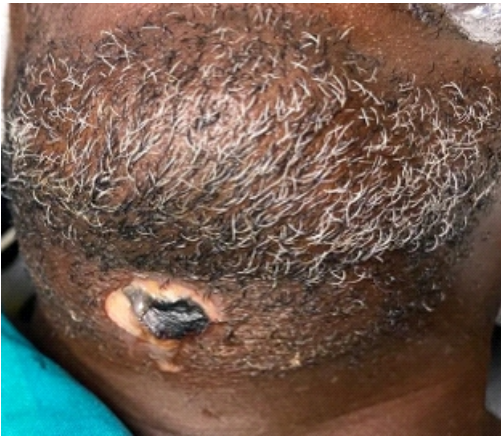

Figure 1(a): Submandibular swelling with region of fasciitis

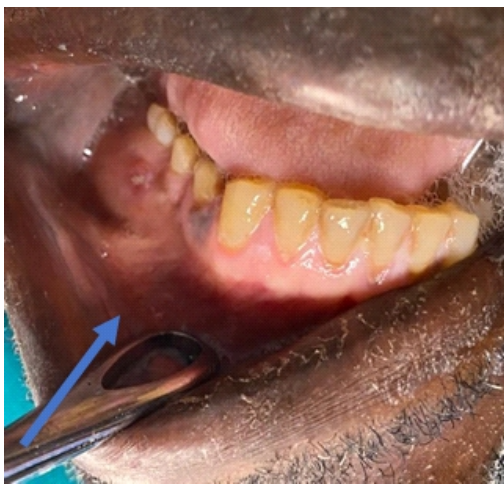

Figure 1(b): Parulis and buccal abscess associated with lower right 1st molar tooth.

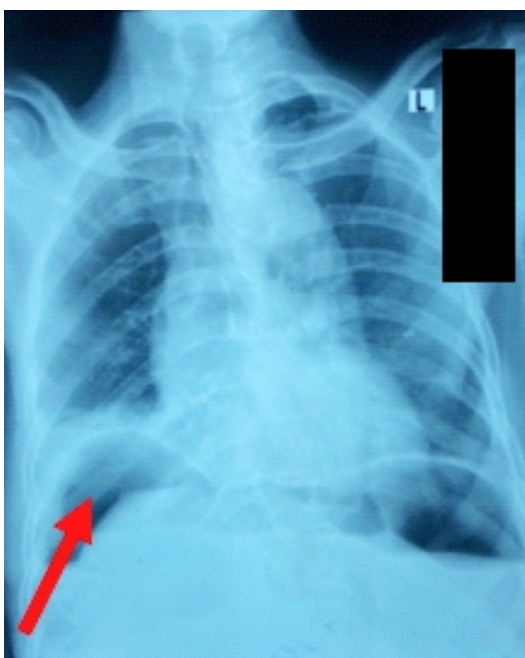


Figure 2: Routine chest radiograph showing subdiaphragmatic gas collection

The diagnoses made were Peritonitis secondary to peptic ulcer from NSAID abuse, and necrotizing fasciitis secondary to an odontogenic infection. Resuscitation protocol was commenced, and patient prepared for emergency surgery by the general surgery and maxillofacial surgery teams.

With routine laparotomy procedures, intraoperative exploration revealed a perforation of about 15mm in its widest diameter in the duodenal region (Figure 3). This was repaired with a modified Graham's patch. The repair seal was tested by submerging the site under normal saline and injecting air into a nasogastric tube, indicating the absence of bubbles. Standard closure, cleaning, and dressing were done. While maintaining a strict sterile barrier, routine cleaning of the mouth and face was done, and a thorough examination was completed. Extraction of the offending tooth (lower right first molar) and a retained root of upper left first molar were done. Debridement was made with abscess drainage and copious irrigation using 50% hydrogen peroxide and Savlon preparations. Hemostasis was secured, and dressing was done.

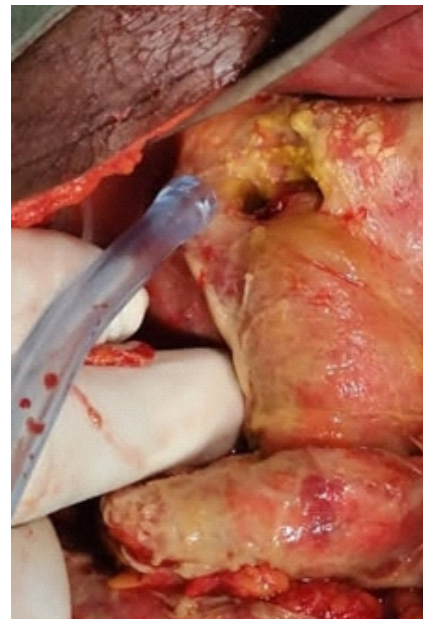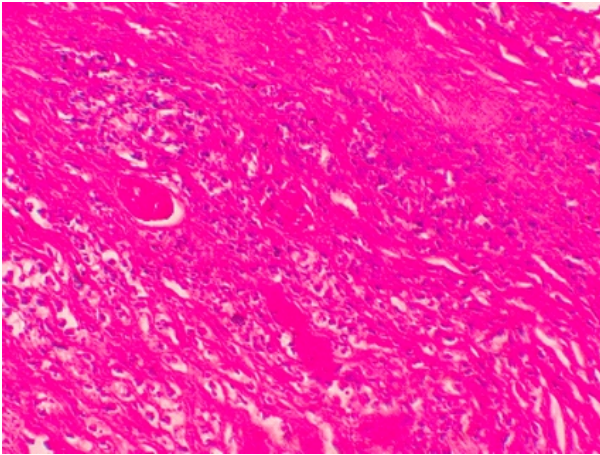


Figure 3: Perforated duodenal ulcer

Antibiotics used were IV Amoxiclav 1.2g 8hrly and IV Metronidazole 500mg 8hrly. Post-operatively, the patient was assessed daily, with continuation of antibiotics and analgesics. Routine dressing and soft tissue management of the debrided region was done with post-extraction care. Daily dressing was done with a mixture of 50% Hydrogen Peroxide and Povidone Iodine after wound cleaning. Persisting limited mouth opening was managed with the use of a trismus screw. The patient recovered uneventfully and was discharged post-op day 5.

Histopathological evaluation (Figure 4) of the surgical specimen was consistent with the diagnosis of a perforated peptic ulcer disease.





**Figure 4: Histopathological view of the excised lesion, showing chronic inflammatory cells and granulation tissue with necrosis at the base of the ulcers and its margins and the presence of fibrous scars.**

## DISCUSSION

This case, in an unusual circumstance, connects two important clinical entities of clinical concern: peptic ulcer disease and severe odontogenic infections. Our patient had a long-standing history of NSAID abuse on account of a toothache, likely increasing his risk for the presenting condition.

Peptic ulcer disease is a clinical manifestation of ulceration in the inner lining of the gastrointestinal tract that extends beyond the mucosa into the submucosal layers.<sup>11</sup>

The condition may be asymptomatic at the onset, with relatively milder symptoms of dyspepsia. As the disease progresses, complications could arise, such as bleeding, gastric outlet obstruction, sepsis, and perforation, as presented in our patient.<sup>12</sup> Although *Helicobacter pylori* infection is known to be associated with PUD, other risk factors include higher alcohol consumption, smoking, diabetes, and stress.<sup>11</sup> In addition, a significant etiology for the presence of PUD is the use of NSAIDs.<sup>13</sup> The evidence indicating the impact of NSAIDs on the mucosal lining is overwhelming, thereby necessitating the call for public education in this regard. In our patient, the possible indicator was his admission to the persistent chronic use of NSAIDs, particularly 100mg of Diclofenac, which he sometimes used beyond the required daily doses.

Beyond the concern of long-standing self-medication, our patient could not access appropriate care for an obvious persistent toothache. This might be the situation for many people, as the prevalence of untreated dental caries is about 40.4% in the Ghanaian population.<sup>14</sup> This figure is similar to other studies in similar populations in the region: Nigeria (11.2% and 48.0%)<sup>15</sup>, East Africa (45.7%)<sup>16</sup>. Most cases of advanced dental caries would require clinical expertise beyond pharmaceuticals. Though an individual's response would depend on several factors: socioeconomic status, educational level, awareness, availability, affordability, public oral health education must be prioritized to create awareness. Aside from the potential complications of severe odontogenic infections<sup>17</sup>, this present case report highlights the complication associated with self-medication for a persistent dental infection.

Dental caries is an individual experience but of public concern. Aside from a global economic cost of \$544.41

billion<sup>18</sup>, dental diseases have considerable intangible costs in the form of pain, psychological distress, loss of function, and even systemic sequelae of infection. This report illustrates how untreated dental infection could interact with a seemingly unrelated condition.

## CONCLUSION

With the known role of NSAIDs in the pathogenesis of peptic ulcer disease, the public should be educated on its potential complications should NSAIDs be overly relied on rather than seeking appropriate oral care.

## REFERENCES

- Jain S, Upadhyaya P, Goyal J, et al. A systematic review of prescription pattern monitoring studies and their effectiveness in promoting rational use of medicines. *Perspect Clin Res.* 2015;6(2):86. doi:10.4103/2229-3485.154005
- van Rensburg R, Reuter H. An overview of analgesics: NSAIDs, paracetamol, and topical analgesics Part 1. <https://doi.org/10.1080/2078619020191610228>. 2019;61:S4-S10. doi:10.1080/20786190.2019.1610228
- Osafo N, Agyare C, Obiri DD, et al. Mechanism of Action of Non-steroidal Anti-Inflammatory Drugs. *J Rheumatol.* 2017;18(SUPPL. 27):120-121. doi:10.5772/68090
- Sinha M, Gautam L, Shukla PK, Kaur P, Sharma S, Singh TP. Current perspectives in NSAID-induced gastropathy. *Mediators Inflamm.* 2013;2013. doi:10.1155/2013/258209
- WHO. Oral health. Published 2022. Accessed February 19, 2023. <https://www.who.int/news-room/fact-sheets/detail/oral-health>
- Peres MA, Macpherson LMD, Weyant RJ, et al. Oral diseases: a global public health challenge. *Lancet (London, England).* 2019;394(10194):249-260. doi:10.1016/S0140-6736(19)31146-8
- Olawuyi A, Ibrahim L, Uti O, Olawuyi A, Ibrahim L, Uti O. Self-Medication for Oral Health Problems among Dental Outpatients at a Nigerian Tertiary Hospital. *Open J Stomatol.* 2018;9(1):9-20. doi:10.4236/OJST.2019.91002
- Cobbold J, Morgan AK, Kwame A, Holds M, Miceli NS. An integrative review of the prevalence, patterns and predictors of self-medication in Ghana. <https://doi.org/10.1080/2770757120222098567>. 2022;9(1). doi:10.1080/27707571.2022.2098567
- Tesfamariam S, Anand IS, Kaleab G, et al. Self-medication with over the counter drugs, prevalence of risky practice and its associated factors in pharmacy outlets of Asmara, Eritrea. *BMC Public Health.* 2019;19(1):1-9. doi:10.1186/S12889-019-6470-5/TABLES/3
- Yeika EV, Ingelbeen B, Kemah BL, Wirsiy FS, Fomengia JN, van der Sande MAB. Comparative assessment of the prevalence, practices and factors associated with self-medication with antibiotics in Africa. *Trop Med Int Heal.* 2021;26(8):862-881. doi:10.1111/TMI.13600

11. Graham DY, Khalaf N. Peptic Ulcer Disease. *Geriatr Gastroenterol* Second Ed. Published online June 5, 2023;1565-1595. doi:10.1007/978-3-030-30192-7\_63
12. Kotha A, Kumar VA, V. GK. A study on surgical complications of peptic ulcer disease: a prospective study at a tertiary care center. *Int Surg J*. 2020;7(2):408-413. doi:10.18203/2349-2902.ISJ20200288
13. Drini M. Peptic ulcer disease and non-steroidal anti-inflammatory drugs. *Aust Prescr*. 2017;40(3):91. doi:10.18773/AUSTPRESCR.2017.037
14. Hewlett SA, Blankson P-K, Aheto JMK, et al. Assessment of oral health status in a Ghanaian population: rationale, methods, and population characteristics. *BMC Oral Heal* 2022 221. 2022;22(1):1-13. doi:10.1186/S12903-022-02090-9
15. Folayan MO, Chukwumah NM, Onyejaka N, Adeniyi AA, Olatosi OO. Appraisal of the national response to the caries epidemic in children in Nigeria. *BMC Oral Health*. 2014;14(1):1-10. doi:10.1186/1472-6831-14-76
16. Teshome A, Muche A, Girma B. Prevalence of Dental Caries and Associated Factors in East Africa, 2000–2020: Systematic Review and Meta-Analysis. *Front Public Heal*. 2021;9. doi:10.3389/FPUBH.2021.645091
17. Bali RK, Sharma P, Gaba S, Kaur A, Ghanghas P. A review of complications of odontogenic infections. *Natl J Maxillofac Surg*. 2015;6(2):136. doi:10.4103/0975-5950.183867
18. Righolt AJ, Jevdjevic M, Marcenes W, Listl S. Global-, Regional-, and Country-Level Economic Impacts of Dental Diseases in 2015. *J Dent Res*. 2018;97(5):501-507. doi:10.1177/0022034517750572

