

MARGINAL ADAPTATION AND POST-OPERATIVE SENSITIVITY IN NON-CARIOUS CERVICAL LESIONS USING A UNIVERSAL ADHESIVE IN A NIGERIAN POPULATION

***Omosebi T.O.¹, Adegbulugbe C.I.², Awotile A.O.¹, Enone L.L.¹, Adebayo G.E.³**

¹Department of Restorative Dentistry, Lagos State College of Medicine/ Lagos State University Teaching Hospital, Ikeja, Lagos-state, Nigeria

²Department of Restorative Dentistry, College of Medicine, University of Lagos/Lagos University Teaching Hospital, Idi-Araba, Lagos-State, Nigeria

³Department of Dental Services, Federal Medical Centre, Ebute-metta, Lagos-state, Nigeria

Corresponding Author: Dr. Temitope Olabisi OMOSEBI, Department of Restorative Dentistry, Lagos State College of Medicine/Lagos State University Teaching Hospital, Ikeja, Lagos-state, Nigeria

Correspondence: lopeisokay@yahoo.com

DOI: <https://dx.doi.org/10.4314/gdj.v21i1.7>

ABSTRACT

BACKGROUND: Problems such as microleakage and post-operative sensitivity may arise in the composite restoration of non-cariou cervical lesions (NCCLs). This study assessed marginal adaptation and post-operative sensitivity in restored non-cariou cervical lesions using a universal adhesive with different application techniques.

MATERIALS AND METHODS: An interventional study included sixty teeth that met the selection criteria. Total-etch and selective-etch were the two application techniques used. Marginal adaptation and post-operative sensitivity were evaluated immediately post-op as a baseline, then at 3, 6, and 12 months using FDI Criteria. Data collected was analyzed using SPSS with statistical significance at $p \leq 0.05$.

RESULTS: The majority of participants belonged to the 41-50 years age group. The NCCLs were present more in the maxillary teeth at 43(71.7%). Regarding marginal adaptation, out of the 60 restorations, seven restorations showed small marginal fractures at the 12-month period in both techniques. Restorations in the selective-etch technique group had 100% scores of 1 (no hypersensitivity) in post-operative sensitivity throughout the evaluation periods, whereas there was a score of 2 for minor hypersensitivity of restoration in the total-etch technique.

CONCLUSION: The assessment of marginal adaptation and post-operative sensitivity in restored teeth with NCCLs using a universal adhesive with selective etch and total-etch techniques showed good clinical performance over a one-year evaluation.

Key Words: Marginal adaptation, post-operative sensitivity, non-cariou cervical lesions, universal adhesives.

INTRODUCTION

The loss of tooth tissue at the neck of a tooth unrelated to tooth decay is called a non-cariou cervical lesion (NCCL).¹ NCCLs frequently affect dental structures, and their severity is associated with aging.² One of the factors determining the long-term success of restorations of these lesions is the presence or absence of gaps at the tooth-restoration interface.³ Gaps found at the interface will cause marginal leakage and may result in sensitivity and secondary caries.³

The incidence of post-operative sensitivity is more frequently reported for class V composite restorations due to the configuration factor.⁴ The higher the configuration factor, the higher the stress resulting from polymerization shrinkage, which causes the resin to pull away from the cavity wall, leaving a small gap.^{4,5} This gap permits oral fluids and bacteria ingress and is termed microleakage with resultant post-operative sensitivity.⁵

Restoration of lesions resulting from non-cariou loss of dental hard tissue at the cervical region is used as a clinical model to evaluate the efficacy of dentin bonding agents in tooth restorations, as the American Dental Association (ADA) recommended.⁶ The characteristics of NCCLs include:^{7,8} (1) cervical lesions do not provide any macro-mechanical retention; (2) they require at least 50% bonding to dentin; (3) class V restoration margins are located in enamel as well as in dentin; (4) they are highly prevalent; (5) they are usually found in the anterior teeth or premolars, thus providing good access for the restorative procedure and visibility for evaluation; (6) preparation and restoration of class-V lesions are minimal and relatively easy, reducing somewhat practitioner variability; (7) despite varying cavity configuration factors of class-V lesions, and thus resultant interfacial stress, the mechanical properties of the composite resin used are relatively unimportant; and (8) ineffective bonding

commonly results in restoration loss, which is the most objective evaluation parameter.

Some important factors affect resin bonding at the cervical region of the tooth; the orientation of the enamel rods at the cervical region is in the gingival direction with reduced bond strength^{9,10} and prismless enamel, which is commonly found at the cervical area of the teeth, making it more resistant to acid etching, thus affecting enamel bonding.^{9,11} The early use of adhesives in dentin resulted in poor bond strengths.¹² This was a result of the composition of dentin, given the fact that enamel contains 1% protein while dentin is 17% collagen by volume.¹³ This collagen is inaccessible due to surrounding hydroxy-apatite crystals.¹⁴ Moreover, non-cariou cervical lesions typically consist of sclerotic dentin, preventing maximum adhesion due to its acid-resistant nature.¹⁵ Reports have indicated that resin bond strengths to non-cariou sclerotic cervical dentin are lower than bonds made to normal dentin.¹⁶ This is thought to be due to the occlusion of tubules by mineral salts (hypermineralization), preventing resin tag formation.¹⁶

The principles of adhesive dentistry date back to 1955, when Buonocore conveyed the benefits of acid etching as a surface treatment before applying the resins.¹⁷ The adhesive systems have been revolutionized and are regularly used in operative dentistry to improve resin-based materials' retention, sealing, and aesthetics.¹⁸ One of the most recent novelties in adhesive dentistry was the introduction of universal adhesives that have been used since 2011 in clinical practice.¹⁷ These new adhesives are known as "multi-mode" or "multi-purpose" adhesives because they may be used as self-etch adhesives, etch-and-rinse adhesives, or as selective-etch adhesives.¹⁹

Universal adhesives have monomers capable of producing chemical and micromechanical bond adhesion

to the dental substrates.²⁰ One functional monomer used in contemporary dental adhesives but not in older-generation bonding agents is 10-methacryloyloxydecyl dihydrogen phosphate (MDP), which interacts chemically with hydroxyapatite (HAP) intensively and stably ('Adhesion-Decalcification' concept).^{21,22} The universal adhesives also contain other monomers, which are biphenyl dimethacrylate (BPDM), dipentaerythritol pentaacrylate phosphoric acid ester (PEN-TA)²³ and polyalkenoic acid copolymer that enhance adhesion to tooth structures.¹⁷

Treatment of NCCLs is very important because most patients present with severe hypersensitivity²⁴ caused by thermal and pH changes.¹⁵ There are challenges in restoring the NCCLs because no retentive cavity can be prepared in the tooth's cervical region. NCCLs typically consist of sclerotic dentin, which can prevent maximum adhesion due to its acid-resistant nature.^{25,26} The challenges mentioned above have brought about the evolution of bonding systems²⁷ and the use of composite resin in the restoration of NCCLs. However, a few studies have evaluated the marginal integrity and post-operative sensitivity in restoring NCCLs using universal adhesives in the West Africa sub-region. Therefore, this present study focused on assessing marginal adaptation and post-operative sensitivity in restoring non-carious cervical lesions using a universal adhesive with different application techniques.

METHODOLOGY

This was a randomized, controlled clinical study. A simple randomization using computer-generated numbers was used to categorize the selected patients into two study groups. This study was carried out in the Conservative Dentistry clinic of the Department of Restorative Dentistry, Lagos State University Teaching Hospital, Ikeja, Lagos State, a tertiary Hospital in Nigeria's South Western geopolitical zone. The selected participants were enlisted from the patients referred for the restoration of non-carious cervical lesions at the clinic. The sample size for this study was determined using a formula for clinical studies $n = \frac{(Z\alpha + Z\beta)^2 \{p_1q_1 + p_2q_2\}}{A^2}$.²⁸

The sample consisted of 30 restorations per group, totaling 60 restorations.

Patients aged 18 years and above with non-carious cervical lesions of between 1mm and 3mm depth extending beyond enamel to dentin were included in this study. However, patients with rampant uncontrolled caries, advanced untreated periodontal diseases, teeth with periapical pathology, non-vital tooth or previous root canal therapy, and evidence of severe bruxism, clenching, and temporomandibular disorder were excluded. Approval for the study was obtained from the Health Research and Ethics Committee of the Lagos State University Teaching Hospital, Ikeja. Verbal and signed informed consent were obtained from all participants after fully explaining the procedures, risks involved, benefits involved, and availability for the follow-up periods of 3 months, 6 months, and 12 months. Every participant was given opportunities to ask questions concerning the study, and appropriate clarifications were given before the commencement of the study.

Procedure

Thirty participants were selected for the study, each with 2 non-carious cervical lesions requiring restorations who had met the inclusion criteria. Thirty teeth were selected for each intervention; they were randomized using a computer-generated table of random numbers into two groups based on the application modes: total-etch group and selective-etch group. Degree of sclerosis ranging

from 1-4 and pre-operative sensitivity to a blast of air using the Schiff Cold Air Sensitivity Scale ranging from 0-3 as a standard index were recorded prior to the placement of restorations. Tooth shade selection was performed with the Vita shade guide under natural light before the restorative procedure while the teeth were moist. The teeth were treated under local anaesthesia (2% xylocaine HCL 1:80,000) as needed and isolated with a rubber dam (Uno dent®). The teeth were cleaned with pumice and a prophylaxis brush for approximately 10 seconds before treatment. In the total-etch group, both the enamel and dentin were etched for 15 seconds with 34% phosphoric acid (Scotchbond™ Phosphoric Etchant, 3 M ESPE) applied with dispensing tip, rinsed for 10 seconds and dried using gentle application of air for 2 seconds to keep the dentin moist based on the manufacturer's instructions, while this etchant gel was carefully placed only on enamel margin in selective-etch group. One coat of the universal adhesive (3M ESPE) was applied to the enamel and dentin in the two groups for 20 seconds with agitation, air dried for 5 seconds, and light cured for 10 seconds, as stated by the manufacturer. In both total-etch and selective-etch groups, Filtek supreme ultra-universal (3 M ESPE) composite resin was placed in 1.5 mm incremental depth in dentin and cured for 40 seconds, and the 1.5mm incremental depth in enamel was cured for 20 seconds according to the manufacturer's instructions using Ultra-Lite LED Curing light (Rolence®) (with output 400-1000 mW/cm²). Carbide finishing burs (7404, OS-1, OS-2, Brasseler) were used to remove gross excess, followed by polishing. Polishing was carried out with aluminium oxide polishing paste (Henry Schein®) and rubber cup (Shofu®) on a slow handpiece under irrigation immediately after placement of restorations.

Evaluation of restorations

All the restorations were evaluated at baseline, 3 months, 6 months, and 12 months for marginal adaptation and post-operative sensitivity. The clinical evaluation was done by two blinded, experienced and calibrated dentists with inter and intra-examiner reliability of 85% using the FDI clinical criteria.²⁹ Kappa score of 0.85 was taken as acceptable for all measurements. An examiner assessed the reliability test earlier for correctness and accuracy after the treatment of preliminary cases that were not included in this study. The characteristics recorded by the examiners were scored in a range of 1 to 5. Score 1- Clinically excellent/very good; Score 2- Clinically good; Score 3- Clinically sufficient/satisfactory; Score 4- Clinically unsatisfactory (but reparable); Score 5- Clinically poor (replacement necessary). The subcategory with the worst scores determined the overall rating or final score. Clinical evaluation was done using Loupes with 4x magnification (Lactona®), dental mirror, and probe. Clinical photographs of restorations were taken at each recall visit.

Data analysis

Data were entered and analyzed using the Statistical Packages for Social Sciences (SPSS, IBM) version 25.0. Categorical variables were presented using frequencies and percentages, while numeric data were presented using mean and standard deviation for normally distributed data. Charts were also used for data presentation. Association between categorical data was determined using the chi-square test and Fisher's exact test, while clinical outcome at different follow-up intervals was assessed using the McNemar test. A 5% level of significance was considered statistically significant.

RESULTS

Out of forty (40) participants of palatal obturator wearers, 16 (40%) were males, and 24 (60%) were females giving a male-to-female ratio of 2:3. The mean age of the participants was 40.50 ± 9.57 years. Most participants, 12 (30%), fell between the ages of 31 and 40. The lowest number of participants, 7 (17.5%), were in the age group of 51-60 years, as indicated in Table 1.

Table 1 also indicates the number of years participants wore their palatal obturators; it also shows their level of education and occupation.

Table 1: Socio-demographic characteristics of subjects

Age Group (years)	Male N(%)	Female N(%)	Total (100)	Statistic	p-value
<41	4 (15.1%)	1 (11.1)	5 (16.7)	1.871**	0.600
41-50	10 (47.6)	6 (66.7)	16 (53.3)		
51-60	6 (28.6)	1 (11.1)	7 (23.3)		
>60	1 (4.8)	1 (11.1)	2 (6.7)		
Total	21 (100)	9 (100)	30 (100)		

Mean±SD 48.43±8.3 45.80±6.7 47.43±7.1 -0.409* 0.685

**Fisher's exact test; *Independent student t test; SD=Standard deviation

Table 2: Distribution of restorations placed by location in the arch

	Total etch (n=30) No. (%)	Selective etch (n=30) No. (%)	Total	χ ²	p-value
Side					
Right	14 (46.7)	15 (50.0)	29 (48.3)	0.067	0.796
Left	16 (53.3)	15 (50.0)	31 (51.7)		
Jaw					
Maxilla	21 (70.0)	22 (73.3)	43 (71.7)	0.082	0.774
Mandible	9 (30.0)	8 (26.7)	17 (28.3)		

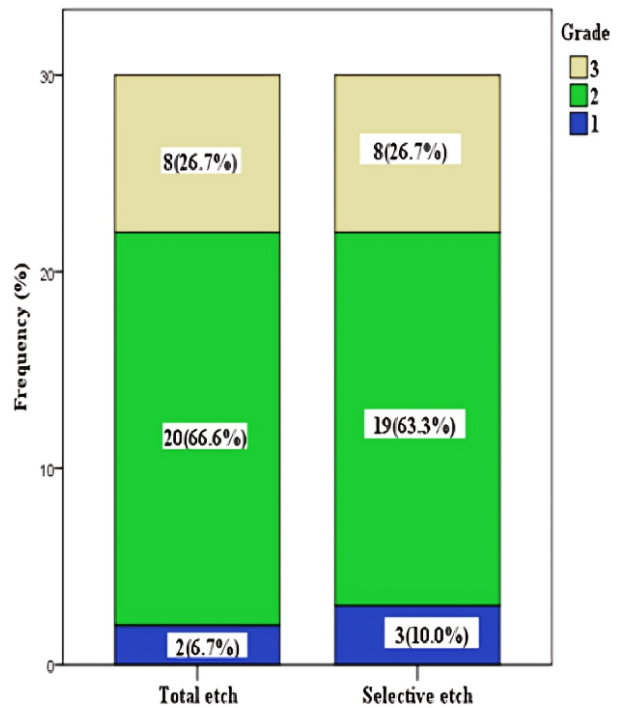


Figure 1: Simple bar chart showing the degree of sclerotic dentin in the non-carious cervical lesions

Evaluation of marginal adaptation in the restoration of NCCLs

All 30 total-etch mode restorations and 30 selective-etch mode restorations scored 1 in 100% of cases for marginal adaptation at baseline. At 3 months, 22(73.3%) restorations in the total-etch group had a score of 1, and 8(26.7%) had a score of 2, while 21(70.0%) restorations in the selective-etch group had a score of 1 and 9(30.0%) had a score of 2. At 6 months, 15(50.0%) restorations in the total-etch group had a score of 2, while 16(53.3%) restorations in the selective-etch group had a score of 2. At 12 months, 14(46.7%) restorations in the total-etch group had score of 1, 13(43.3%) had score of 2 and 3(10.0%) had score of 3, while 12(40.0%) restorations in the selective-etch group had score of 1, 14(46.7%) had score of 2 and 4(13.3%) had score of 3 (Table 3). All the restorations were clinically acceptable. Throughout the evaluation period, the difference in marginal adaptation between the two groups was not statistically significant (p>0.05).

Table 3: Evaluation of marginal adaptation in the restoration of non-carious cervical lesions using a universal adhesive in total-etch and selective-etch modes.

FDI Sc	Baseline			3 Months			6 months			12 months		
	TE N(%)	SLE N(%)	P	TE N(%)	SLE N(%)	P	TE N(%)	SLE N(%)	P	TE N(%)	SLE N(%)	P
Marginal adaptation												
1	30(100.0)	30(100.0)	1.000	22(73.3)	21(70.0)	0.774	14(46.7)	12(40.0)	0.761	14(46.7)	12(40.0)	0.846
2	0(0.0)	0(0.0)		8(26.7)	9(30.0)		15(50.0)	16(53.3)		13(43.3)	14(46.7)	
3	0(0.0)	0(0.0)		0(0.0)	0(0.0)		1(3.3)	2(6.7)		3(10.0)	4(13.3)	

****Fisher's exact test; *Independent student t test; SD=Standard deviation**

Evaluation of post-operative sensitivity in the restoration of NCCLs

Restorations in the total-etch group dropped from 100% at baseline to 96.7% at 3, 6, and 12 months in post-operative sensitivity. In the selective-etch group, the restorations had 100% scores 1 from baseline to 12 months (Table 4). All the restorations were clinically acceptable. No statistically significant difference in post-operative sensitivity was observed between the two groups throughout the evaluation period ($p>0.05$).

Table 4: Evaluation of post-operative sensitivity in the restoration of non-carious cervical lesions using a universal adhesive in total-etch and selective-etch modes.

Table 2: Distribution of restorations placed by location in the arch

FDI Sc	Baseline			3 Months			6 months			12 months		
	TE N(%)	SLE N(%)	P	TE N(%)	SLE N(%)	P	TE N(%)	SLE N(%)	P	TE N(%)	SLE N(%)	P
Post-operative sensitivity												
1	30(100.0)	30(100.0)	1.000	29(96.7)	30(100.0)	0.313	29(96.7)	30(100.0)	0.313	29(96.7)	30(100.0)	0.313
2	0(0.0)	0(0.0)		1(3.3)	0(0.0)		1(3.3)	0(0.0)		1(3.3)	0(0.0)	

Fisher's exact use, SC= Scores, TE= Total-etch, SLE= Selective etch, P = P value; significant < 0.05 Scores: 1 = clinically excellent/ very good, 2 = clinically good.

DISCUSSION

The incidence of post-operative sensitivity is frequently reported for class v composite restorations due to the configuration factor,⁴ and gaps found at the interface, which cause marginal leakage and eventual sensitivity and secondary caries,³ have been a major concern. This study focused on assessing marginal adaptation and post-operative sensitivity in restoring non-carious cervical lesions using a universal adhesive with different application techniques.

Non-carious cervical lesions were present more in the maxillary teeth than in the mandibular teeth. This is consistent with previous studies.^{30,31} This could be attributed to the fact that most patients begin their tooth cleaning from the maxillary teeth with a progressive decrease of force as the process continues.³¹ Another possible explanation is that maxillary teeth overlap the mandibular teeth; therefore, the toothbrush makes more contact with maxillary teeth while brushing.

In the case of assessed marginal adaptation, thirty-one restorations were considered to have minor discrepancies (score 2) at the 6-month recall, 15 for total-etch and 16 for selective-etch. A finding similar to the results of the current study was reported by Perdigão et al.,²⁸ who, at 6 months evaluation, found a higher percentage of score 2 in selective-etch (42%) compared to total-etch (32%). Seven restorations scored 3 at 12 months, 3 for total-etch, and 4 for selective-etch; however, the 7 restorations mentioned above were clinically satisfactory and sufficient. This study shows that marginal adaptation in the total-etch group appears better clinically based on clinical observation of the restorations than the selective-etch group. However, no statistically significant difference was identified between the two groups. On the contrary, a study by Atalay et al.,³² showed that the selective-etch group performed better than the total-etch group, recording 100% alpha scores in the selective-etch group till 18 months. However, there was no statistically significant difference between the groups. The changes in marginal adaptation in restorations over time could be attributed to biomaterial-tooth interfaces, which are exposed to chemical and mechanical degradation.³ Chemically, the degradation of the resin bond interface is caused by the absorption of water and chemicals, such as enzymes present in the saliva, into the hybrid layer, compromising the bonding

system over time, which results in marginal fractures.⁸ Another possibility associated with fracture along the marginal interface may be attributed to repeated mechanical stress during each chewing cycle.³³ At some sites, stress concentrations may exceed interfacial fracture toughness, which results in the initiation of a crack. The marginal defects recorded in this study may be attributed to repeated mechanical stress during each chewing cycle due to the high fibrous diet in our environment.³⁴

Regarding post-operative sensitivity, a 3.3% score of 2 was recorded only in the total-etch group in this study at 3, 6, and 12 months; this might be ascribed to excessive etching of the dentin layer. However, the difference between the total-etch and selective-etch groups was not statistically significant. In contrast, a similar study¹⁵ showed no post-operative sensitivity throughout the evaluation period for the total-etch group. However, in the selective-etch group, sensitivity was observed at 6 and 12 months, with no statistically significant difference between the two groups. Post-operative sensitivity has been linked to incomplete marginal seal, which might be due to chip fractures at the margin³⁵ and inadequate coating of the dentin surface with adhesives following acid etching.⁵ In addition, the incidence of post-operative sensitivity is more frequently reported for class V composite restorations due to the configuration factor.⁴ The higher the configuration factor, the higher the stress resulting from polymerization shrinkage, which causes the resin to pull away from the cavity wall, leaving a small gap.^{4,5} This gap permits oral fluids and bacteria ingress and is termed microleakage with resultant post-operative sensitivity.⁵

The good clinical performance of the restorations in the two groups regarding marginal adaptation and post-operative sensitivity might be attributed to the unique feature of Scotchbond Universal adhesive utilized in this study. The Scotchbond Universal adhesive has a unique feature; it contains the MDP and polyalkenoic-acid copolymer, capable of bonding to calcium. MDP forms nano-layers with calcium present in the hybrid layer.²² Moreover, Scotchbond Universal adhesive is more hydrophobic than earlier simplified adhesives; its hydrophobicity is derived from the molecule MDP, which is inherently hydrophobic. The universal adhesive's hydrophobic nature may also help explain its favourable comparison with total-etch material in this study and a similar study.³⁶

Etching of enamel surfaces helps to improve the performance of restorations in terms of marginal adaptation; this was carried out on both the total-etch and selective-etch groups, which gave good clinical performances in this study. Atalay et al.,³² carried out a similar study, including self-etch mode; it was reported that the self-etch mode showed less satisfying performance regarding marginal adaptation compared to total-etch and selective-etch modes. The authors noted that universal adhesive is a good choice for adhesion to dentin but possibly insufficient for enamel bonding. Using chemical bonding of MDP with hydroxyapatite at the etched enamel could significantly increase the enamel bond strength.³²

CONCLUSION

The assessment of marginal adaptation and post-operative sensitivity in restoring non-carious cervical lesions using a universal adhesive with total-etch and selective etch techniques showed good clinical performance. The etching of enamel surfaces in both

techniques helped to improve the marginal seal, allowing it to have a good marginal adaptation and preventing post-operative sensitivity. Clinicians should be encouraged to use the universal adhesives in both techniques to restore non-carious cervical lesions..

REFERENCES

- Osborne KL, Burke FJ, Wilson NH. The aetiology of the non-carious cervical lesion. *Int Dent J.* 1999; 49(3):139–143.
- Lamas-Lara C, Vásquez-Rodrigo H, Rosas-Prado C, et al. Comparison of the clinical effect of the adhesive strategies of universal adhesives in the treatment of non-carious cervical lesions. Systematic review and meta-analysis. *J Oral Res.* 2017;7(5):210–222.
- Opdam N, Roeters F, Feilzer A, et al. Marginal integrity and post-operative sensitivity in Class 2 resin composite restorations in vivo. *J Dent.* 1998; 26(7):555–562.
- Feilzer A, De Gee A, Davidson C. Setting stress in composite resin in relation to configuration of the restoration. *CL J Dent Res.* 1987;66(11):1636–1639.
- Sabbagh J, Fahd J, Mcconnell R. Post-operative sensitivity and posterior composite resin restorations: a review. *Dent Updat.* 2018; 45(3):207–213.
- American Dental Association. Acceptance program guidelines: Dentine and enamel adhesive materials. *Am Dent Assoc Counc Sci Aff.* 2001;2(1):12–16.
- Peumans M, Kanumilli P, De Munck J, et al. Clinical effectiveness of contemporary adhesives: a systematic review of current clinical trials. *Dent Mater.* 2005;21(2):864–881.
- Munck J, Landuyt K, Peumans M. A critical review of the durability of adhesion to tooth tissue. *J Dent Res.* 2005;84(2):118–132.
- Shimada Y, Tagami J. Effects of regional enamel and prism orientation on resin bonding. *Oper Dent.* 2003;28(1):20–27.
- Akpata E, Alomari Q, AlShammery A. Bonding to enamel and dentin. In: *Principles and practice of operative dentistry: a modern approach.* 2nd Edition, pp 69-82, United Kingdom; Quintessence publishing, 2013.
- Pashley DH, Tay FR. Aggressiveness of contemporary self-etching adhesives Part II: etching effects on unground enamel. *Dent Mater.* 2001;17(5):430–444.
- Liu Y, Tjäderhane L, Breschi L, et al. Limitations in bonding to dentin and experimental strategies to prevent bond degradation. *J Dent Res.* 2011;90(8):953–968.
- Kugel D, Ferrari M. The science of bonding: From first to sixth generation. *J Am Dent Assoc.* 2000;131(1):20–25.

14. Cardoso M, de Almeida N, Mine A, et al. Current aspects on bonding effectiveness and stability in adhesive dentistry. *Aust Dent J*. 2011;56(1):31–44.
15. Dilsad F, Ergin E, Cananta S. Twenty-four-month clinical performance of different universal adhesives in etch-and-rinse, selective etching and self-etch application modes in NCCL – a randomized controlled clinical trial. *J Appl Oral Sci*. 2019;27(1):1–10.
16. Tay FR, Pashley DH. Resin bonding to cervical sclerotic dentin: A review. *J Dent*. 2004;32(3):173–196.
17. Sofan E, Sofan A, Palaia G, et al. Classification review of dental adhesive systems: from the IV generation to the universal type. *Ann Stomatol (Roma)*. 2017;8(1):1–17.
18. Van Dijken J. A randomized controlled 5-year prospective study of two HEMA-free adhesives, a 1-step self etching and a 3-step etch-and-rinse, in non-carious cervical lesions. *Dent Mater*. 2013;29(11):271–280.
19. Hanabusa M, Mine A, Kuboki T, et al. Bonding effectiveness of a new ‘multi-mode’ adhesive to enamel and dentine. *J Dent*. 2012;40(6):475–484.
20. Muñoz M, Luque-Martinez I, Malaquias P, et al. In vitro longevity of bonding properties of universal adhesives to dentin. *Oper Dent*. 2015;40(3):282–292.
21. Fukegawa D, Hayakawa S, Yoshida Y, et al. Chemical interaction of phosphoric acid ester with hydroxyapatite. *J Dent Res*. 2006;85(10):941–944.
22. Yoshida Y, Yoshihara K, Nagaoka N, et al. Self-assembled Nano-layering at the Adhesive Interface. *J Dent Res*. 2012;91(4):376–381.
23. Tay FR, Pashley DH. Aggressiveness of contemporary self-etching systems. *Dent Mater*. 2001;17(4):296–308.
24. Bamise C, Adeyemi O, Oginni A. An analysis of the etiological and predisposing factors related to dentin hypersensitivity. *J Contemp Dent Pract*. 2008;9(5):1–9.
25. Yildiz M. Restoration of non-carious cervical tooth surface lesions using composite and dentin pins. *Rev Clin PesqOdontol*. 2010;6(2):193–196.
26. Venkatesan K, Kuzhanchinathan M, Prakash P. Critical review of noncarious cervical lesions. *SRM J Res Dent Sci*. 2018;9(2):74–80.
27. Buonocore M, Babu N, Joseph R. Adhesive dentistry. *J Conserv Dent*. 2005;8(3):43–46.
28. Ibrahim T. Research methodology and dissertation writing for health and allied health professionals. 1st ed. Abuja, Nigeria: Cress Global Link Limited; 2009. p. 74–75.
29. Hickel R, Peschke A, Tyas M, et al. FDI World Dental Federation: Clinical criteria for the evaluation of direct and indirect restorations-update and clinical examples. *Clin Oral Investig*. 2010;14(4):349–366.
30. Oginni AO, Olusile AO, Udoye CI. Non-carious cervical lesions in a Nigerian population: abrasion or abfraction? *Int Dent J*. 2003;53(5):275–279.
31. Afolabi AO, Shaba OP, Adegbulugbe IC. Distribution and characteristics of non- carious cervical lesions in an adult Nigerian population. *Niger Quarterly Journal Hosp Med*. 2012;22(1):1–6.
32. Atalay C, Ozgunaltay G, Yazici A. Thirty-six-month clinical evaluation of different adhesive strategies of a universal adhesive. *Clin Oral Investig*. 2020;24(4):1569–1578.
33. De Munck J. Influence of a shock absorbing layer on the fatigue resistance of a dentin-biomaterial interface. *Eur J Oral Sci*. 2005;113(1):1–6.
34. Enone L, Awotile A, Adegbulugbe C, et al. One-year clinical evaluation of nanohybrid resin composite in the restoration of occlusal and proximo-occlusal cavities in Nigeria. *Adv Hum Biol*. 2017;7(3):130.
35. Qvist V, Qvist J, Mjor I. Placement and longevity of tooth-colored restorations in Denmark. *Acta Odontol Scand*. 1990;48(5):305–311.
36. Lawson NC, Robles A, Fu C-C, et al. Two-year clinical trial of a universal adhesive in total-etch and self-etch mode in non-carious cervical lesions. *J Dent*. 2015;43(10):1229–1234.