

Caseous lymphadenitis: A case of sheep and its management in Ethiopia

Dessalew Habte

Debre Markos University, Department of Veterinary Laboratory Technology, Debre Markos, Ethiopia.

E-mail: desalewhabte@gmail.com or dessalew_habte@dmu.edu.et

Abstract

Caseous lymphadenitis (CLA) is a contagious and chronic bacterial disease of animals that affects the lymphatic system with the formation of abscesses. This case report documents a sheep diagnosed with CLA that was brought to the Veterinary Teaching Hospital of Addis Ababa University College of Veterinary Medicine and Agriculture (AAU-CVMA), Bishoftu on March 06/2022. The primary complaint was weakness, anorexia, and a slight, fluctuating, sickle-shaped, enlarged swelling in the neck region between the ear and jaws, which developed due to a laceration by a wire on the fence. Physical and clinical examination revealed increased body temperature (40.7°C) and respiratory rate (44 breaths/min) and mildly fluctuating swelling on lymph nodes. Anorexia, coughing, general ill thrift, exercise intolerance, and enlargement of subcutaneous tissues and lymph nodes around the neck region were observed. Aspiration of the swelling revealed thick, pale greenish-cheesy pus. Using the Ethiopian Differential Diagnosis and Information Environment App-based diagnosis and bacterial culture of the pus revealed the case as CLA. It was managed by surgical removal of the pus, topical wound spray, and systemic administration of fortified procaine penicillin for five days intramuscular and once topically on the site, respectively. The sheep recovered after a month. In conclusion, CLA is a challenging suppurative disease of sheep and goats that can be successfully treated by topical wound management and systemic penicillin therapy.

Keywords: Abscess; Caseous lymphadenitis; Penicillin; Sheep.

Introduction

Caseous lymphadenitis (CLA) or cheesy gland disease is caused by *Corynebacterium pseudotuberculosis*, is a significant and chronic contagious disease that potentially threatens the majority of sheep-rearing countries. This disease is characterized by the formation of widespread abscesses in lymph nodes, subcutaneous tissues, internal organs, and reproductive disorders (orchitis, abortion, and stillbirth). It occurs worldwide and is considered one of the most economically important diseases, particularly in the sheep and goat industry. That is why it's so-called the plague of small ruminant producers (Pépin and Paton, 2010; Umer *et al.*, 2017).

Caseous lymphadenitis is caused by *Corynebacterium pseudotuberculosis* (*C. pseudotuberculosis*) which is a gram-positive, pleomorphic, rod-shaped, non-sporulating, non-capsulated, non-motile, intracellular, facultative anaerobic bacterium in the family *Corynebacteriaceae*. This micro-organism also causes other diseases; external subcutaneous abscesses, ulcerative lymphangitis, and internal infection in horses (Çetinkaya *et al.*, 2002). Transmission occurs mainly through contamination of superficial wounds by contact, during common procedures (shearing, castration, and ear tagging), through contaminated environment (*C. pseudotuberculosis* is able to penetrate skin lesions and oral mucosal injuries), through injuries by other traumatic events and aerosols from animals with lymphadenitis in the lung (Osman *et al.*, 2018; Moura *et al.*, 2020).

In small ruminants, the clinical signs of CLA are primarily characterized by weight loss, poor growth, purulent nasal discharge, fever, general ill health, and the development of abscesses in peripheral and/or internal lymph nodes and organs such as the lungs, kidneys, liver, and spleen. The abscesses are caused by bacteria-induced caseation necrosis of the lymph glands. Additionally, affected animals may exhibit signs of respiratory disease, including cough, dyspnea, and tachypnea (Ribeiro *et al.*, 2013; Constable *et al.*, 2017). The diagnosis of this disease can be mainly based on the history of a wound, clinical signs, isolation of the agent from discharging abscesses, serology, PCR, and ultrasonography or radiography for internal organs. The differential diagnosis of CLA are localized tumor, abscess, hernia, oedema, and haematoma (Dercksen *et al.*, 2010; Nassar *et al.*, 2016).

CLA due to *C. pseudotuberculosis* can be treated with penicillin, tetracyclines, and cephalosporins. However, treatment with these drugs alone is generally not effective because of several factors including the protective nature of the capsule, the formation of the encapsulated abscess as well as the intercellularity of the organism. Therefore, surgical lancing or removing superficially located abscesses along with the above antibiotics is the effective way of treatment (Constable *et al.*, 2017; Alves *et al.*, 2020).

Due to the rapid spread of the disease, once introduced into a flock and those infected individuals serve, as a reservoir of infection, the control and eradication of CLA is difficult. Generally, it is agreed that the finest strategic way to control the disease is the vaccination of healthy animals, along with identification and isolation/quarantine of infected ones. The disease is highly prevalent and economically important in most sheep-producing countries like Ethiopia. It produces a negative influence on the growth, wool, meat, and milk production, skin and carcass condemnation, and reproductive efficiencies of flocks of small ruminants in which the most efficient strategy for the control and prevention remains in a matter of debate (Fikre and Abraha, 2014; Osman *et al.*, 2018; Yitagesu *et al.*, 2020). Therefore, the current case report describes the case of CLA and its treatment in a young sheep.

Description of the case

A young sheep with a body weight of 20 kg was presented to the Veterinary Teaching Hospital (VTH) of Addis Ababa University, College of Veterinary Medicine and Agriculture (AAU-CVMA), Bishoftu on March 06/2021 with the primary complaint of anorexia, weakness, weight loss and hot, slightly fluctuating, sickle-shaped and enlarged swelling between the ear and jaws around the neck region. The owner has also stated that the swollen mas has developed due to a laceration by a wire on the fence when the sheep was managed under a semi-intensive system with other animals. Physical examination revealed that the sheep has a body temperature of 40.7 °C, respiratory rate of 44 breaths/minute, heart rate of 88 beats/minute, and hot and thick (mildly fluctuating) swelling externally between parotid and mandibular lymph nodes while during palpation involvement of retropharyngeal or other associated lymph nodes were felt.

During clinical examination, the sheep displayed symptoms such as loss of appetite, coughing, general ill health, purulent nasal discharge, fever, and increased respiratory rate. Additionally, there was enlargement of subcutaneous tissues and lymph nodes around the neck region, and a hot, fluctuating, sickle-shaped, and enlarged swelling (Figure 1) was observed. Aspiration of this swollen mass with a sterile 20-gauge needle and syringe revealed thick, pale green, watery to cheesy pus, which confirmed the presence of a pus-filled cyst around the neck region. The EDDIE App-based diagnosis revealed the case as CLA and its treatment options. Therefore, based on the history of a wound, characteristic clinical signs, and EDDIE App-based diagnosis result, the case was tentatively diagnosed as CLA, which is differentially diagnosed with localized tumor (lymphoma), abscess oedema, and haematoma.



Figure 1. Picture of the sheep affected by caseous lymphadenitis (A) and after therapy (B).

Laboratory investigation and its findings

A fresh sample was collected from the swollen mass with a sterile needle with a syringe and placed into a screw-capped bottle containing 3ml of tryptone soya broth and immediately transported to AAU-CVMA laboratory, Bishoftu and enriched overnight by placing it inside the microbial incubator at 37 °C. The next day, some of the enriched samples were inoculated on a blood agar base supplemented with 7% sheep blood and incubated at 37 °C for 48 hours. After these hours, the sparse growth of small, white to grayish (cream-like) and waxy colonies surrounded by a weak zone of *hemolysis* (Figure 2A) characteristic of *Corynebacterium* species, the etiologic agent of CLA was observed.

From the grown colonies on blood agar, a loop full of the pure colony was taken and a smear was made for gram staining, which provides small, short, gram-positive, pleomorphic (angular, palisade arrangement), looking like rod-shaped (Figure 2B below) were observed. Generally, the history of the wound due to laceration, clinical signs, EDDIE App-based diagnosis, and laboratory results showed to conclude that the disease affecting the sheep was finally confirmed as caseous lymphadenitis.

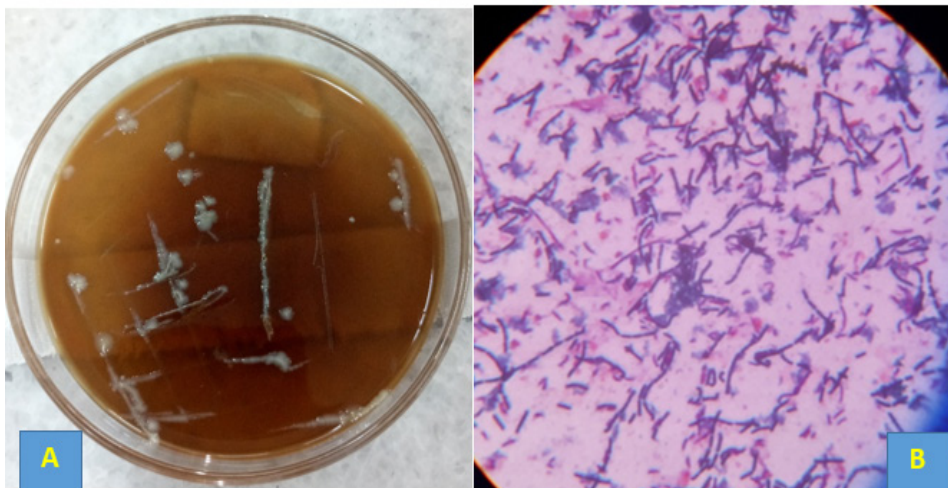


Figure 2. Laboratory results of caseous lymphadenitis suspected sheep (A, growth of *C. pseudotuberculosis* on blood agar and B, result of gram stain of colonies from blood agar).

Case management and treatment outcome

After confirmation of the disease affecting the sheep as CLA, the management and treatment approaches used were surgical draining of the abscess by the following procedures; the hair around the swollen area was clipped and shaved, followed by cleaning with clean water and savlone, then lidocaine HCL 2% was locally infiltrated around the swelling to avoid pain during manipulation. Then the abscess was surgically lanced out and flushed with diluted iodine solution followed by application of fortified procaine penicillin for five days intramuscular and into the cavity topically once stat where the pus content was removed. Subsequently, external chlortetracycline (*cyclo*) spray (Farvet Laboratories B.V., Netherlands) was applied for three days.

Finally, an intramuscular injection of 4,000,000 IU/10ml fortified procaine penicillin (North China Pharmaceutical Co. Ltd., Shijiazhuang China) at the recommended dose of 22, 000 IUs/ kg body weight for five days stat was applied. Because of the contagious nature of the disease, all materials used to treat this animal were appropriately disinfected and the drained purulent material was also carefully collected and disposed of by burning. The owner was advised to isolate this sheep from other animals by cleaning and disinfecting its bedding until the lesion stops draining and heals. Finally, the sheep were reported to be recovered from this disease after a month and sold to another owner.

Discussion

Caseous lymphadenitis (CLA) is a transmissible, chronically insidious, and serious disease of small ruminants caused by *Corynebacterium* species (Galvão *et al.*, 2017; Osman *et al.*, 2018) which is in line with the cause of the present case report.

CLA can occur as an outbreak in a population of small ruminant farms involving flocks or as a single case (Colom-Cadena *et al.*, 2014) an Iberian ibex (*Capra pyrenaica hispanica*). This is in agreement with the presented case that a single sheep was infected from four. It is not a notifiable disease in many countries, since the actual prevalence in small ruminants is usually underestimated and animal owners are not aware of its economic impacts. The morbidity rate can usually range up to 15%, and morbid animals will often eventually succumb to the disease (Osman *et al.*, 2015). Correspondingly, studies that were carried out in different parts of Ethiopia have shown that CLA is a widespread disease, especially in sheep (Fikre and Abraha, 2014; Abebe and Sisay, 2015; Yitagesu *et al.*, 2020; Osman *et al.*, 2015).

The hallmark clinical finding in cases of CLA is the development of an external abscess in the location of marginal lymph nodes. Common sites of development include behind the ears, beneath the jaw or neck, on the shoulders, or in the rear flank region and the involved lymph nodes that include parotid, submandibular, prescapular, and prefemoral lymph nodes (Ribeiro *et al.*, 2013). Caseous lymphadenitis abscesses are characteristically thick-walled. Soft pasty white to green exudate filled these abscesses when they are fresh, but the typical onion-like appearance of rings of thick dry pus is displayed in older abscesses (Constable *et al.*, 2017). Other clinical signs which include

loss of appetite, coughing, general ill thrift, purulent nasal discharge, fever, increased respiratory rate, and exercise-intolerant can also be displayed in addition to enlargement of the lymph nodes and subcutaneous tissue that contain pus (Osman *et al.*, 2015; Abba *et al.*, 2017; Reshma *et al.*, 2017). This agrees with the clinical signs of the current case report.

The diagnosis of CLA disease can be mainly based on the history of a wound, clinical signs, isolation of the agent from discharging abscesses by microbiological techniques, and other advanced laboratory techniques (Jabar *et al.*, 2016; Dercksen *et al.*, 2010). This is in line with the diagnostic approaches followed in the current case report that discharging abscess was collected in and cultured on the blood agar followed by primary and secondary bacteriological tests.

The best approach in the management and treatment of CLA is surgical lancing and draining of the pus from the enlarged lymph nodes and subcutaneous tissues and lavage with dilute iodine solution followed by the use of antibiotics topically and parentally. In addition to proper management of the case, strict biosecurity measures, elimination of diseased animals from the flock, vaccination, disinfection of shearing materials used for production procedures, and removal of hazards in the environment that injure the skin can prevent and reduce the disease (Colom-Cadena *et al.*, 2014; Abba *et al.*, 2017). Thus, the diagnostic, management for removal of the pus along with antibiotic therapy for inhibition of secondary complications and the methods used for the control and prevention of CLA in the current case report were in line with the approaches of the above authors.

Conclusions

This case report showed that CLA is a challenging suppurative disease of sheep that can be treated by topical wound spray, systemic therapy with fortified procaine penicillin, and surgical management by drainage. As a preventive measure, there is a vaccine available for use in sheep in other countries. Generally, because CLA is a chronic infection, efforts should be focused on preventing the spread to uninfected animals. However, if a suspected animal is presented, palpation of the affected area and laboratory bacterial examination usually work for the identification of the disease. Animals with visible CLA abscesses should be isolated until the abscesses get completely healed. Usu-

ally, it is recommended to work in close collaboration with a nearby veterinarian or animal health worker to develop an on-farm disease control and testing plan. In addition, when farmers purchase used sheep handling equipment, it is advised to disinfect appropriately to prevent the introduction of CLA from outside farms. Regular disinfection of farms that may become spoiled by abscess material is highly recommended. Close follow-up and separation of new farm additions for a considerable time is also one of the preventive measures to reduce the risk of entry of CLA infection. Drinking raw milk is a potential source of human infection, especially in immunosuppressed individuals.

References

- Abba, Y., Adamu, L. and Bitrus, A., 2017. Clinical case of caseous lymphadenitis in a goat: Case management. *Malays J. Vet. Res.*, 8(1), 31–35.
- Abd, A., Tawab, E., Rizk, A., Affi, S. and Mohamed, S., 2020. *Corynebacterium Pseudotuberculosis* infection in small ruminant and molecular study of virulence and resistance genes in Beni-Suef governorate. *BVMJ*, 37, 122–127.
- Abebe, D. and Sisay, T., 2015. Determination of *Corynebacterium pseudotuberculosis* prevalence and antimicrobial susceptibility pattern of isolates from lymph nodes of sheep and goats at an organic export abattoir, Modjo, Ethiopia. *Lett. Appl. Microbiol.*, 61(5), 469–476.
- Alves, J., Farias, A. and Anjos, D., 2020. Seroepidemiological study of caseous lymphadenitis in sheep from the Northeast region of Brazil using an indirect ELISA. *Trop. Anim. Health Prod.*, 52 (14), 1945-1952.
- Çetinkaya, B., Karahan, M., Atil, E., Kalin, R., Baere, T. and Vaneechoutte, M., 2002. Identification of *Corynebacterium pseudotuberculosis* isolates from sheep and goats by PCR. *Vet. Microbiol.*, 88(1), 75–83.
- Colom-Cadena, A., Velarde, R., Salinas, J., Borge, C., Serrano, E. and Gassó, D., 2014. Management of a caseous lymphadenitis outbreak in a new Iberian ibex (*Capra pyrenaica*) stock reservoir, *Acta Vet. Scand.*, 56, 83.
- Constable, P., Hinchcliff, K., Done, S. and Grundberg, W., 2017. *Veterinary Medicine: A Textbook of the Diseases of Cattle, Horses, Sheep, Pigs, and Goats*, eleventh edition, UK: *Elsevier*. Pp716-842.
- Dercksen, P., Brinkhof, M., Dekker, T., Maanen, K., Baird, G. and Kamp, E., 2010. A comparison of four serological tests for the diagnosis of caseous lymphadenitis in sheep and goats. *Vet. Microbiol.*, 75, 167-175.

- Fikre, Z. and Abraha, G., 2014. Caseous lymphadenitis in goats from Borena range land South Ethiopia slaughtered at Luna Export Abattoir. *JVMAH*, 6(6), 168–173.
- Galvão, C., Fragoso, S., Oliveira, C., Ribeiro, R., Pereira, B. and Soares, C., 2017. Identification of new *Corynebacterium pseudotuberculosis* antigens by immunoscreening of gene expression library. *BMC Microbiol.*, 17(202), 1–8.
- Jeber, Z., MohdJin, Z., Jesse, F., Saharee, A., Sabri, J., Yusoff, R. *et al.*, 2016. Influence of *Corynebacterium pseudotuberculosis* infection on level of acute phase proteins in goats, *BMC Vet. Res.*, 12(1), 1–5.
- Moura, G., Lelis, N., Oliveira, I., Bezerra, J., Calabuig, C., Martins, P., *et al.*, 2020. Seroprevalence of *Corynebacterium pseudotuberculosis* and *Toxoplasma gondii* in sheep in semi-arid region of ceará state. *Cienc. Rural*, 50(9), 1–8.
- Nassar, A., Daniel, G., Ruiz, R., Miyashiro, S., Scannapieco, M., Souza, J. *et al.*, 2016. Diagnostic comparison of *Corynebacterium pseudotuberculosis* through microbiological culture and PCR in sheep samples. *Arq. Inst. Biol.*, 82 (8), 1–6.
- Osman, A., Lim, E. and Abba, Y., 2015. Caseous lymphadenitis in a goat: A case report. *Int. J. Livest. Res.*, 5(3), 128–132.
- Osman, A., Nordin, M., Kadir, A. and Saharee, A., 2018. The epidemiology and pathophysiology of caseous lymphadenitis: A review. *J. Vet. Med. Res.*, 5(3), 1129.
- Pépin, M. and Paton, M., 2010. Caseous lymphadenitis in sheep and goats, In *Infectious and Parasitic Diseases of Livestock*, first edition, Paris, France. pp. 1153-1165.
- Reshma, P.S., Ambily, R., Hubli, S., Nair, S.S., Ramankutty, S., Kumar, V. *et al.*, 2017. Isolation and molecular detection of *Corynebacterium pseudotuberculosis* from a case of umbilical abscess in a kid. *Int. J. Sci. Environ. Tech.*, 6(5), 2827–2832.
- Ribeiro, D., Dorella, K., Fernanda, L., Gust, P., Castro, T., Portela, W., *et al.*, 2013. Sub-clinical diagnosis of caseous lymphadenitis based on ELISA in sheep from Brazil. *J. Bacteriol. Parasitol.*, 4(3), 1–4.
- Umer, M., Yusuf, P., Firdaus J., Baiee, F., Umar Hambali, I. and Sharif, A., 2017. Caseous lymphadenitis in small ruminants: An overview on reproductive implications. *Int. J. Vet. Sci. Anim. Husb.*, 2(2), 23–31.
- Yitagesu, E., Alemnew, E., Olani, A., Asfaw, T. and Demis, C., 2020. Survival analysis of clinical cases of caseous lymphadenitis of goats in North Shoa, Ethiopia. *Vet. Med. Int.*, 2020, 1-8.