

## Case Report

### Herpes Simplex Virus-1 Herpetic Meningoencephalitis in Adults: Three Cases in Casablanca, Morocco

Kamena Mwana-yile Hassan<sup>1</sup>, Hanane Badi<sup>1</sup>, Houda Lahrichi<sup>2</sup>, Ouiame El Fadel<sup>1</sup>, Latifa Marih<sup>1</sup>, Moustapha Sodqi<sup>2</sup>, Abdellaoui Soussi<sup>1</sup>, Kamal Marhoum El Filali<sup>1</sup>

<sup>1</sup> Infectious Diseases Department, Ibn Rochd University Hospital, Faculty of Medicine and Pharmacy of Casablanca, HASSAN II University, Morocco

<sup>2</sup> Laboratory of Bacteriology and Virology, Ibn Rochd University Hospital, Faculty of Medicine and Pharmacy of Casablanca, HASSAN II University, Morocco

Corresponding authors\*: docteurmwanayile@gmail.com

#### Abstract:

*Herpes simplex virus type 1 is the first cause of acute focal encephalitis with necrosis of the cerebral parenchyma in children and adults, with high morbidity. Herpes simplex virus type 2 is the main cause of herpetic meningitis in adults, with a good evolution. Herpetic meningoencephalitis is rarely caused by HSV-1. We report three observations of PCR-confirmed HSV-1 meningoencephalitis in cerebrospinal fluid in young immunocompetent adults aged 27, 53, and 58. They presented with a meningoencephalitis picture consisting of a meningeal syndrome and encephalic involvement. Lumbar puncture confirmed lymphocytic clear-fluid meningitis, with a median white blood cell count of 97, red blood cell count of 69, proteinorachia of 0.78, and glycorachia of 0.62. Cerebral magnetic resonance imaging is the gold-standard neuroimaging technique in the management of herpetic meningoencephalitis. Early initiation of acyclovir has contributed significantly to improved patient outcomes and prognosis. Herpetic meningoencephalitis is a diagnostic and therapeutic emergency, with a very poor functional prognosis, particularly in terms of complications.*

**Keywords:** Meningitis, Encephalitis, Herpes simplex virus-1, Morocco

**Citation :** Hassan KM, Badi H, Lahrichi H, et al Herpes simplex virus-1 herpetic meningoencephalitis in adults: 3 cases in Casablanca, Morocco. *Ethiop Med J* 62 (2) 127-132

**Submission date :** 20 June 2023 Accepted: 29 March 2023 Published: 1 April 2024

#### Introduction

Herpes simplex viruses 1 (HSV-1) and 2 (HSV-2) are the main causes of central nervous system infections, with very different frequencies and severities [1-3]. HSV-1 is the main cause of herpetic encephalitis, accounting for 5% to 15% of encephalitis in children under 5 years of age following initial infection, and in adults over 50 years of age following reactivation, with high morbidity and mortality in excess of 70%, and a worldwide incidence of 2-6 cases/million inhabitants/year [1,2]. HSV-2 is the main cause of benign and sometimes recurrent genital herpes meningitis in adult females, with a worldwide incidence of 7 cases/million population/year [3]. The main clinical manifestations of HSV-1 herpetic encephalitis are encephalopathy, fever, convulsions, headache and focal neurological deficits [4]. Herpetic meningoencephalitis is rarely caused by HSV-1. We report three observations of PCR-confirmed HSV-1 meningoencephalitis in cerebrospinal fluid in young immuno-

competent adults admitted to the Infectious Diseases Department of Ibn Rochd University Hospital in Casablanca.

#### Observations

##### Case 1

Mr. TA, aged 53, with a history of seizures in 2003, was admitted on July 22, 2022, to the Infectious Diseases Department at Ibn Rochd University Hospital for a meningeal syndrome consisting of headache in the form of a helmet, resistant to analgesics, emesis and an infectious syndrome consisting of fever and a syndrome of encephalitis, including disturbed consciousness (Glasgow 12/15) and combativeness, which had been progressing for three days. Neurological examination revealed a stiff neck and positive Kernig's and Brudzinski's signs. A cerebral computed tomography (CT) scan revealed no abnormalities, complemented by a cerebral magnetic resonance imaging (MRI) scan

showing bilateral limbic signal abnormalities and an electroencephalogram showing foci of middle temporal slowing. Lumbar puncture identified clear-fluid meningitis with 20 white blood cells/mm<sup>3</sup> (80% lymphocytes) and 35 red blood cells/mm<sup>3</sup>, hyperproteinorachia at 0.75 g/L and normoglycorachia at 0.66 g/L (R = 70%). HIV-1 and -2 serologies and lupus work-up were negative. Treatment was initiated with acyclovir 15 mg/Kg/day every 8 hours (750 mg in 3 infusions), third-generation cephalosporin 100 mg/Kg/day (3 g in 2 infusions), and an antiepileptic (1 tablet in two doses). HIV-1 and -2 serology and lupus

work-up were negative. PCR-Herpes simplex virus-1 in the cerebrospinal fluid (CSF) came back positive after three days, and only the antiviral treatment was maintained. Ganciclovir replaced acyclovir, following a stock shortage, on the ward at a dose of 10 mg/kg, equivalent to 400 mg in two infusions. The patient progressed well after 21 days of treatment, with no sequelae.

The results of CSF cytochemical tests are presented in tabular form (Table I)

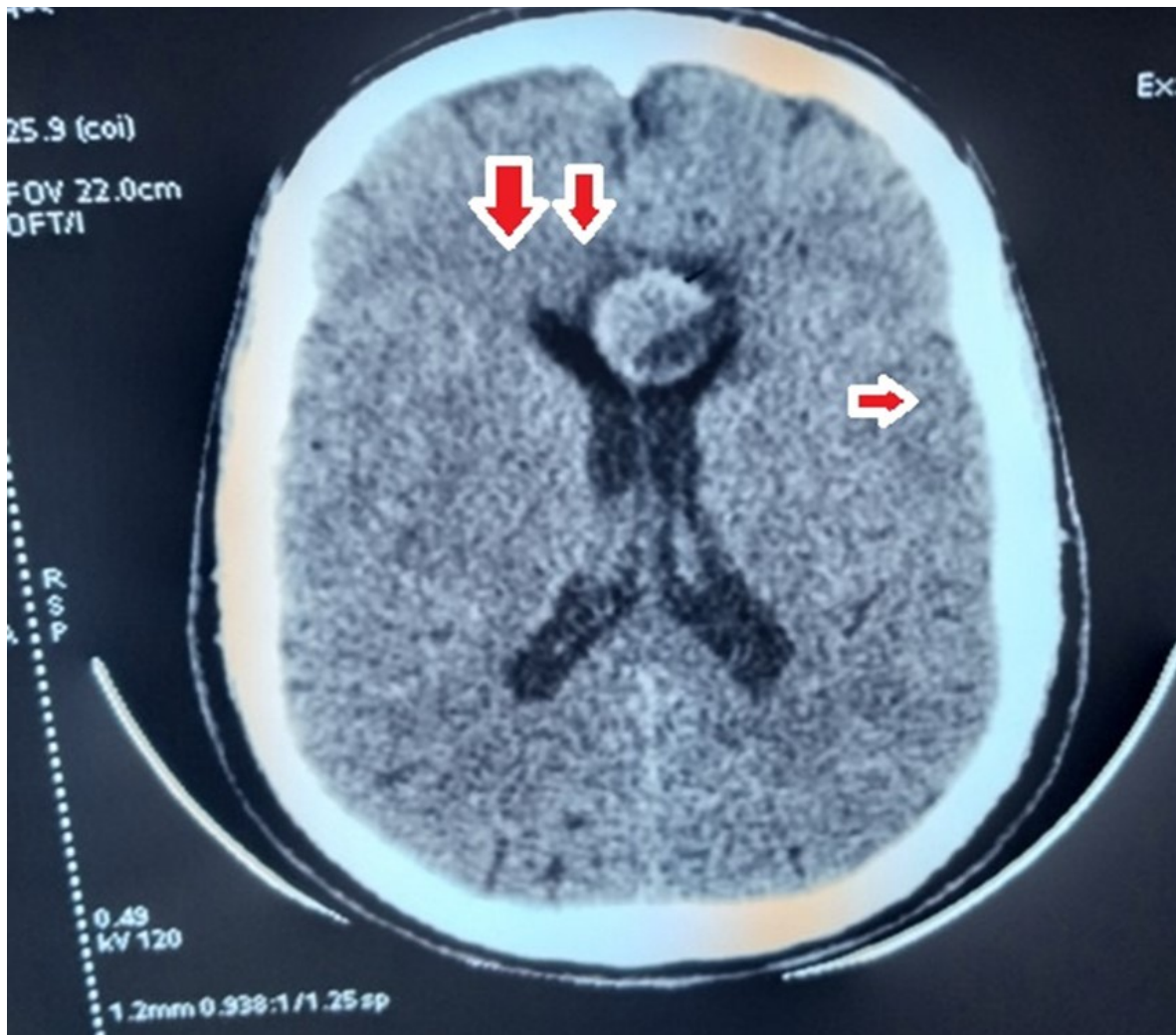
**Table I:** Cytochemical examination of cerebrospinal fluid of patients

Observation	Aspect	Cytology examination	Bacteriologic examination	Proteinorachia	Glycorachia
Case 1	Clear	20 WBC (80% L) 35 RBC	DE – Sterile culture	0,75 g/L	0,66 g/L
Case 2	Clear	30 WBC (100% L) 20 RBC	DE – Sterile culture	1,08 g/L	0,59 g/L
Case 3	Clear	20 WBC (90% L) 73 RBC	DE – Sterile culture	0,70 g/L	0,61 g/L

### Case 2

Mr DA, aged 58, a chronic smoker (22 packs/year) for 30 years, was admitted on August 28, 2022 to the infectious diseases department of Ibn Rochd University Hospital Rochd with a meningeal syndrome consisting of headache resistant to analgesics, emesis, infectious syndrome with fever and encephalitis syndrome, including disturbed consciousness (Glasgow 13/15) and hallucination-type behavioral disturbance, which had been progressing for eight days before admission. Neurological examination revealed a stiff neck and positive Kernig's and Brudzinski's signs. A cerebral CT scan revealed areas of non-systematized hypodensity in the temporal and insular regions (Figure 1), complemented by a cerebral MRI scan showing a gyriform hypersignal on T2, Flair, and diffusion sequences, with a drop in the apparent diffusion coefficient in the frontal and right parietal regions, as well as bilaterally in the insular region (Figure 2). Lumbar puncture revealed clear-fluid meningitis with 70 white blood cells/mm<sup>3</sup> (100% lymphocytes) and 10 red blood cells/mm<sup>3</sup>, hyperproteinorachia at 0.89 g/L and normoglycorachia at 0.60 g/L (R = 52%). HIV-1 and 2 serologies and lupus work-up were negative. Treatment was initiated with acyclovir 15 mg/Kg/day every 8 hours (750 mg in 3 infusions) and third-generation cephalosporin 100 mg/Kg/day (3 g in 2 infusions). As CSF PCR for herpes simplex virus-1 was positive, only antiviral treat-

ment was continued. As disorders of consciousness and behavior persisted one week after treatment, a follow-up lumbar puncture was performed, revealing a clear-fluid meningitis with 30 white blood cells/mm<sup>3</sup> (100% lymphocytes) and 20 red blood cells/mm<sup>3</sup>, a hyperproteinorachia at 1.08 g/L and a normoglycorachia at 0.59 g/L (R = 54%) After three weeks of treatment, the patient's hallucinations persisted and a second lumbar puncture revealed minus 3 white blood cells/mm<sup>3</sup>, hyperproteinorachia at 1.07 g/L and normoglycorachia at 0.71 g/L. The patient was transferred to neurology for additional management of the hallucinations.

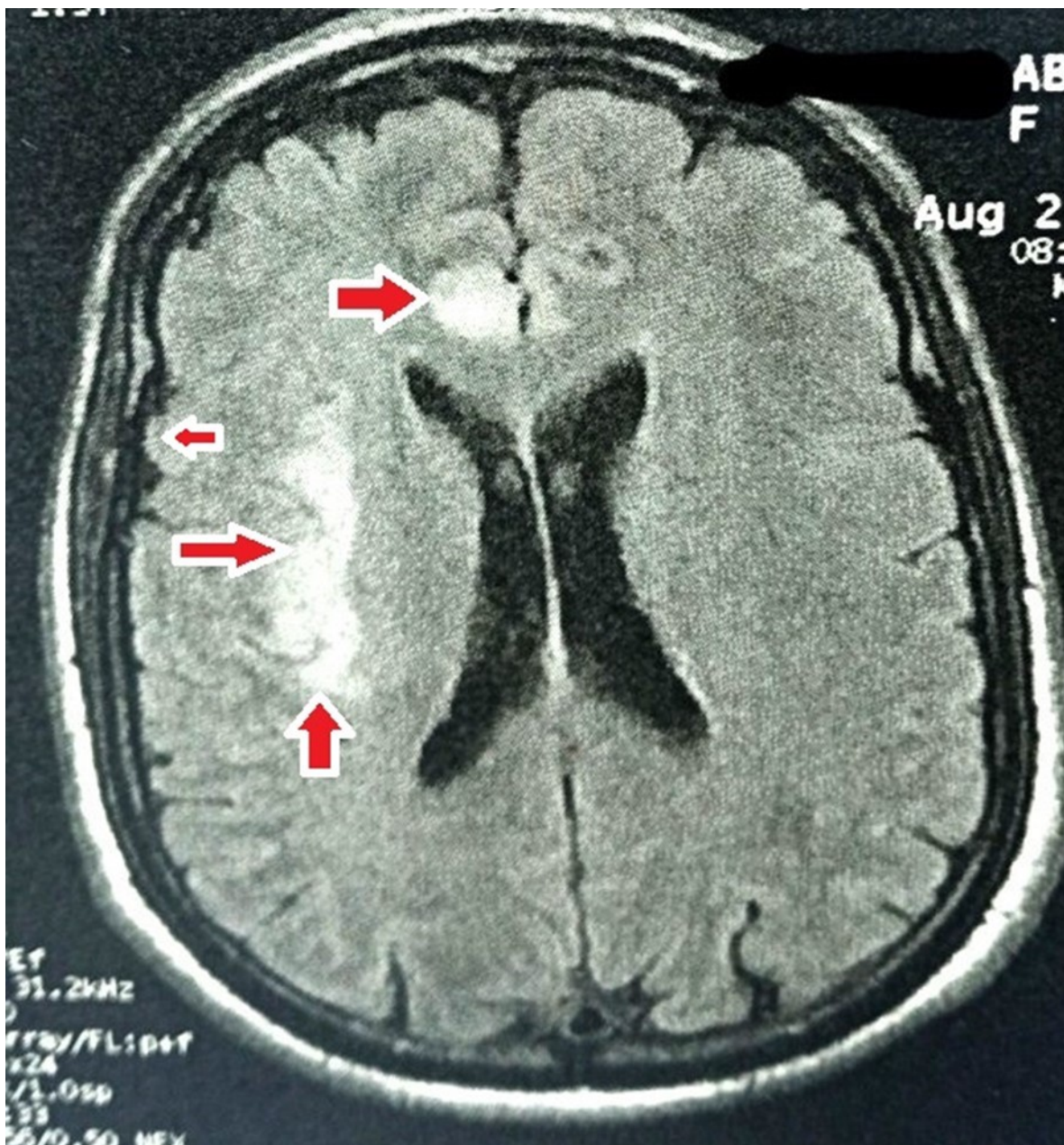


**Figure 1:** Areas of temporal and insular hypodensity

### Case 3

Mr AB, aged 27, with no particular pathological history, was admitted on October 07, 2022, to the Infectious Diseases Department of CHU Ibn Rochd for a meningeal syndrome consisting of headache that was resistant to analgesics, vomiting and an infectious syndrome consisting of fever with no figures, and an encephalitis syndrome with disturbed consciousness (Glasgow score 13/15), and hallucinations, which had been progressing for ten days. A cerebral CT scan showed a small intra-parenchymal hematoma of external capsular origin, and a lumbar puncture revealed clear-fluid meningitis with 20 white blood cells/mm<sup>3</sup> (90% lymphocytes) and 73 red blood cells/mm<sup>3</sup>, hyperproteinorachia at 0.70 g/L and normoglycorachia at 0.61 g/L (R = 65%). HIV-1 and -2 serology and lupus work-up were negative. Treatment was initiated with acyclovir 15 mg/Kg/day every 8 hours (750 mg

in 3 infusions), third-generation cephalosporin 100 mg/Kg/day (3 g in 2 infusions), anticonvulsant Gardenal 100 mg (one tablet in two doses) and neuroleptic Haldol 5 drops in three doses. CSF Herpes simplex virus-1 PCR was positive after three days, and only antiviral treatment was maintained. On the 8th day of treatment, we observed hepatic cytolysis (AST: 321 UI/L and ALT: 422 UI/L), for which antiviral treatment was stopped and resumed after six days, i.e., the duration of antiviral treatment was 22 days. After three weeks of treatment, the patient showed no memory impairment and persistent visual hallucinations. A cerebral MRI scan was completed, showing a gyriform hypersignal on T2 sequences in the temporal and insula bilateral regions. The patient was transferred to the neurology department for management of the sequelae.



**Figure 2:** gyriform hypersignal on T2, Flair, and diffusion sequences with reduced apparent diffusion coefficient in right frontal and parietal areas and bilateral insular areas.

### Discussion

Herpetic encephalitis affects all age groups, but is more common and more severe in children and the elderly [5]. Some 33% of patients are under 20 years of age, and 50% are over 50 [6]. In our study, the first two patients were over 50 years of age, one of them 27.

HSV-2 is the main cause of herpetic meningitis, either as a primary infection or as a reactivation (recurrence) of a dormant virus in the central nervous system (CNS) [7]. It is related to genital herpes and is

frequent in adults, particularly women [3].

To replicate once in the central nervous system (CNS), the virus can either reside in a quiescent latent state in this tissue or eventually actively lead to severe acute necrotizing encephalitis, which is characterized by aggravated neuroinflammation and prolonged neuro-immune activation producing a potentially fatal disease [9].

Cytochemical examination of the cerebrospinal fluid shows hyperproteinorachia, normoglycorachia, and a predominantly lymphocytic pleocytosis, pointing to a

## Discussion

Herpetic encephalitis affects all age groups, but is more common and more severe in children and the elderly [5]. Some 33% of patients are under 20 years of age, and 50% are over 50 [6]. In our study, the first two patients were over 50 years of age, one of them 27.

HSV-2 is the main cause of herpetic meningitis, either as a primary infection or as a reactivation (recurrence) of a dormant virus in the central nervous system (CNS) [7]. It is related to genital herpes and is frequent in adults, particularly women [3].

To replicate once in the central nervous system (CNS), the virus can either reside in a quiescent latent state in this tissue or eventually actively lead to severe acute necrotizing encephalitis, which is characterized by aggravated neuroinflammation and prolonged neuro-immune activation producing a potentially fatal disease [9].

Cytochemical examination of the cerebrospinal fluid shows hyperproteinorachia, normoglycorachia, and a predominantly lymphocytic pleocytosis, pointing to a diagnosis of meningoencephalitis when the clinical picture is favorable (febrile neurological symptoms [9])

Cerebral computed tomography in the setting of herpetic meningoencephalitis is normal [9], but in our case series, it helped orient the diagnosis by showing areas of temporal and insular hypodensity

Magnetic resonance imaging (MRI) of the brain is the reference radiological examination, showing T2 hypersignals in the temporal lobes (present in 90% of cases) and the cingulate gyrus. The confirmatory test for herpetic meningoencephalitis is the polymerase chain reaction (PCR) in CSF, with a sensitivity of 98%, a specificity of 94%, a positive predictive value of 95%, and a negative predictive value of 98% [9]. Early initiation of acyclovir has been shown to improve outcome and prognosis in patients with proven

herpetic meningoencephalitis [10]. In cases of acyclovir-related renal failure or acyclovir rupture, ganciclovir also makes a significant contribution to the management of herpetic meningoencephalitis [11].

As bacterial meningoencephalitis can often not be ruled out on clinical grounds, and septic encephalopathy is a common mimic of herpetic encephalopathy [12], the addition of broad-spectrum antibiotics is recommended until bacterial infection can be ruled out. This approach is supported by recent UK guidelines for the empirical management of encephalitis [13].

Immunodeficient patients were less likely to present prodromal symptoms or focal neurological deficits, and it was not uncommon to observe an absence of pleocytosis in the CSF. Morbidity and mortality were significantly higher in the immunodeficient group, with 35.7% mortality versus 6.7% in the immunocompetent group [14].

## Conclusion

Herpetic meningoencephalitis is a rare clinical manifestation of HSV-1 infection, with a good prognosis if antiviral treatment is initiated early.

## Conflict of interest

The authors declare no conflict of interest.

## Authors' role

- KH: Design, writing, and literature reviews
- HI: Design and Literature Reviews
- OF, SA: Bacteriology and Virology Laboratory
- HL: literature reviews
- LM, MS and KM EF: Scientific supervision

## Consent of the family member

We obtained the consent of patients' families for the writing and presentation of the case series. Radiographic Images were de-identified.

## References

1. Rozenberg F. Herpes simplex virus and central nervous system infections: encephalitis, meningitis, myelitis. *Virologie (Montrouge)*.2020 Oct 1;24(5):283-294. doi : 10.1684/vir.2020.0862
2. Richard J Whitley. Herpes simplex encephalitis : adolescents and adults. *Antiviral Res.* 2006 Sep ;71(2-3) : 141-8.doi : 10.1016/j.antiviral.2006.04.002
3. Jakobsen A, Skov MT, Larsen L, Trier Petersen P, Brandt C, Wiese L et al. Herpes Simplex Virus 2 Meningitis in Adults : A Prospective, Nationwide, Population-Based Cohort Study. *Clin Infect Dis.* 2022 Sep 14 ;75 (5) :753-760. doi : 10.1093/cid/ciab1071
4. Singh TD, Fugate JE, Hocker S, Wijdicks EF, Aksamit AJ, Jr., Rabinstein AA. Predictors of outcome in HSV encephalitis. *J Neurol* 2016 ;263 :277-289
5. Behzad-Behbahani A, Abdolvahab A, Gholamali YP, Roshanak B, Mahmood R. Clinical signs as a guide for performing HSVPCR in correct diagnosis of herpes simplex virus encephalitis. *Neurol India* 2003; 51:341-344.

6. Schroth G, Gawehn J, Thron A, Vallbracht A, Voigt K. Early diagnosis of herpes simplex encephalitis by MRI. *Neurology* 1987;37:179-183.
7. Bennett JE, Dolin R, Blaser MJ. Mandell, Douglas, and Bennett's principles and practice of infectious diseases. 8th ed. Philadelphia, PA: Elsevier Health Sciences, 2014
8. Douglas R, Wilcox, Richard Longnecker. The Herpes Simplex Virus Neurovirulence Factor  $\gamma$ 34.5: Revealing Virus-Host Interactions. *PLoS Pathog.* 2016 Mar 10;12(3):e1005449. doi: 10.1371/journal.ppat.1005449. eCollection 2016 Mar
9. [Luisa F Duarte](#), [Mónica A Fariás](#), [Diana M Álvarez](#), [Susan M Bueno](#), [Claudia A Riedel](#), [Pablo A González](#). Herpes Simplex Virus Type 1 Infection of the Central Nervous System: Insights Into Proposed Interrelationships With Neurodegenerative Disorders. *Front Cell Neurosci.* 2019 Feb 26;13:46. doi: 10.3389/fncel.2019.00046
10. Scheld WM, Whitley RJ, Marra CM. Infections of the central nervous system. 4th ed. Philadelphia: Wolters Kluwer Health; 2014. 907
11. Hjalmarsson A, Blomqvist P, Skoldenberg B. Herpes simplex encephalitis in Sweden, 1990-2001: incidence, morbidity, and mortality. *Clin Infect Dis* 2007;45:875-880.
12. Laure Blanc A, El Mansouf L, Lemaire X. First case of herpetic meningoencephalitis treated with ganciclovir. *J Chemother.* 2017 Oct;29(5):308-309
13. Riancho J, Delgado-Alvarado M, Sedano MJ, Polo JM, Berciano J. Herpes simplex encephalitis: clinical presentation, neurological sequelae and new prognostic factors. Ten years of experience. *Neurol Sci* 2013;34:1879-1881
14. Tan IL, McArthur JC, Venkatesan A, Nath A. Atypical manifestations and poor outcome of herpes simplex encephalitis in the immunocompromised. *Neurology* 2012;79:2125-2132