

CASE REPORT**A RARE CASE OF HEPATIC SUBCAPSULAR HEMATOMA PRESENTING WITH SEVERE ANEMIA IN A 20-HOUR OLD TERM NEWBORN: CASE REPORT**Gashaw Arega^{1*}, Asrat Demtse¹, Yosef Belayhun¹, Fathia Oumer²¹Addis Ababa University, , Department of Pediatrics and Child Health, Addis Ababa,²Addis Ababa University, Department of Radiology, Addis Ababa,*Corresponding author: gashawarega@gmail.com**Abstract**

Hepatic subcapsular hematoma is an extremely rare clinical condition in the neonatal period. Being a life-threatening emergency, it requires prompt diagnosis and management. In a newborn presented with severe anemia, hypovolemic shock, and abdominal distention with hemoperitoneum without any identifiable risk factors hepatic subcapsular hematoma should be considered. Newborns may develop catastrophic acute and long-term complications if the diagnosis is not made timely. Obstetricians, pediatricians, neonatologists and pediatric surgeons should have a high of the index of suspicion of hepatic subcapsular hematoma in newborns to avoid delay in the diagnosis and to reduce neonatal morbidity and mortality.

Here, we report a 20 hour's old male term newborn diagnosed with Hepatic Subcapsular Hematoma after he presented with progressive abdominal distension and severe anemia. Abdominal ultrasound showed a well-defined round heterogenic echogenic liver mass and massive intra-peritoneal fluid collection. The newborn was managed in the Neonatal Intensive Care Unit with Fresh Frozen Plasma transfusion, Whole blood transfusion and vitamin K administration, and discharged improved after a week. A high index of clinical suspicion is necessary to avoid delayed diagnosis and life-threatening complications among health professionals in the neonatal intensive care unit.

Keywords: Newborn, Hepatic Subcapsular Hematoma, NICU, Severe Anemia, APGAR score**Case presentation**

The case was a 20-hour-old male term newborn, born to 29 years old para II mother at 40 weeks of gestational age. The mother had a regular Antenatal Care (ANC) follow-up with unremarkable baseline investigations and her

blood group was O+. The pregnancy was uneventful and no fetal abnormalities were detected on prenatal obstetric ultrasound evaluation and follow-up. The mother had no known medical illness during pregnancy or before pregnancy.

Citation : Arega G, Demtse A., Belayhun Y., Oumer F.. H. A Rare Case of Hepatic Subcapsular Hematoma presenting with Severe Anemia in a 20-Hour Old Term Newborn: case report. *Ethiop J Pediatr Child Health*. 2022;17 (2):146-151

Submission date: 23 September 2022 **Accepted:** 29 October 2022 **Published:** 28 December 2022

The labor started spontaneously and lasted for 04 hours with intrapartum rupture of the membrane. The delivery was via spontaneous vertex delivery, to effect an alive male newborn weighing 3200 grams with an APGAR score of 8 and 9 at the first and 5th minutes respectively. Routine newborn care was given and the newborn was put on the mother's side and sucking well. At the age of 20 hours, the newborn has begun to develop progressive abdominal swelling with pallor. Laboratory examination showed severe neonatal anemia and the newborn was referred to our Neonatal Intensive Care Unit for better investigations and treatment.

Physical examination during admission to our NICU showed an acutely sick-looking newborn with a heart rate was 165 beats per minute, a respiratory rate of 60 breaths per minute, a saturation of oxygen 90 % with atmospheric air and a temperature of 36.6 degrees centigrade.

The newborn had paper white conjunctivae, a distended abdomen with positive shifting dullness and fluid thrill, palmar pallor involving the palmar crease and lethargy on nervous system examination with bilaterally reactive pupils.

Neonatal reflex examination revealed depressed moro reflex, un-sustained suckling

reflex and weak grasp reflex. Up on admission the newborn was managed with intranasal oxygen support, resuscitated with bolus normal saline, transfused with whole blood, antibiotics with ampicillin and cefotaxime initiated with a consideration of early onset neonatal sepsis and vitamin k was administered.

Complete blood count panel showed a white blood count of 14,700 with 58% of neutrophils, hemoglobin of 4.6 g/dl with a hematocrit of 16.4 and mean corpuscular volume of 90fl, platelet count was 154,000 and the blood group was O+. Serum electrolytes, coagulation profile, renal function test and bilirubin total and direct were normal. Liver function test showed ALT-183, AST-123, ALP-125. B-HCG and alpha fetoproteins were determined and showed a value of 1.04 and 76,000ng/ml respectively. Trans-frontal ultrasound was normal.

Greyscale abdominal ultrasound showed ill-defined mixed hypo-echoic and anechoic liver lesion measuring liver mass measuring 5.6cm by 4.7 cm with massive intra peritoneal fluid collection [Figure 1]. In the color Doppler study, there was no significant flow demonstrated.

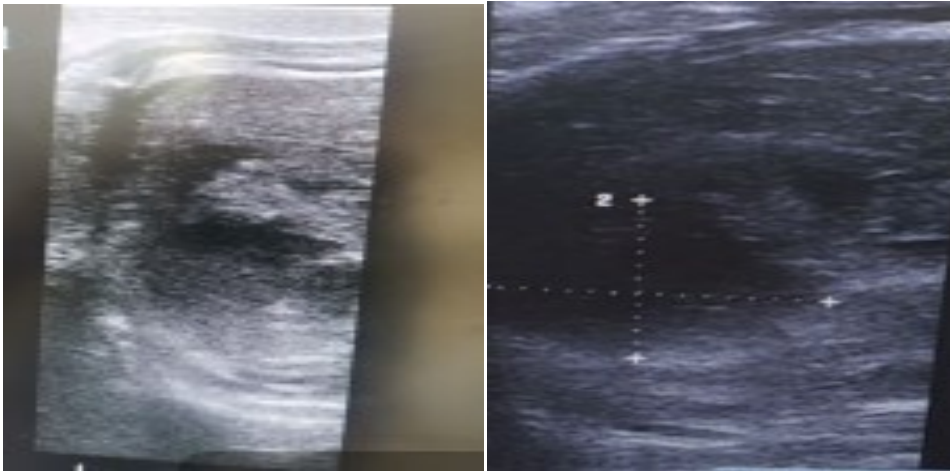


Figure 1- Abdominal ultrasound images showing ill-defined mixed hypo echoic and anechoic liver lesion.

Pre-contrast axial abdominal CT at hepatic level, demonstrated poorly defined mixed heterogeneous lesion at right posterior segment and Post contrast axial, sagittal and coronal

CT scan at hepatic level, demonstrating hypo enhancing sub capsular lesion with mild heterogeneity and mass effect. [Figure 2A, 2B].

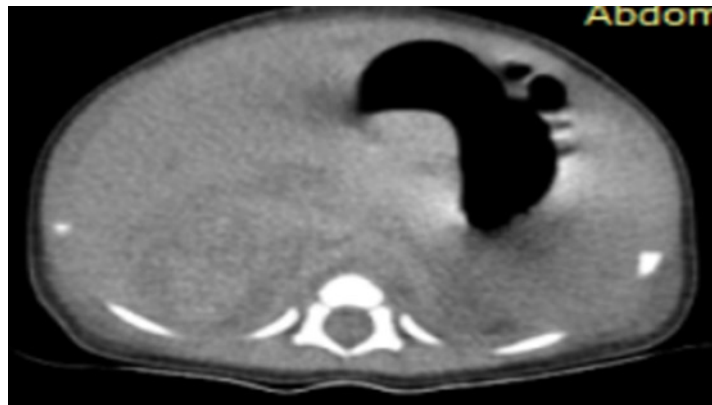
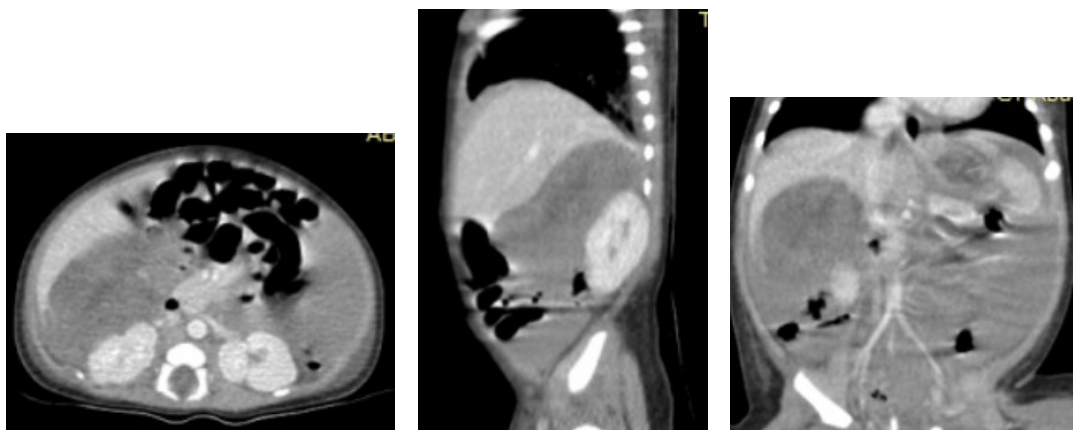


Figure 2A- Pre-contrast axial abdominal CT at hepatic level showing poorly defined mixed heterogeneous lesion at right posterior segment.



2B- Post-contrast axial, sagittal and coronal CT scan at hepatic level, demonstrating hypo enhancing sub-capsular lesion with mild heterogeneity and mass effect.

Based on the presentation, physical findings, laboratory, and imaging findings hepatic subcapsular hematoma with severe anemia was made. The newborn condition improved with supportive medical management and serial abdominal ultrasound showed significant improvement in the free fluid collection and a decrease in the size of the liver collection. The abdominal girth decreases progressively and the newborn was discharged with follow-up arranged at high-risk infant clinic. The infant is now 6 months old and subsequent abdominal ultrasounds were unremarkable.

Case discussion

Hepatic subcapsular hematoma is an extremely rare clinical entity in the early newborn period. As it is an uncommon clinical condition infrequently experienced in the newborn practice the diagnosis is usually missed or delayed [1]. Coagulopathies, hypoxia, sepsis, pneumothorax, maternal diseases, placental lesions, and trauma can be the predisposing factors for liver subcapsular hematoma [2].

Hepatic Subcapsular Hematoma in newborns is more common in newborns born with breech presentation and is more common in preterm newborns. And it should be suspected clinically in newborns presented with unexplained hypovolemic shock and neonatal anemia [3].

The non-specific signs and symptoms of hepatic subcapsular hematoma may be progressed and lead to the development of sudden circulatory collapse when the accumulated hematoma in the liver ruptures through the

hepatic capsule and blood enters the peritoneal cavity forming hemoperitoneum [3]. The newborn may present with clinical signs of anemia and abdominal distention with signs of peritoneal fluid collection. Abdominal ultrasound helps to establish the diagnosis. As hepatic hematoma in the newborn is most often subcapsular in location, an abdominal ultrasound scan can demonstrate parenchymal hemorrhage appearing hyperechogenic or it may appear cystic with a hyperechogenic part. In newborns diagnosed with hepatic subcapsular hematoma conservative medical therapy is the mainstay of treatment with oxygen support, blood product transfusion, correction of coagulopathies, addressing the risk factors and avoiding excessive handling of the baby. Surgical interventions should be considered for newborns who fail to respond to conservative medical therapy to improve the outcomes of the newborn with ruptured hepatic subcapsular hematoma [4,5,6].

In our case, the initial symptoms and signs were non-specific. The newborn was acutely sick-looking and tachycardic. Physical examinations showed paper white conjunctivae, abdominal distention with signs of fluid collection, palmar pallor and depressed neonatal reflex. Complete blood count panel showed severe neonatal anemia with a hemoglobin of 4.6g/dl and hematocrit of 16.4 %. Abdominal ultrasound showed subcapsular location ill-defined mixed hypoechoic and anechoic liver lesion. The diagnosis of hepatic subcapsular hematoma with severe anemia was made.

The newborn was managed with intranasal oxygen support, resuscitated with bolus normal saline, transfused with whole blood, antibiotics with ampicillin and cefotaxime initiated with a consideration of early-onset neonatal sepsis and vitamin k was administered. On subsequent days the newborn condition got improved with supportive conservative management and serial abdominal ultrasound showed significant improvement in the free fluid collection and decrease in the size of the liver collection. And the newborn discharged improved.

In conclusions, hepatic subcapsular hematoma is an extremely rare clinical entity in newborn period. In a neonate presented with severe neonatal anemia, hypovolemic shock and abdominal distention with hemoperitoneum without any identifiable risk factors hepatic subcapsular hematoma should be considered. Conservative management is the mainstay of treatment in newborn with hepatic subcapsular hematoma and a high index of clinical suspicion is required among health professionals working in the neonatal intensive care unit to avoid catastrophic acute and long-term complications.

Ethical Clearance

Informed consent for publication was obtained from the parents and ethical clearance was obtained from Addis Ababa University institutional review board.

Funding

Nil

Conflict of Interest

Nil

Authors' Contribution

The authors confirm contribution to the paper as follows: study conception, write-up and editing the manuscript: GA; data collection, drafting and analysis of the study: YB; Study conception, imaging write-up and revising the manuscript: FO; study design, drafting the manuscript: AD. All authors reviewed the manuscript and approved the final version of the manuscript.

References

1. Maliyackel Aiyappanpillai Anjay, Chaniyil Krishnan Sasidharan, Parameswaran Anoop, Hepatic Subcapsular Hematoma: Two Neonates With Disparate Presentations, *Pediatrics & Neonatology*, Volume 53, Issue 2, 2012, Pages 144-146, ISSN 1875-9572, <https://doi.org/10.1016/j.pedneo.2012.01.013>.
2. Singer DB, Neave C, Oyer CE, Pinar H. Hepatic subcapsular hematomas in fetuses and neonatal infants. *Pediatr Dev Pathol*. 1999 May-Jun;2(3):215-20. doi: 10.1007/s100249900116. PMID: 10191344.
3. Gonçalves C, Aguilar S, Prior AR, Oliveira G. Hepatic subcapsular haematoma in a premature newborn. *BMJ Case Rep*. 2013 Jun 3;2013:bcr2013009074. doi: 10.1136/bcr-2013-009074. PMID: 23737575; PMCID: PMC3702791
4. Ryan A, Finer NN. Subcapsular hematoma of the liver in infants of very low birth weight. *CAMJ* 1987;2013:1265-9

5. French C, Waldstein G. Subcapsular hemorrhage of the liver in the newborn. *Pediatrics* 1982;2013:204e8.
6. Moon S, Lee T, Yoon H. A case of delayed hemorrhage of a subcapsular liver hematoma in a neonate. *Korean J Pediatr* 2008;2013:89–92