

CASE REPORT

LEECH INFESTATION: THE UNUSUAL CAUSE OF UPPER AIRWAY OBSTRUCTION

Demeke Mekonnen

ABSTRACT

This paper presents a case of a 7 year-old child who presented with a 14-days history of blood stained saliva and shortness of breath of 3 days with signs of upper airway obstruction. Laryngoscopy revealed a blackish living foreign body in the proximal trachea. Under general anesthesia the leech was removed by applying forceps. I conclude that a high index of suspicion of leech infestation is required when faced with a child presenting with unexplained bleeding per mouth and signs of upper airway obstruction.

KEY WORDS: *Leech, Foreign body, Trachea, upper airway obstruction.*

INTRODUCTION

The leech is a hemophagic parasite, living on occasional meals of blood obtained by attaching to fish, amphibians, and mammals. Infestation occurs by drinking infested water from quiet streams, pools and springs. They attach to their hosts and remain there. Leech bodies are composed of 34 segments. Externally, leeches tend to have a brown and red striped design on an olive colored background. These organisms have two suckers, one at each end, called the anterior and posterior sucker. The posterior is mainly used for leverage while the anterior sucker, consisting of the jaw and teeth, is where the feeding takes place (1). Leech saliva contains a number of compounds which assist in its feeding. An anesthetic limits the sensations felt by the host (and thus reduces the chance of the host trying to detach the leech). A vasodilator causes the blood vessels near the leech to become dilated, and thus provides the leech with a better supply bleeding as much as 150 ml of blood for up to 48 hours. Leech saliva contains a complex protein called hirudin, which is a highly effective anticoagulant. The leech needs this to prevent blood clots which would block its feeding (1).

Leech infestation may cause serious complications like lethal dyspnoea, haemoptysis or haematemesis. A leech has been found in the nose, post-nasal space and oropharynx, but rarely in the hypopharynx or larynx. A few cases of leech in the hypopharynx or larynx have been reported in the literature during the past years (2). This case report here is intended to give clue for considering leech as a cause of unexplained upper airway obstruction with bleeding per mouth.

CASE REPORT

A 7-year-old child who came from Dedo was admitted to Jimma University Specialized Hospital Department of Pediatrics and Child health on May 29, 2012 with the history of blood stained saliva of 14 days duration and shortness of breath of 3 days duration. There was no history of trauma, foreign body ingestion, throat pain, fever, dysphagia and drug intake. He has no malena, haematuria, epistaxis or ecchymotic spots on the body. He had no such complaints in the past. He has spring water contact near the vicinity (called 'Darto spring' in Dedo woreda Bortolla kebele, South West Ethiopia) which is not protected and is used for both animals and humans.

Department of Pediatrics and Child Health, College of Public Health and Medical Sciences, Jimma University

Correspondent: Demeke Mekonnen Email: demeke.mekonnen@ju.edu.et or demekekem@yahoo.com

There is leech in the spring and it affects the cattle and they use traditional medicines made from mixing of tobacco leaves and flax seed ('telba'). But there was no similar illness to children in the surrounding. They had tried to give the child this traditional medicine though there was no improvement rather he started to have worsening of bleeding and three days prior to presentation he started to have shortness of breath and stridor. His growth and development is comparable with his peers.

Examination revealed a child with respiratory distress (stridor, intercostals and subcostal retraction) but chest is clear to auscultation and resonant to percussion, normal oral cavity but oropharynx having strikes of blood posteriorly. His nasal airways were patent without any evidence of epistaxis. There was no other abnormal clinical examination finding other than some pallor and slightly pale conjunctiva.

He was investigated with assessment of Upper airway obstruction secondary to foreign body, plus anemia and bleeding dyscrasia. with CBC, ESR, U/A, S/E, Coagulation profile and X-ray of the chest & neck (PA and Lateral). Plain radiograph of the lateral neck view reveals increase in the prevertebral soft tissues and subglottic narrowing but chest x-ray was found to be normal. His hemoglobin was 9.8 g/dL, total leukocyte count $8.6 \times 10^9/L$ with neutrophils 60%, lymphocytes 29.2% and erythrocyte sedimentation rate was 28mm at the end of first hour. Bleeding time, prothrombin time and activated partial thromboplastin time were normal while platelet count was $385 \times 10^9 /L$. His stool was negative for blood.

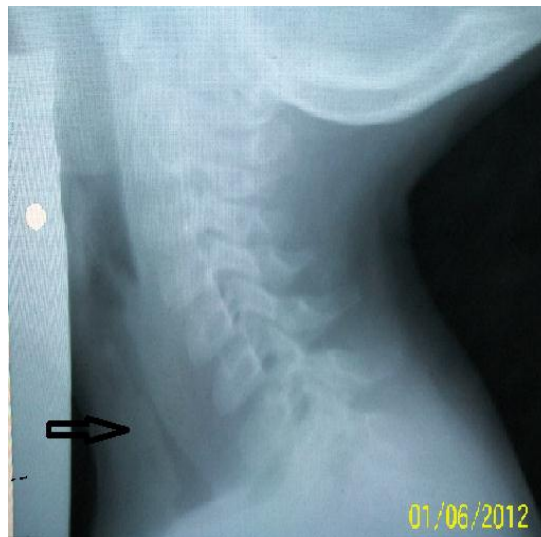


Fig. 1. Lateral neck X-ray view of the patient showing subglottic narrowing and soft tissue opacity.

The child then was taken to the Operating Theater and under general anesthesia laryngoscopy was done and it was found that the upper part of the leech was seen at the level of upper trachea first it looks like a blood clot then it was having movement and forceps was applied to takeout alive leech which measures 6cm. The child then was transferred to the ward with stable vital sign and no active bleeding or sign of respiratory distress. He was observed for 24 hours for development of sign of respiratory distress or any other complication. There was no problem identified then with advice given on the safe water use and discharged home.



Fig. 2 The leech removed from the patient, JUSH, May 2012.

DISCUSSION

Leech is a common name for over 650 species of carnivorous, blood sucking annelid worms that make up the class Hirudinea of Phylum Annelida. They are equipped with a large and small sucker. The mouth is located on the small sucker and has three jaws with sharp teeth that make a Y-shaped incision in the flesh. The leech can ingest an amount of blood approaching 10 times their own weight and may not require feeding for up to one year after their last meal. This occurs after biting the host; a process that is pain free due to a local anesthetic in the leech's saliva(1).

Leeches do not carry diseases, but can cause death in extreme cases. They enter the body either by drinking water or through the openings of persons who bath in infected water. This can be associated with inadequate and unsafe water supply in the locality therefore almost all cases have been reported from less-developed countries where access to and use of safe water is often a problem, especially in rural areas (9-13). So far, very few cases have been reported from Europe (7, 8). When ingested through the mouth in drinking water, they attach themselves to the linings of the nose or throat. Suffocation is a common cause of death for domestic animals. External wounds from leeches are less dangerous, but they may cause a secondary infection (1).

Leech endoparasitism, although rare, may cause serious, even lethal complications (3). Lethal dyspnoea, haemoptysis or haematemesis can be the revealing symptoms with further development of anemia. Mohammad et al. reported a case of a 6-year-old child who presented suffocating at the emergency room after having been diagnosed and treated for asthma over one month period (4). The child had drunk leech infested water in a rural area. Surgical removal of the leech resulted in resolution of the symptoms. Other four patients who inhaled leeches and developed severe attacks of inspiratory stridor, difficulty in breathing and spitting of blood were presented by Kaygusuz (5). All were diagnosed by indirect laryngoscopy. The leeches were removed with forceps. A case report by Solomon described a case of acute laryngotracheal obstruction in a 12-year-old boy (6).

In general a patient having a leech in the oral cavity presents with spitting of blood and a feeling

of a foreign body. A leech in the hypopharynx causes bleeding, leading to spitting of blood or haematemesis and that lying in the larynx gives rise to airway obstruction and change of voice. Diagnosis may be made by indirect laryngoscopy or fibreoptic examination. Soft tissue radiograph of the neck may reveal a foreign body but is not specific for the leech. Examination under general anesthesia (direct laryngoscopy) is essential and performed as an emergency for diagnosis and removal of the leech. The application of traditional medications may lead to dislodging of the leech deeper and may result in suffocation to death. From the case seen here we can conclude that the possibility of leech endoparasitism should be considered as a cause of unexplained bleeding from the throat in areas where aquatic leeches are commonly found, particularly when there is a history of recent contact with streams or springs. It is also wise to avoid application of traditional medications since there is a risk of dislodging to major airways leading to suffocation and death.

REFERENCES

1. Adam R, Zakrzewski P. Therapeutic use of leeches. *University of Toronto Medical Journal* 2001; 79(1): 65-67.
2. Labadi MH, Jamal MN. Leeches in the larynx. *J Laryngol Otol* 1997; 111: 980-1.
3. Bilgen C, Karci B, Uluoz U. A nasopharyngeal mass: leech in the nasopharynx. *Int J Pediatr Otorhinolaryngol* 2002; 64: 73-6.
4. Mohammad Y, Rostum M, Dubaybo BA. Laryngeal hirudiniasis: an usual cause of airway obstruction and hemoptysis. *Pediatr Pulmonol* 2002; 33: 224-6.
5. Kaygusuz I, Yalcin S, Keles E. Leeches in the larynx. *Eur Arch Otorhinolaryngol* 2001; 258: 455-7.
6. Solomon E. Leech: an unusual cause of (laryngotracheal) obstruction. *Ethiop Med J* 1991; 29: 141-2.
7. Auw-Haedrich C, Keim A, Kist M. Conjunctival infestation of a child with *Theromyzon tessulatum*. *Br J Ophthalmol* 1998; 82: 1093-1094.
8. Castillo Salinas F, Herranz Perez B, Ferrer Comalat A, Canals Riazuelo J. Unusual

- parasitic infestation by leeches in a child. *An Esp Pediatr* 1991; 35: 269.
9. Bilgen C, Karci B, Uluoz U. A nasopharyngeal mass: leech in the nasopharynx. *Int J Pediatr Otorhinolaryngol* 2002; 64: 73–76.
 10. Cundall DB, Whitehead SM, Hechtel FO Severe anaemia and death due to the pharyngeal leech *Myxobdella africana*. *Trans R Soc Trop Med Hyg* 1986; 80: 940–944.
 11. Estambale BB, Knight R, Chung R Haematemesis and severe anaemia due to a pharyngeal leech (*Myxobdella africana*) in a Kenyan child: a case report. *Trans R Soc Trop Med Hyg* 1992; 86: 458.
 12. Lepage P, Serufulira A, Bossuyt M Severe anaemia due to leech in the vagina. *Ann Trop Paediatr* 1981; 1: 189–190.
 13. O’Dempsey TJ Tails of the unexpectored: experiences with leech infestation in childhood. *Ann Trop Paediatr* 1987; 7: 252–254.