

CASE REPORT

NON SYNDROMIC OLIGODONTIA: CASE REPORT

Pradeep Tangade^{1*}, Manu Batra²

ABSTRACT

Oligodontia is a rare genetic disorder which represents the congenital absence of more than six teeth in primary, permanent or both dentitions. It is usually a part of a syndrome and seldom occurs as an isolated entity. Genes responsible for non syndromic oligodontia are found to be MSX1 and PAX9 genes. In this case report a 13 year old boy is presented who had absence of all four second permanent molars and permanent mandibular incisors. The maxillary central incisors presented with conical shape. During physical examination, there was no abnormality in either hairs or nails, perspiration was normal and no congenital clefts of lip or palate was seen. Hence in this case, Oligodontia is not associated with any syndrome which is a rare finding.

INTRODUCTION

Missing of one or more teeth congenitally is most often seen during dental examination. Absence of all teeth is quite rare but commonest forms are hypodontia and Oligodontia. The condition is genetic in origin. Hypodontia involves the absence of 1 to 6 teeth whereas Oligodontia describes condition in which more than six teeth are missing (1).

In previous studies, it was seen that more than 80% of hypodontia present with one or two congenitally missing teeth and only less than 1% will present with six or more. The incidence of oligodontia usually varies from 0.08% to 0.16%. It is a rare condition and the occurrence is common in girls in the ratio of 3:2 (2).

Oligodontia can occur in association with various genetic syndromes, like ectodermal dysplasia, Van Der Woude syndrome, Down syndrome and Reiger syndrome or as a nonsyndromic isolated familial trait, or as an infrequent finding. Oligodontia is often related with conical shaped teeth, microdontia, delayed

eruption of permanent teeth, an increased freeway space and retention of deciduous teeth. Syndromic and non syndromic form of Oligodontia can be differentiated by conducting thorough physical examination of hairs, nails, sweat glands, eyes and to check for any congenital disorders.

CASE REPORT

A 13 year old boy reported to the Department for a routine dental check-up. His past medical history was non-contributory and family history revealed that he was born to non-consanguineous marriage with normal delivery and no one in his family have congenitally missing teeth. The patient had no history of trauma or extractions. Extra oral examination revealed a face with normal facial profile and normal skeletal dental base relations (fig 1). During clinical examination, maxillary central incisors were conical in shape along with bilateral peg shaped maxillary lateral incisors. The deciduous right mandibular central incisor and maxillary canines, first and second molars were retained and permanent mandibular incisors were

^{1,2}Department of Public Health Dentistry, Kothiwal Dental College & Research Centre, Kanth Road, Moradabad-244001, Uttar Pradesh, India

*Corresponding author: Dr. Pradeep Tangade, Professor & Head of Department, Department Of Public Health Dentistry, Kothiwal Dental College & Research Centre, Kanth Road, Moradabad-244001, Uttar Pradesh, India. Email: ptangade@rediffmail.com

missing. Radiographically, in Orthopantomogram (OPG) all four permanent second molars and

permanent mandibular central and lateral incisors were missing (fig 2).

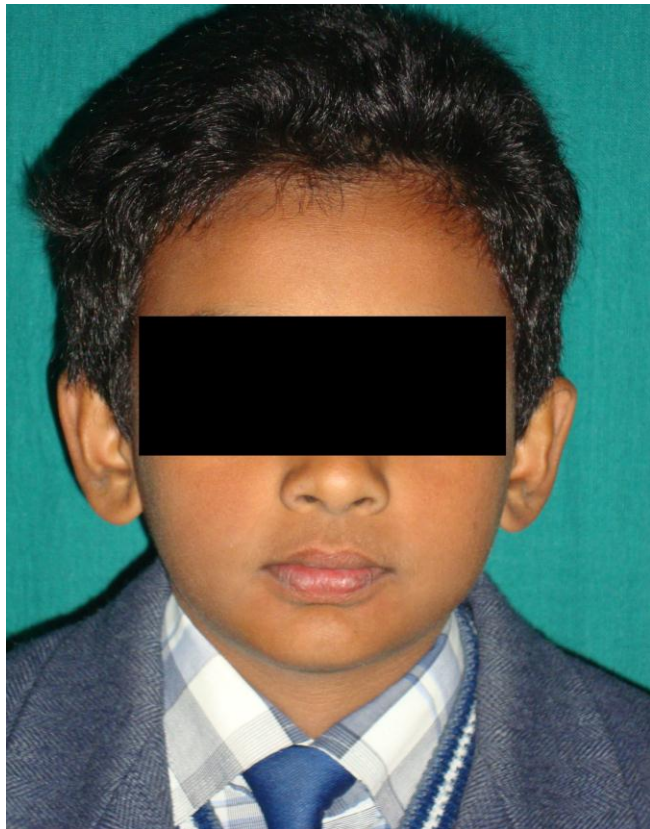

Figure 1: Clinical photograph of the subject

A provisional diagnosis of non syndromic oligodontia was given with differential diagnosis of Ectodermal Dysplasia; Rieger syndrome and Van der Woude syndrome.

Complete set of investigations were done which included routine examination of blood including serum calcium, alkaline phosphate, TSH, T3, T4. The findings of these investigations were normal. During physical examination, hairs were not thin and sparse, nails were not brittle and no difficulty in perspiration was seen which ruled out ectodermal dysplasia; on ocular examination, no signs of glaucoma was seen ruling out Rieger syndrome and lastly Van Der Woude syndrome was left out as there was cleft palate or any mucosal cysts in lower lip. Hand wrist radiographic examination was normal. Finally based on above findings non syndromic Oligodontia as final diagnosis was justified.

The treatment plan considered for the patient included reshaping conical maxillary teeth, followed by the extraction of all the retained deciduous teeth present in both maxillary and mandibular arches. After healing of extraction sites, removable partial denture will be considered for aesthetic and functional rehabilitation of the patient.

DISCUSSION

Oligodontia is the term used most commonly in describing the phenomenon of congenitally missing teeth. Oligodontia has been classified as isolated or non-syndromic and syndromic hypodontia (3). Although oligodontia can occur over with 60 different syndromes, these anomalies can occur without any syndrome or systemic

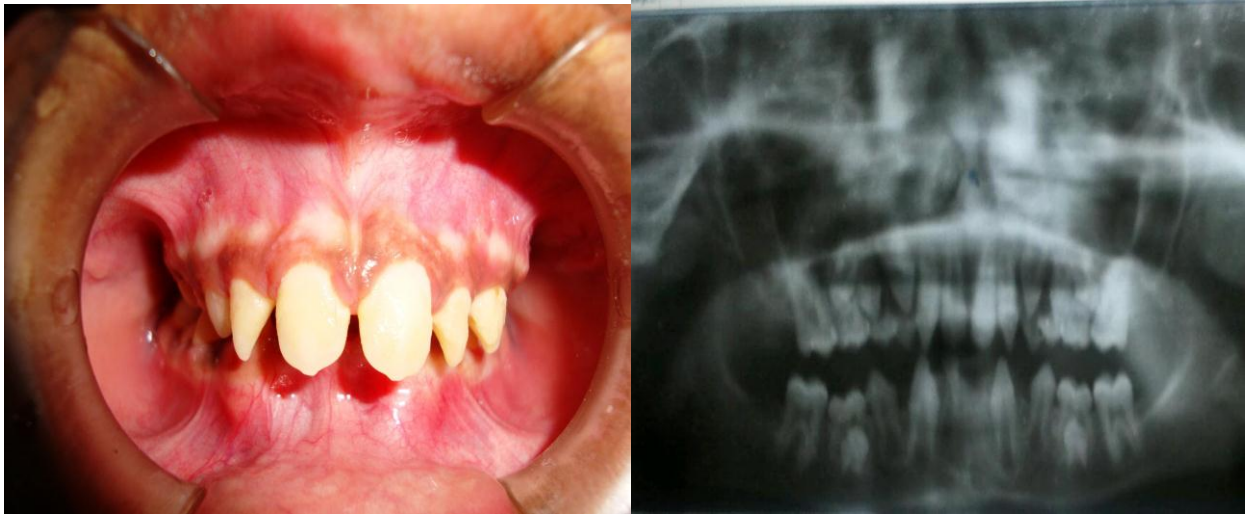


Figure 2: Close up view of permanent dentition of patient showing conical permanent maxillary incisors; and Panoramic radiograph showing pattern of hypodontia: missing all four permanent second molars and mandibular incisors; retained primary mandibular central incisor is seen

disease. However, oligodontia is seen more common in non-syndromic or familial form than syndromic form (4).

The biologic basis for the congenital absence of permanent teeth is partially explained by the failure of the lingual or distal proliferation of the tooth bud cells from the dental lamina. The causes of hypodontia are attributed to environmental factors such as irradiation, tumours, trauma, hormonal influences, rubella, and thalidomide or to hereditary genetic dominant factors, or to both (5). *MSX1* and *PAX9* genes play a key role in early tooth development. *PAX9* is a paired domain transcription factor that plays a critical role in odontogenesis. All mutations of *PAX9* identified to date have been associated with nonsyndromic form of tooth agenesis (6).

Oligodontia condition should not be neglected as it may result in various disturbances like abnormal occlusion, altered facial appearance which may cause psychological distress, difficulty in mastication and speech. Treatment depends on extent of hypodontia and should consist of interdisciplinary approach. Therefore early diagnosis is important in such conditions. Case of tooth agenesis should be recorded with complete clinical history including medical and radiological investigations to rule out any syndrome (7).

In conclusion, even though oligodontia is mostly considered to be associated with several syndromes but non syndromic aspect of Oligodontia should also be taken into

consideration. Taking this fact to account, the dental fraternity should aim at treating the condition as early as possible and achieve both prosthetic and aesthetic functionality of teeth.

REFERENCES

1. Tavajohi-Kermani H, Kapur R, Sciote JJ. Tooth agenesis and craniofacial morphology in an orthodontic population. *Am J Orthod Dentofacial Orthop* 2002; 122: 39-47.
2. Hosur MB, Puranik RS, Vanaki SS. Oligodontia: A Case Report and Review of Literature. *World Journal of Dentistry*, 2011; 2: 259 – 262.
3. Arte S, Pirinen S. Hypodontia. Orphanet Encyclopedia, 2004; 1-7.
4. Cobourne MT. Familial human hypodontia- is it all in the genes? *Br Dent J*, 2007; 203: 203-208.
5. Mostowska A, Biedziak B, Trzeciak WH. A novel mutation in *PAX9* causes familial form of molar oligodontia. *Eur J Hum Genet*, 2006; 14: 173-179.
6. Guruprasad R, Nair PP, Hegde K, Singh M. Case report: nonsyndromic oligodontia. *JIDA*, 2011; 3:450-454.
7. Singh AP, Boruah LC. Nonsyndromic oligodontia in Permanent Dentition of three siblings: A case report. *JIDA*, 2009;3:117-119.