

CASE REPORT**Split Calvarial Graft and Titanium Mesh for Reconstruction of Post-Craniotomy Frontal Bone Defect**Shimels Megersa Gema^{1,2}, Mehrnoush Momeni^{3*}, Amir Ali Badri³**OPEN ACCESS**

Citation: Shimels Megersa Gema, Mehrnoush Momeni, Amir Ali Badri. Split Calvarial Graft and Titanium Mesh for Reconstruction of Post Craniotomy Frontal Bone Defect. Ethiop J Health Sci.2017;28(2):245.

doi:<http://dx.doi.org/10.4314/ejhs.v28i2.16>

Received: July 19, 2017

Accepted: July 20, 2017

Published: March 1, 2018

Copyright: © 2018 Shimels Megersa, et al . This is an open access article distributed under the terms of the [Creative Commons Attribution License](#), which permits unrestricted use, distribution, and reproduction in any medium, provided the original author and source are credited.

Funding: Nil

Competing Interests: The authors declare that this manuscript was approved by all authors in its form and that no competing interest exists.

Affiliation and Correspondence:

¹Oral and Maxillofacial Surgery, Department of Oral and Maxillofacial Surgery, Tehran University of Medical Sciences, International Campus (TUMS-IC), Tehran, Iran

²Department of Oral and Maxillofacial Surgery, college of public health and medical sciences, Jimma University

³Oral and Maxillofacial Surgery at Sina Hospital, Tehran University of Medical Sciences, (TUMS), Tehran, Iran

*Email:

mehrnoushmomeni@yahoo.com

ABSTRACT

BACKGROUND: *The goal of cranioplasty is to achieve a lifelong, stable and structural reconstruction of the cranium covered by a healthy skin and scalp flap. We present two cases of large frontal bone defect following a accident.*

CASES: *We describe the utilization of autogenous local split calvarial graft and titanium mesh for the reconstruction of the post trauma frontal bone defect.*

CONCLUSION: *Cranioplasty using split calvarial bone grafting for restoring large cranial defects resulting from a trauma is a useful technique, and allows the surgeon to reconstruct a moderate to large cranial defect without rifting the inner cortical plate.*

KEYWORDS: *Bone Graft; Calvarial Splitting; Cranioplasty*

INTRODUCTION

Cranioplasty is one of the oldest known surgical procedures, with archaeological evidence of ancient Incans using gold to reconstruct trephination holes around 3000 BC. The earliest written account of cranioplasty dates back to 1505 when Ibrahim bin Abdullah, an Ottoman era military surgeon, advocated the use of cranial Xenografts from a goat or dog (1).

There is no ideal technique as each method has its limitations. When auto grafts are utilized, problems are encountered with satisfactory graft contour and long-term stability, particularly as regards resorption along with potential donor site morbidity. High infection rates and material failure have been reported with biomaterials (2).

The ideal material should be biocompatible, nonthermo conductive, radio transparent, nonmagnetic, lightweight, rigid, simple to prepare, easily applicable and inexpensive. No graft qualifies all the prerequisites in totality. However, autogenously split calvarial graft has proved its worth to be used as one of the best choices in the world literature. We describe the utilization of autogenous bone (split calvarial graft) and titanium mesh for reconstruction of large post-traumatic frontal bone defect in two cases.

CASE DESCRIPTIONS

Case 1: A 52-year old male patient present to outpatient department with the complaint of deformity at frontal region. He had a history of head trauma before seven years in which he sustained a depressed comminuted fracture of frontal bone on his right side.. Now, he present with cosmetic deformity of fore head (Figure 1), and he claimed that he could not get job because of this deformity. He did not have known past medical history.. The defect was reconstructed with split calvarial graft and titanium mesh.

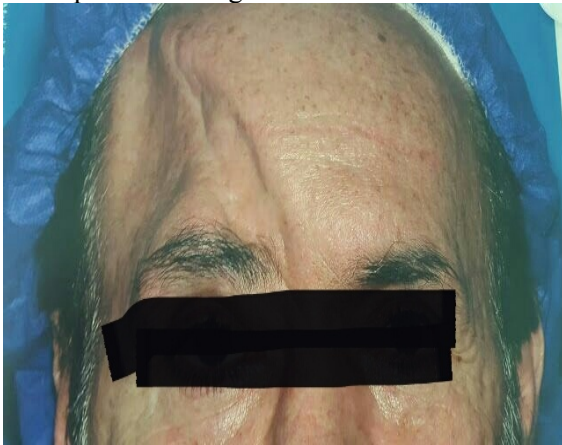


Figure 1: Pre-operative frontal view of patient

Operative sequences:

1. General anesthesia
2. Preparation and Draping
3. Approach Coronal incision (Figure 2).
4. Graft harvest from parietal bone
5. Defect reconstruction and fixation of the graft: The defect of superior orbital rim was reconstructed by 0.5x3cm bone harvested from the blunt lip of the defect.. The residual defect on posterior side and defect secondarily created due to bone harvest was covered with titanium mesh (Figure 2 A and B).
6. Incision closure: in two layers: (Figure 3).

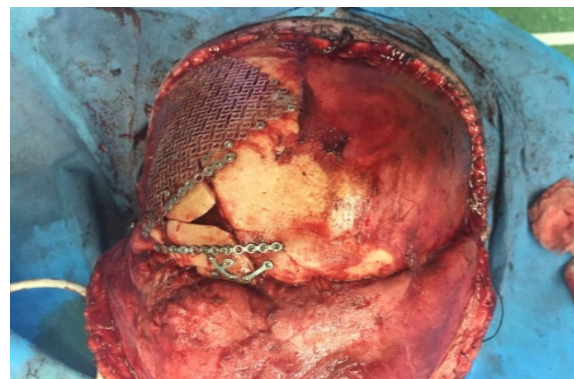
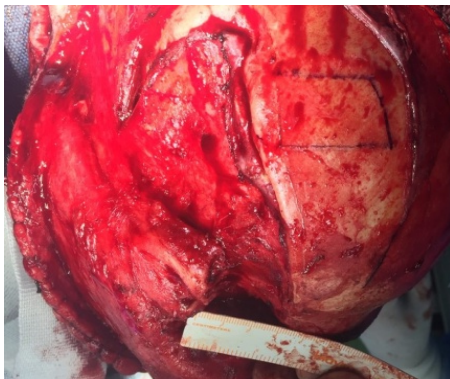


Figure 2: Intra operative photography of defect (A) reconstructed defect (B)

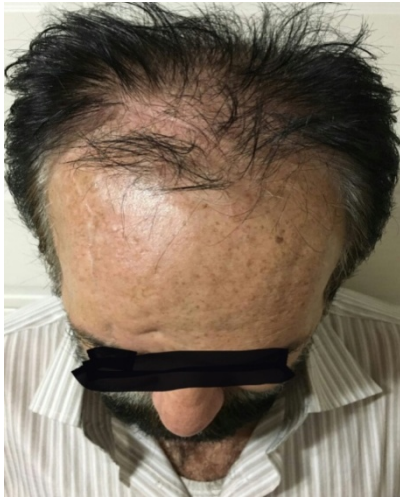

Figure 3: Post-operative appearance after 6 month, bird view

Case 2: A 20-year old man was referred to Emergency Department of Sina Hospital as a case of multiple traumas due to road traffic accident.. The patient was transferred to operating room where all loose fragments of fractured frontal bone was removed via the laceration on forehead area. After two and half month, he presented to our clinic with a cosmetic deformity of forehead on left side (4nA and B). He was a candidate for reconstruction of frontal deformity, treatment of ZMC fracture and orbital wall reconstruction.

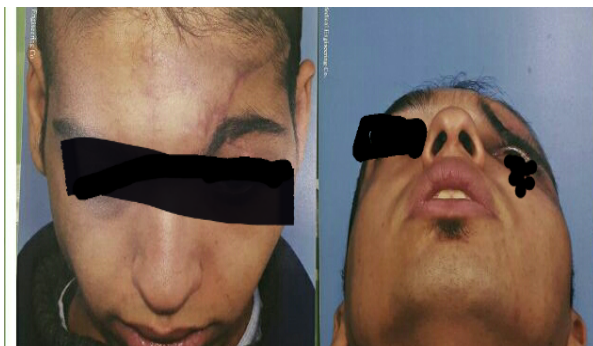


Figure 4: Pre-operative appearance, frontal view (A) , worm view(B)

The patient underwent a craniotomy through a coronal skin flap (incision placed 3cm behind hair line) to access defect of frontal area. The frontal bone defect was covered with split calvarial graft harvested from parietal bone and fixed with titanium micro plate and self-tapping micro screws

(Figure 5). The residual defect at superior orbital rim was covered with titanium mesh. The post-operative result was satisfactory (Figure 6).

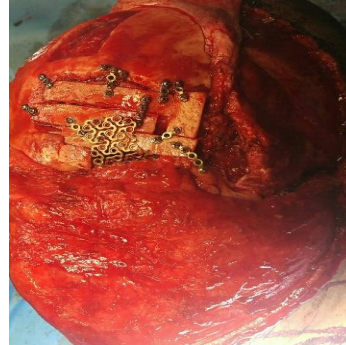


Figure 5: Intra-operative, site graft harvest (A) reconstructed defect (B)

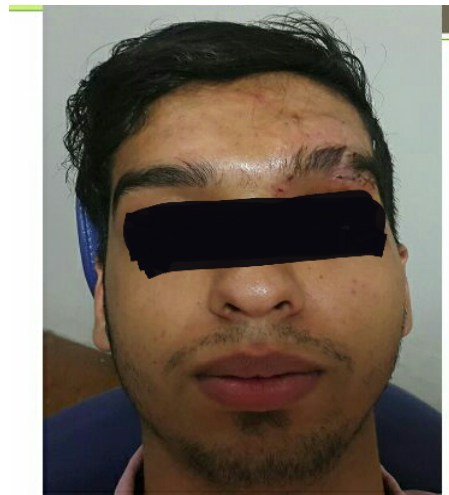

Figure 6: Post-operative appearance, 8 month after reconstruction

DISCUSSION

The primary indication of cranioplasty is to provide a mechanical protection to the brain. The broad classification on materials used for reconstruction of cranial defect are:

Bone grafts

- Autografts
- Cranial vault:
- Mandible
- Ilium
- Allograft
- Xenografts

Biomaterials

- Methyl methacrylate
- Calcium phosphate
- Titanium implants

Combination of bone grafts and biomaterials:

Autogenous bone graft has always been used as standard material for reconstruction of cranio-maxillofacial defect for ages. The the three main sources of autogenous bone graft to discuss are iliac crest bone graft, rib graft and split calvarial graft. Embryologically, the calvarial bones are intramembranous in origin. The intramembranous bone is more stable than the endochondral bone. Endochondral bone resorption rates are as high as 60–80%, whereas membranous bone resorption rates range from 17 to 20 %. Amongst autogenous grafts, split thickness calvarial graft fits into almost all the ideal requirements for cranial reconstruction. In a comparative study conducted by Moss et al. (3), the three main sources of autogenous bone grafts i.e., calvarial graft, iliac crest graft and rib graft were compared with demineralized bone matrix in restoring the cranial defect. They found that amongst the autogenous graft, calvarial graft is the ideal one for restoring the cranial defect in offering good contour and adequate mechanical support. The proximity of the cranial vault to other surgical sites, availability of relatively large quantities of bone and favorable consistency make cranial bone harvest an extremely viable reconstructive maneuver. Some of the notable disadvantages of the autogenous split calvarial graft are: Absorption, loss of contour, and difficulty to control cosmetic contour. This is not a preferred graft in extremes of ages because at age below 7 years, there might not be adequate diploic width to harvest and the availability will be insufficient. The mean thickness of the adult skull ranges from 6.80 to 7.72 mm but varies between 3.0 and 12 mm (4). In this case report, the age of the patient was 52 and 20 years which is the safest age group. However, most allograft materials may not be suitable in pediatric patients owing to skull growth. Thus, autologous bone grafts are often preferred in the reconstruction of the pediatric skull because of

their capacity to Osseo integrate and grow with the pediatric skeleton (5).

Cranioplasty using split calvarial bone grafting for restoring large cranial defects resulting from a trauma is a useful technique, and allows the surgeon to reconstruct a moderate to large cranial defect without rifting the inner cortical plate. The morbidity associated with the harvesting of cranial bone is low, and the residual harvest site defects can be camouflaged with titanium mesh.

REFERENCES

1. Sanan A, Haines SJ. Repairing holes in the head: a history of cranioplasty. *J Neurosurgery* 1997;40:588–603
2. Grant GA, Jolley M, Ellenbogen RG, Roberts TS, Gruss JR, Loeser JD. Failure of autologous bone-assisted cranioplasty following decompressive craniectomy in children and adolescents. *J Neurosurg* 2004; 100:163–8.
3. Moss SD, Joganic E, Manwaring KH, Beals SP. Transplanted demineralized bone graft in cranial reconstructive surgery. *J Pediatric Neurosurg* 1995;23(4):199–204.
4. Bradley ES, Thomas M. Calvarial bone graft harvest: anew technique. *J Otolaryngol Head Neck Surg* 2000; 123:547–552.
5. Josan VA, et al. Cranioplasty in children. *Childs Nerv Syst* 2005; 21:200–204.