

CASE REPORT**Tail-like Congenital Duplication of Lower Extremity (Extra Leg or Vestigial Parasitic Twin)****Temesgen Mekonnen^{1*}****OPEN ACCESS**

Citation: Temesgen Mekonnen. Tail-like Congenital Duplication of Lower Extremity (Extra Leg or Vestigial Parasitic Twin). *Ethiop J Health Sci.* 2017;28(1):103.

doi:<http://dx.doi.org/10.4314/ejhs.v28i1.14>

Received: June 13, 2017

Accepted: June 14, 2017

Published: January 1, 2018

Copyright: © 2018 Temesgen Mekonnen, et al. This is an open access article distributed under the terms of the [Creative Commons Attribution License](#), which permits unrestricted use, distribution, and reproduction in any medium, provided the original author and source are credited.

Funding: Nil

Competing Interests: The authors declare that this manuscript was approved by all authors in its form and that no competing interest exists.

Affiliation and Correspondence:

¹Department of Radiology and Imaging, Myungung Christian General Teaching Hospital and Medical College, Addis Ababa, Ethiopia

*Email: mekonnenem@yahoo.com

ABSTRACT

BACKGROUND: Congenital duplication of lower extremity, either complete or incomplete is extremely rare. Only 26 cases had been reported till 2010, of which only 5 cases had feature of complete duplication. Theories have been proposed that the cause of this abnormality includes maternal factors like diabetes and usage of teratogenic drugs. Duplication of lower extremity may mimic that of vestigial parasitic twin; phenotypically, it appears as an individual with extra appendage or limbs. Vestigial parasitic twigs are very rare comprising only 10% of all conjoined twins. Conjoined twin by itself is rare because the survival rate after birth is approximately 25%.

CASE DETAILS: A 5-year old female patient came from a rural area of Ethiopia was referred to our hospital for radiological diagnosis and to assess the vascular supply. No family history of similar congenital abnormality was identified. No known history of chronic illness or maternal usage of teratogenic drugs was identified either.

CONCLUSION: A child with parasitic twin and complete duplication of lower limb is reported. Tail-like soft tissue was found arising from sacral area. CT scan findings confirmed the duplication of the lower limb bones. Fatty tissue was the major component of the soft tissue almost replacing the muscle. Reconstructed CT angiography images showed major arterial blood supply of the parasitic limb. Surgical intervention was done successfully. This type of case is unusual. It is the rarest type of lower limb duplication.

KEYWORD: congenital duplication of lower limb, vestigial parasitic twin, pseudo tail

INTRODUCTION

Human limbs started to develop from the 4th weeks of post-fertilization. The lower limb buds appear 2 days after the upper limb buds. Each limb bud consists of a mass of mesenchyme covered by a layer of ectoderm. At the tip of each limb bud, the ectodermal cells form an apical ectodermal ridge (AER) which promotes the development and growth of that limb in the proximo-distal axis, i.e. from hip to foot (1).

In the literature, several etiological theories of limb duplication have been proposed and continue to be debated (2,3,4.). Hanley suggested that bifurcation or splitting of the limb bud may result in limb duplication(3). Packard proposed that an error of limb bud specification may induce supernumerary limb buds and leading the limb duplication(2).

Genetic mechanisms may also play as an etiological role.(4)

congenital duplication of the lower extremity (including the partial duplication) is quite rare. Only 26 cases had been reported in the literature till 2010 (5), but complete duplication of lower limb is more unusual.

Vestigial parasitic twin is a specific type of conjoined twins, It appears as parasitic because it is incompletely formed or wholly dependent on the body function of the complete fetus (autositic twin).

The phenotype of parasitic twins is one normal functioning individual with extra appendages or organs. However, there is a debate regarding whether the additional limbs are another person or just a mutation of the individual body. There are different types of parasitic twin including the Dipygus ('double buttocks') and pygomelia ('limbs attached to the buttocks')(6).

Statistics shows that only a few hundred conjoined twins are born across the globe each year, which is about one in every 100,000 births. Approximately, half are stillborn. The overall survival rate for conjoined twins is approximately 25%. Parasitic twins occurs in 10% of the cases of twins(6).

Parasitic twin of pygomyelia variety can also appear as a tail. A tail can be a true tail or pseudo tail. True tail can be defined as an extension from the coccyx (tailbone) where one might expect a so-called 'vestigial tail. However, so far, even a single report of true tail is not observed (probably never exist in human being).

The pseudo tail is an anomalous prolongation from the coccygeal vertebra; the prolongation

could be lipoma, teratoma, chondrodystrophy, or parasitic fetus. This type of tail may contain bone but not vertebra. This condition is relatively observed (6).

CASE REPORT

A 5-year old female patient came from a rural area of Ethiopia referred to MCM (the Korean Hospital) for CT angiography of the lower extremities, and to access the vascular supply of the tail like soft tissue growth. Her mother died after giving birth to this child. History from close relative remarked no similar congenital abnormality among the members of her family. There was no known maternal history of diabetes or teratogenic drug usage in the pregnancy. CT scan findings are summarized as follows.

Procedure done: Using multiplanar 8 slice General Electric CT machine, CT angiography of the lower extremities was performed., 17 cc of the Ultravist-370 was infused intravenously by using the power injector. The procedure was done under anesthesia using Ketamin IV infusion due to the patient's inability to stay still during the procedure

Radiologic findings: Image 1, demonstrate the morphologic CT appearance. There is an extra parasitic lower limb duplication attached from sacral area with extension to the presacral space (looks like a tail). Image 2 shows Skeletal images viewed from The oblique projections showing. normal right and left lower extremities

Extra lower limb was seen between the normal lower limbs. Comparison of the Parasite Femur Versus accompanied normal Femur:

-Length = 191 mm VS 238.8 mm

-Cortical thickness = 4.7 mm vs 4.8 mm

-Femoral shaft width = 8.9 mm vs 17.8 mm

The length of the parasitic (extra) femur was 80 % of the normal femur. Similarly, the width of the parasite femur was equivalent to 50% . However, the cortical thickness of both the parasitic and normal femur were almost equal.

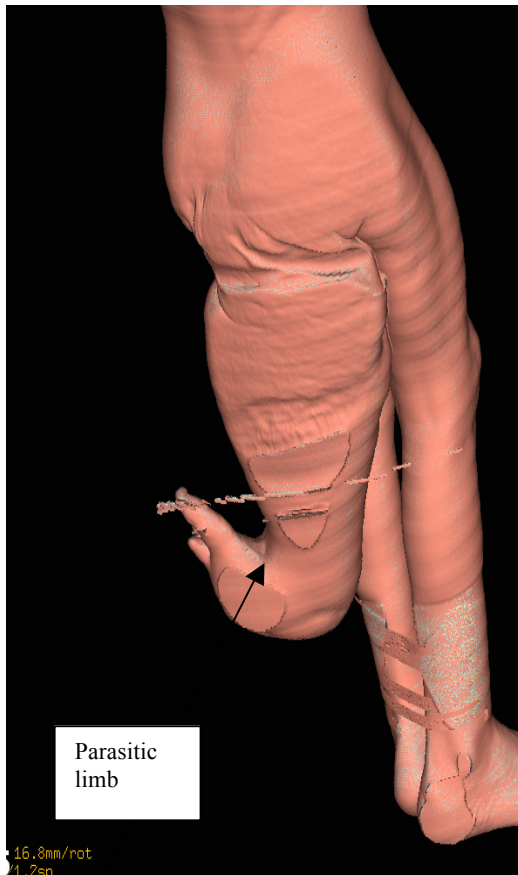


Image 1: Morphologic appearance of tail like soft tissue extension

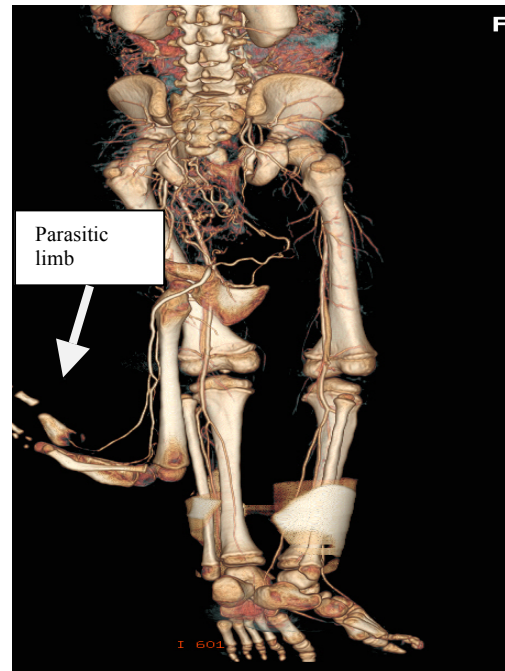


Image 2: Skeletal images viewed from the oblique projections showing- The normal right and left lower extremities , this image also demonstrate the extra limb (paras. Limb)

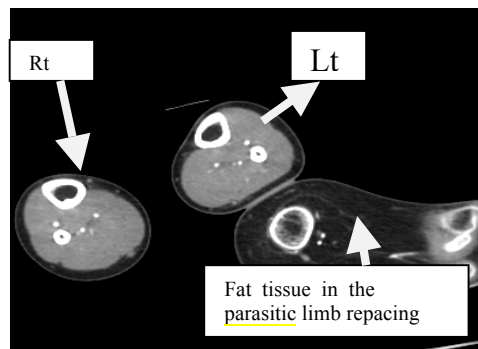
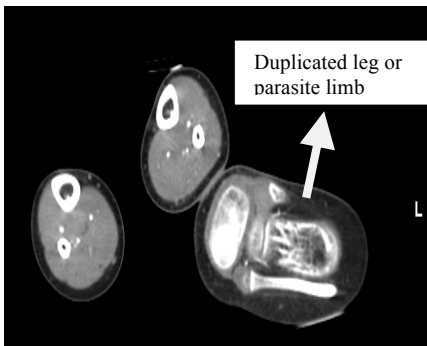


Image 3: Axial, CT scan images taken at the mid femoral shaft area demonstrating extensive fat density structures surrounding the femur with no obvious muscular tissue density (maximum thickness of the fat 68.4 mm)

Image 4 : Reconstructed vascular image showing the major vascular supply to the parasitic limb. As shown in the CT arteriographic image, an arterial blood supply originates from the bifurcation of the aorta (labeled as single*) and additional branches from the right and left internal iliac arteries appear as the major blood supply to this parasitic limb(indicated by double stars**). Similarly, mesh like collateral vascular structures are seen in the soft tissue of the parasitic twin .

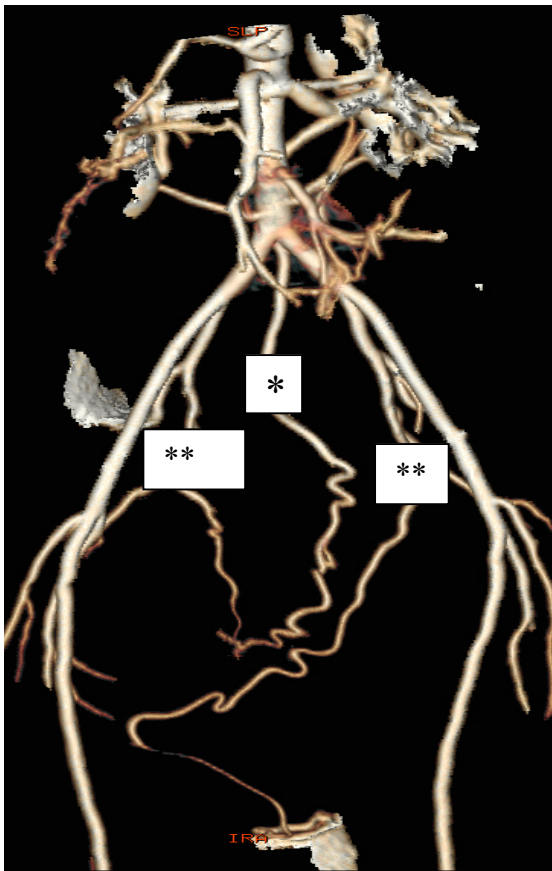


Image 5 : 5 yrs old child photo image with parasitic limb

Intervention: after evaluation of the radiologic images, surgical intervention was done. Incision was done by leaving adequate flap for wound coverage. then dissecting in a correct cleavage between the parasite and the main body. after reading the neurovascular bundle, the vessels and nerves were ligated. Parasitic tissue was resected completely leaving intact of the main body structures. Reconstruction of the access rectum, urogenital structure and sphincter and wound coverage with proper musculo cutaneous flap was done. All in all, the surgery was successful and the child returned to her rural village to continue the usual life. Yet, follow-up appointment was given.

DISCUSSION

This is an unusual case of a 5-year old child with morphologically tail like soft tissue (Image 1) which consists of bony structure of lower limbs, identified on CT scanning (Image 2). This case appears to be uncommon as it is the rare type of lower limb duplication with complete hemipelvis, femoral bone, patella, tibia and double fibula, tarsal, metatarsal, and toes (Image 2). Reviwing the previous literature, the commonest lower limb duplication is usually on the toes like polydactyl; our case is similar to that of Norman (published in 1964). This case also has a phenotypic appearance of vestigial parasitic twin with feature of pygomelia

Various reports of conjoined twins were published. but completely duplicated limb (extra leg) like this is very rare. I believe, such specific findings were not common. Genetic mechanism may be involved. As a recommendation, further researches are needed to pinpoint the causes. Moreover, in a

case of limb duplication, additional congenital anomalies should be searched during antenatal follow-up period. Ultrasound based diagnosis of intrauterine congenital abnormality has to be strengthened. Live born detected cases should come to health institutions for early surgical correction.

ACKNOWLEDGMENT

I would like to acknowledge the staffs in the department of Radiology for their encouragement and valuble supports, particularly Dr. Solomon Berkissa, Dr. Kuhn Hong, Dr. Yared Nigussie, Dr. Fanaye Yilma and Dr. Abiy Hiruy, I also forward gratitude to the MCM Hospital technical and administrative staffs for their kindly cooperation.

REFERENCES

1. Roberts D.J, Tabin C. The genetics of human limb development. *Am J Hum Genet.* 1994; 55: 1-6
2. Packard D.S, Levinsohn E.M, Hootnick D.R. Extent of duplication in lower-limb malformations suggests the time of the teratogenic insult. *Pediatrics* 1993; 91: 411.
3. Hanley E.N, Stanitski C.L. Incomplete congenital duplication of a lower extremity. *J Bone Joint Surg Am.* 1980; 62: 479-481.
4. McCredie J, Loewenthal J. Pathogenesis of congenital malformations. *Am J Surg*, 1978; 135: 293-297.
5. Y. osakie, S. nishimato, T. oyama, Y. yushumura. Congenital duplication of lower extremity A case report and review of the literature. *JRRAS (international journal of surgical reconstruction)*. 2010; 63: 390.
6. Wolpert L. Vertebrate limb development and malformations. *Pediatr Res.* 1999; 46: 247.