

CASE REPORT**HYPERCALCEMIA IN ASSOCIATION WITH SUBCUTANEOUS FAT NECROSIS OF THE NEWBORN****Abraham Haileamlak*, MD****ABSTRACT**

The case of a four weeks-old girl with subcutaneous fat necrosis and associated hypercalcemia is presented. Subcutaneous Fat Necrosis of the New born (SCFN) is an uncommon disorder which is rarely complicated with life threatening hypercalcemia. Though it is reported from many parts of the world this is the first case to the best of my knowledge from Ethiopia. The clinical & radiological manifestations with possible pathogenesis of hypercalcemia and management are discussed with review of literatures.

INTRODUCTION

Subcutaneous fat necrosis of the newborn is an uncommon inflammatory disorder of adipose tissue that occur primarily in the first four weeks of life as a firm subcutaneous nodules on the cheeks, back, arms, thighs & buttocks (1, 2). Harrison *et al* first described it in 1926 (3) and reported that it affects full term or post term newborns who have a history of peri-natal asphyxia or difficult labor and delivery (1, 2, 3). SCFN usually resolves over a period of months, but in some cases result in death due to its association with hypercalcemia (1-5). The association between SCFN of the newborn and hypercalcemia was first reported in 1950's however the mechanism that results in hypercalcemia remains incompletely understood (3,4,6,7). Several possible pathogenic mechanisms have been proposed, including increased vitamin D sensitivity, increased parathormone and prostaglandin E₂ activity and increased calcium release from necrotic tissue (6,7). An infant with subcutaneous fat necrosis and hypercalcemia is describe.

CASE REPORT

Baby Y.B., a 4-weeks old girl was born to a 28 years old gravida three, para one woman at 41 weeks of gestation and weighed 3900gm. Labor and delivery was difficult since the presentation was face and thus the neonate was asphyxiated with apgar scores of 2 and 5 at first and fifth minutes respectively. She was resuscitated and admitted to Ethio-Swedish Pediatrics hospital neonatology ward on first day of age on the 10th of November 1998 where she was diagnosed to have convulsions & polycythemia, which were treated accordingly & discharged improved.

Twenty-six days after birth, parents of the baby noticed hardening of the skin. On examination, erythematous plaques and nodules on the cheeks, arms back, buttocks & thighs in other wise healthy appearing infant were detected. Weight was almost the same during the subsequent three weeks.

*Department of Pediatrics & Child Health, Jimma University, P. O. Pox 378, Jimma, Ethiopia

Laboratory investigations showed hematocrit of 51%, platelets count of 180,000 per millimeter cubed, white blood cell count of 7200 per millimeter cubed and erythrocyte sedimentation rate of 50 millimeter in the first hour. X-ray of lower extremities showed diffuse subcutaneous calcifications (Fig-1) but normal electrocardiography finding. Serum calcium level was 14mg/dl (normal 9-11 mg/dl), phosphorus 4mg/dl (normal 4-7 mg/dl), magnesium, 2mg/dl (normal 1.6-2.5mg/dl). Fine needle aspiration cytology showed hemorrhagic background, which was not diagnostic. Initial therapy of

hypercalcemia consisted of intravenous hydration and intravenous Furosemide 1mg/kg 6 hourly, but the serum calcium remained high and started on oral Prednisolone 2mg/kg divided in to two doses. In 72 hours of initiation of prednisolone, serum calcium has normalized (8.2mg/dl) and the drug discontinued gradually after a week. Four weeks after the onset, she started to gain weight and the skin lesion resolved in two months time and she was quite healthy subsequently during her follow up visit for one year.

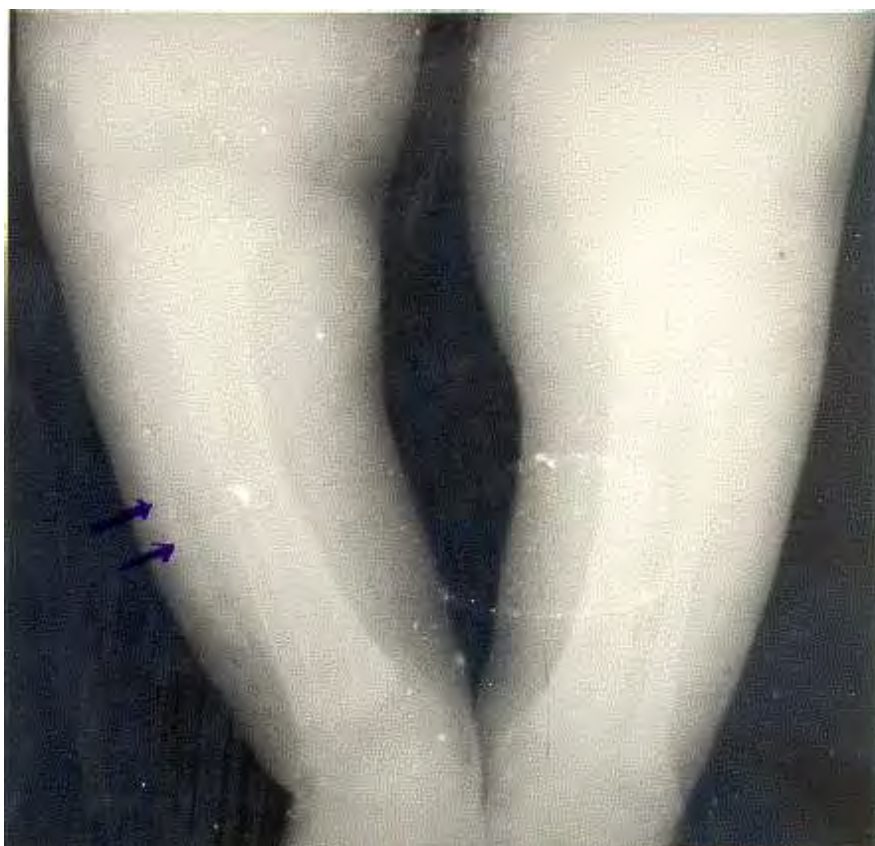

Figure-1. Roentgenogram of the lower extremities showing diffuse subcutaneous calcifications (arrow).

DISCUSSION

The skin lesions, radiological findings and perinatal course of this patient were characteristic of subcutaneous fat necrosis although the cytology was not diagnostic. Subcutaneous fat necrosis in this infant may be due to ischemic injury as complication of asphyxia (2) and polycythemia that had been followed by glaucomatous infiltration of the necrotic tissue. As mentioned above many factors were implicated in the pathogenesis of hypercalcemia in association with subcutaneous fat necrosis of the newborn though non of them were found to have cause effect relation ship based on previous endocrine studies (1,4,5). However, the most plausible explanation made is

increased interstitial calcium uptake by unregulated extra-renal production of 1, 25-dihydrxy vitamin D by Macrophages in the granulomatous infiltrate (fig-2) and as a result calcium deposition occur in the areas of fat necrosis (1,2).

Because subcutaneous fat necrosis of the newborn is rare disorder, physicians may not be familiar with the potential complication of hypercalcemia. Even when symptomatic hypercalcemia occurs, it doesn't become apparent until several weeks after birth and may be manifested as failure to thrive, vomiting, irritability or seizures (1,8). So after the diagnosis of subcutaneous fat necrosis the, infant should be followed closely for the first few weeks of life (1,3).

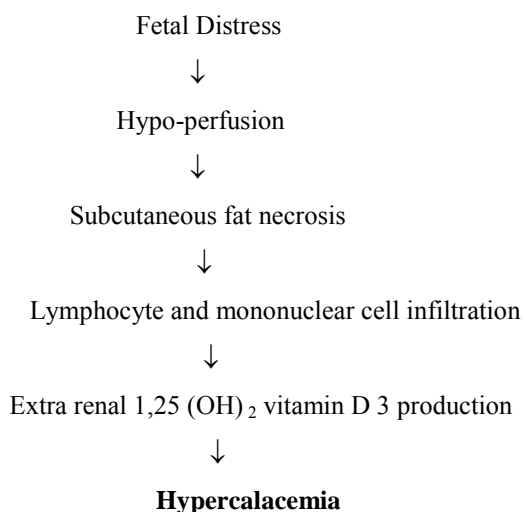


Figure-2. Proposed mechanism for hypercalcemia that occurs in association with subcutaneous fat necrosis of the new born.

REFERENCES

1. Cook J, Stone M, Hansen J. Hypercalcemia in association with subcutaneous fat necrosis of the new born; studies of calcium regulating hormones. *Pediatric*. 1992; 90: 93-96.
2. Darmstad G. and Lane A. Disease of subcutaneous tissue. In: Behrman, Kliegman and Arvin's; Nelson Text book of Pediatrics, 15th ed., W.B Saunders Company, Philadelphia. 1996; 1878-1880.
3. Harrison G, McNee J. An investigation and sclerema neonatorum with special reference to the chemistry of the subcutaneous tissues. Part 1, *Arch. Dis. Children* 1926; 1: 63-84.
4. Finne P, Sanderud J, Aksnes L, Bratlid D, Aarskog D. Hypercalcemia with Increased and unregulated 1,25-dihydroxy-vitamin D production in a neonate with subcutaneous fat necrosis. *J. Pediatr.* 1988; 112:792-794.
5. Metz S, Hassal E. PGE, Hypercalcemia and subcutaneous fat necrosis. *J. Pediatr.* 1980; 97: 336.
6. Veidhuis J, Kulin H, Demers L, Lambert P. Infantile hypercalcemia with subcutaneous fat necrosis: endocrine studies. *J. Pediatr.* 1979; 95: 460-462.
7. Baltrop D. Hypercalcemia associated with neonatal subcutaneous fat necrosis. *Arch. Dis. Children* 1963; 38:516-518.
8. Thomson R. Subcutaneous fat necrosis of the newborn and idiopathic hypercalcemia. *Arch. Dermatol.* 1980; 116: 1155-1158.