

## CASE REPORT

# KARTAGENER'S SYNDROME: A CLASSICAL CASE

Arunabha DC<sup>1</sup>, Sumit RT<sup>1</sup>, Sourin B<sup>2</sup>, Sabyasachi C<sup>3</sup>, Subhasis M<sup>4</sup>

### ABSTRACT

**BACKGROUND:** Recurrent lower respiratory tract infection (LRTI) is a very common problem we encounter in our clinical practice. Failure to recognize the specific cause of this condition may subject the patients to unnecessary and inappropriate treatment.

**CASE DETAILS:** among the various causes of recurrent LRTI, the most frequent causes are abnormalities of general or local impairment of immune mechanism and abnormalities of cilia or mucus of respiratory tract. We report an adult case of recurrent upper and lower respiratory tract infections since childhood along with situs inversus totalis which was diagnosed as Kartagener's syndrome. He had all the classical clinical and radiological features of Kartagener's syndrome which is a rare inherited disorder which is seen in nearly half of the cases of primary ciliary dyskinesia (PCD).

**CONCLUSION:** One should always keep in mind the possibilities of Kartagener's syndrome in patients presenting with recurrent upper and lower respiratory tract infections, sinusitis or bronchiectasis. Inability to diagnose this condition may subject the patient to unnecessary and repeated hospital admissions, investigations and treatment failure.

**KEY WORDS:** Kartagener's syndrome, primary ciliary dyskinesia, situs inversus, dextrocardia, sinusitis

**DOI:** <http://dx.doi.org/10.4314/ejhs.v24i4.13>

### INTRODUCTION

Kartagener's syndrome is an autosomal recessive disorder occurring with frequency of 1:30,000 to 1:40,000 (1). It is characterized by the classic triad of dextrocardia, bronchiectasis and sinusitis (2). Siewart first described this condition in 1904, but details of the condition were given by Manes Kartagener's in 1933 and thereafter it is classically known as Kartagener's syndrome. Abnormal ciliary motility is the basic pathology in this syndrome.

### CASE REPORT

A 40 years old nonsmoker male, street hawker by occupation and residing in a slum area, presented with frequent episodes of profuse expectoration, rhinorrhea and headache since childhood. There

was a history of episodic fever and intermittent worsening of symptoms for the previous five to seven years. The patient developed progressively increasing breathlessness on exertion and frequent episodes of hemoptysis for the last two years. He consulted various doctors for his symptoms since his childhood and was subjected to repeated hematological and radiological investigations, but could never reach a conclusive diagnosis. His symptoms relieved to some extent after several courses of antibiotics, oral steroids and bronchodilators as advised by different treating physicians during worsening of symptoms. However, these improvements were usually temporary and partial and all his basic symptoms persisted. He had even received a full course of anti-tubercular drugs without any symptomatic improvement. There

<sup>1</sup>Department of Pulmonary Medicine, R.G. Kar Medical College and Hospital, Kolkata

<sup>2</sup>Department of Pulmonary Medicine, All India Institute of Medical Sciences, Bhubaneswar

<sup>3</sup>Department of Pulmonary Medicine, Calcutta Medical College and Hospital, Kolkata

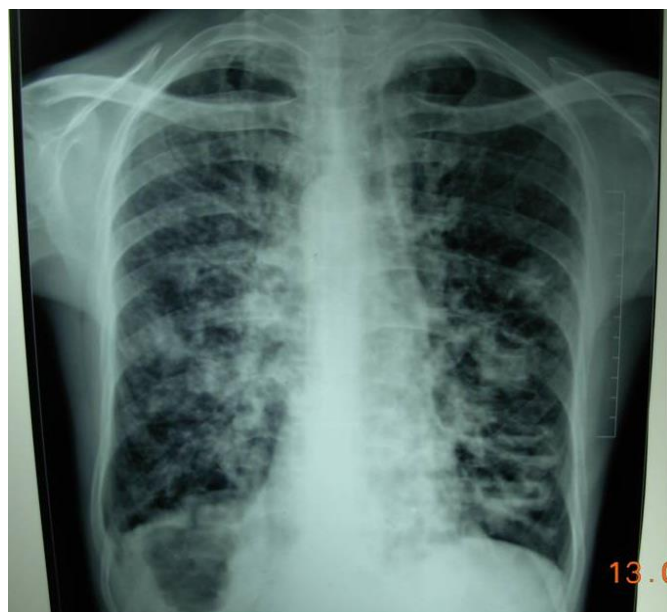<sup>4</sup>Department of Pulmonary Medicine, Sagar Dutta Medical College and Hospital, Kamarhati, Kolkata

**Corresponding Author:** Arunabha Datta Chaudhuri, Email: arunabhadc@rediffmail.com

were no persistent gastrointestinal symptoms since childhood. He had been married for 16 years, but had no issues and neither the husband nor the wife ever sought any medical help for infertility.

On clinical examination, the patient had moderate pallor, clubbing and fever. His accessory muscles of respiration were put into use and his respiratory rate was 34/minute. Cardiac impulse was located on the right fifth intercostal space one centimeter away from sternum, and heart sounds were best audible on the right side of the chest. There were bilateral wheeze and crackles all over the chest both anteriorly and posteriorly. The patient was examined by an oto-laryngologist and found to have features suggestive of chronic sinusitis and otitis media. All routine hematological investigations were within normal limits. Test for Human Immunodeficiency Virus (HIV) and sputum for Acid Fast Bacilli (AFB) were negative. Chest radiograph was done which showed multiple cystic spaces with air-fluid levels in some of them over mid and lower zones on either side (implicating cystic bronchiectasis with secondary infection) and transposition of the heart and gastric air (Figure 1). X-ray of the frontal and maxillary sinuses showed mucosal thickening and haziness of sinuses, suggestive of chronic sinusitis. Ultrasonography of whole abdomen showed liver on the left side and spleen on the right side (Figure -2). A 12 lead Electrocardiogram showed right axis deviation and 'q' waves in lead I and AVL. High resolution computed tomography (HRCT) of thorax showed cystic bronchiectasis in the lower lobes of both lungs (Figure 3) and transposition of liver (on the left side) and heart (on the right side) (Figure 4). CT scan of Para Nasal Sinuses revealed gross mucosal thickening in Maxillary sinuses, septal deviation and nasal polyps (Figure 5). Spirometry

showed an obstructive air way defect. On semen analysis, sperm morphology and count were normal but sperm motility test revealed plenty of immotile sperms. The sperm motility index was 16% (normal is >50%). The patient was diagnosed as a case of Kartagener's Syndrome after establishing the clinical triad of sinusitis, bronchiectasis and situs inversus in him. He was treated with antibiotics, bronchodilators and mucolytic agents, and there were signs of improvement. The prognosis was explained to the patient.



**Figure 1:** Chest X-ray PA view showing multiple cystic spaces with air-fluid levels over the mid and lower zones of either side, implicating cystic bronchiectasis with secondary infection. There is also transposition of the heart and gastric air

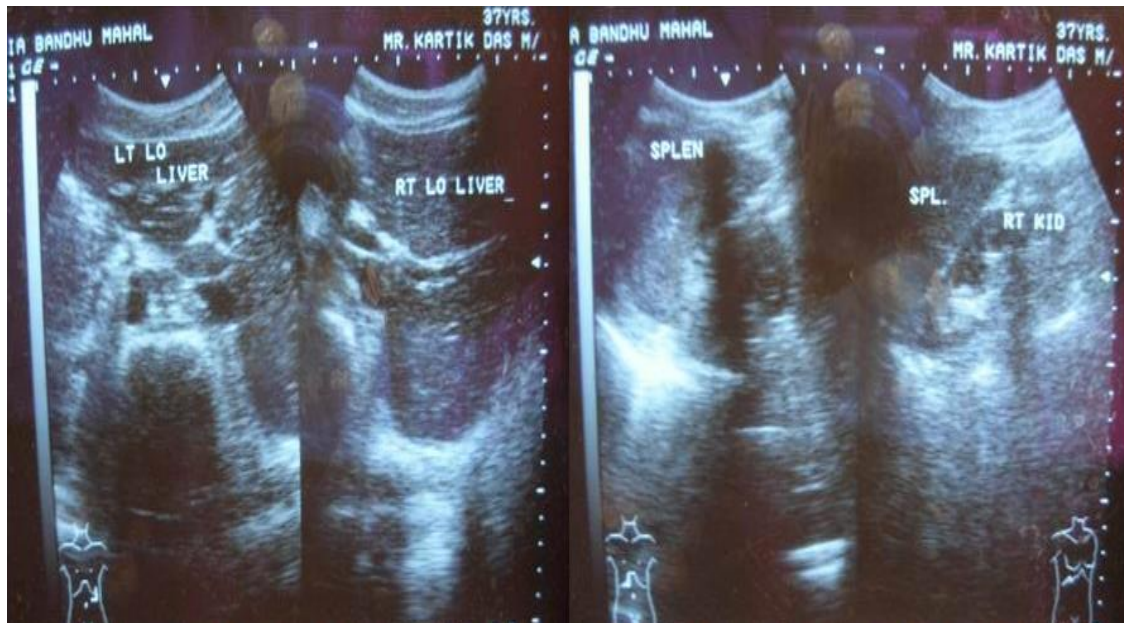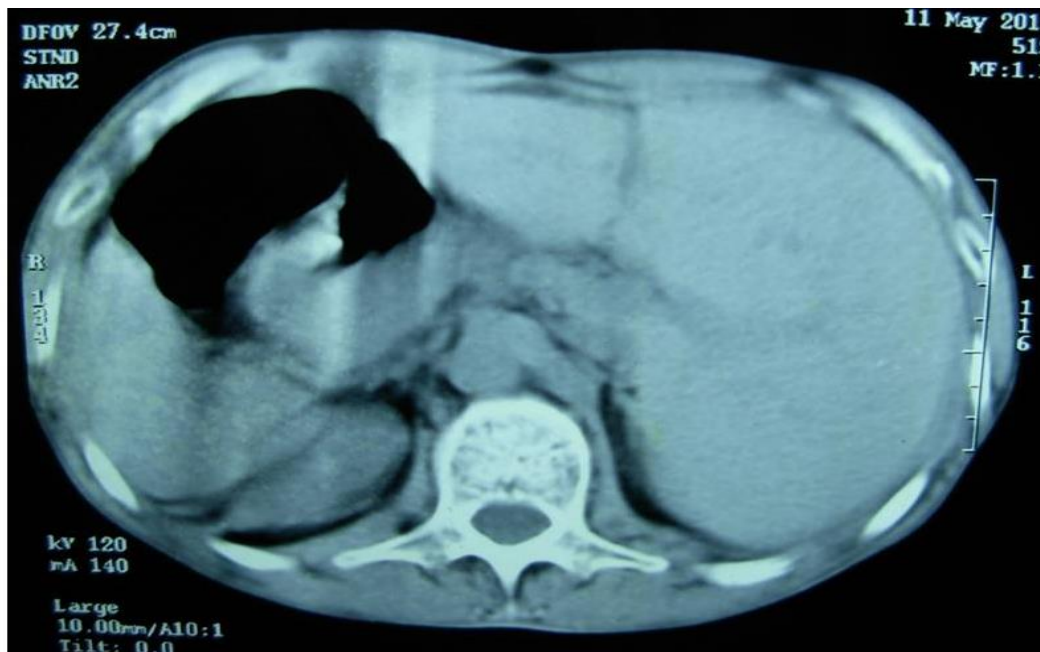


Figure 2: USG of upper abdomen showing liver on the left side and spleen and left kidney on the right side

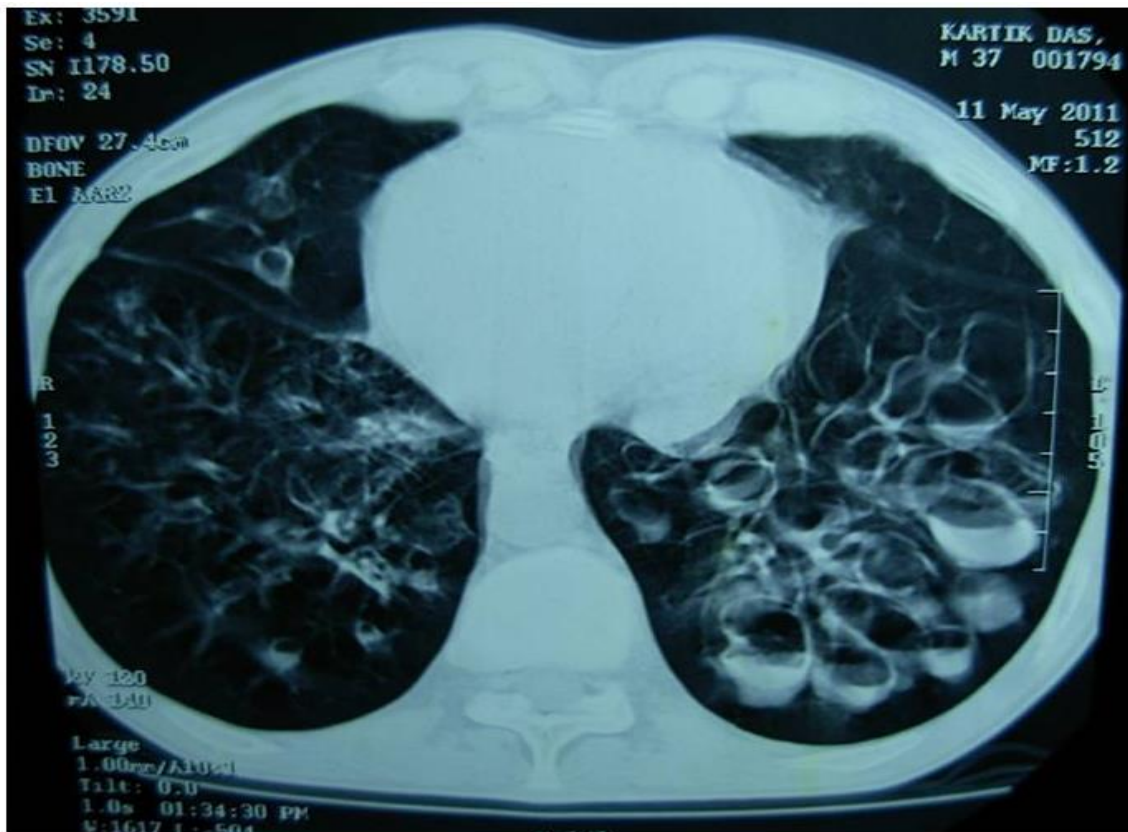

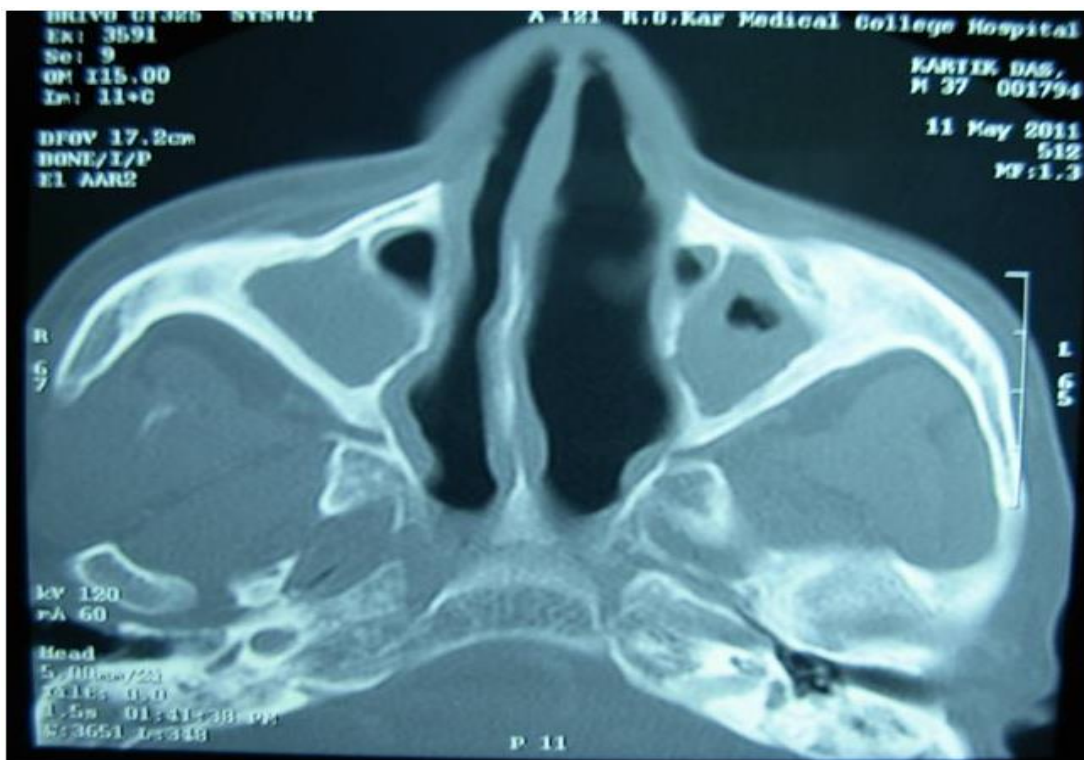Figure -3 - "CT scan of thorax (lung window) showing cystic bronchiectasis in the lower lobes of both lungs".

Figure 3: CT scan of thorax (lung window) showing cystic bronchiectasis in the lower lobes of both lungs



**Figure -4 - "CT scan of thorax (mediastinal window) showing transposition of liver (on the left side) and heart (on the right side)".**

**Figure 4:** CT scan of thorax (mediastinal window) showing transposition of liver (on the left side) and heart (on the right side)



**Figure -5- "CT scan of Para Nasal Sinuses showing gross mucosal thickening in Maxillary sinuses, septal deviation and nasal polyp".**

**Figure 5:** CT scan of Para Nasal Sinuses showing gross mucosal thickening in Maxillary sinuses, septal deviation and nasal polyp

## DISCUSSION

Ciliary movement disorders may be congenital or acquired. Congenital ciliary disorders are also known as primary ciliary dyskinesias (PCD). PCD is an inherited autosomal recessive condition characterized by bronchiectasis, sinusitis and otitis media. Approximately, one half of the patients with PCD have situs inversus (3). When situs inversus is associated with PCD, then it is referred to as Kartagener's syndrome (4). As PCD is a ciliary movement disorder and as normal ciliary beating is necessary for rotation of different viscera during embryonic development, half of the PCDs will have situs inversus because of random rotation and the other half will have normal situs (5). Numerous defects of cilia are encompassed under this category including structural abnormalities of the dynein arms, radial spokes and microtubules (6). Structural abnormalities of dynein arms are the most common (7). The cilia become dyskinetic, their coordinated, propulsive action is diminished and bacterial clearance is impaired. The clinical effects include recurrent upper and lower respiratory tract infections such as sinusitis, otitis media and bronchiectasis (6). Males are generally infertile because of immotile sperms (8). In rare cases, no structural ciliary abnormalities are detectable even though ciliary function is abnormal and the clinical syndrome is typical (9). Some males have completely normal spermatozoa (10).

Kartagener's syndrome may be either situs solitus in which case only dextrocardia is present or situs inversus totalis where all the viscera are on the opposite side (5). The patient in this report had situs inversus totalis. Impaired mucociliary clearance may be detected in adults by the presence of an abnormal saccharin test, in which the time is recorded for saccharin to be tasted in the mouth after it has been deposited on the inferior turbinate, and it usually takes 30 minutes in a normal person (11). It is also possible to measure ciliary beat frequency with appropriate specialized video microscopy (11). The availability of facilities for electron microscopy of sperm tails and respiratory cilia may produce diagnostic confirmation (12). These procedures are invasive and available only at highly specialized centers. The diagnosis of

Kartagener's syndrome in our case was based on clinical and imaging studies.

One should always keep in mind the possibilities of Kartagener's syndrome in those patients presenting with recurrent upper and lower respiratory tract infections, sinusitis or bronchiectasis. Although there is no specific treatment for this condition, failure to recognize the condition may subject the patient to unnecessary and repeated hospital admissions, investigations and inappropriate treatment (3).

## REFERENCES

1. Shukla V, Fatima J, Karoli R, Chandra A, Khanduri S. An unusual presentation of Kartagener's Syndrome. JAPI 2011, April; 59:266-68.
2. Kartagener M, Horlacher A. Situs viscerum inversus and polyposis nasi in einem Falle familiaerer Bronchiectasien. Beitr Klin Tub 1936; 87:331-33.
3. Masud IU, Din SU. Kartagener's Syndrome. Gom J Med Sci. 2006, Jul-Dec;4(2):79-81.
4. Olbrich H, Haffnax K, Kispert A, Volkel A, Volz A, Sasmaz G, et al. Mutation in DNA H5 cause primary ciliary dyskinesia and randomization of left right asymmetry. Nature Genet 2002;30:143-44.
5. None PG, Bali D, Carson JL et al. Discordant organ laterality in monozygotic twins with primary ciliary dyskinesia. Am J Med Genet 1999;82:155-60.
6. Gregory T, Weinberger SE. Bronchiectasis and Lung abscess. In: Harrison's Principles of Internal Medicine; 17<sup>th</sup>. Edition, Vol-II:1629-32.
7. Eavey RD, Nadol JB Jr, Holmes LB, Laird NM, Lapey A, Joseph MP, et al. Kartagener's Syndrome: A blinded controlled study of cilia ultrastructure. Arch Otolaryng Head Neck Surg 1986;112:646-50.
8. Herzon F, Murphy S. Normal ciliary ultrastructure in children with Kartagener's syndrome. Ann Otol Rhinol Laryng 1980;89:81-3.
9. Guerrant JL, Douty T, Tegtmeyer C, Jahrsdoerfer RA. Bronchiectasis in the immotile cilia syndrome. New Eng J Med 1978;298:282.

10. Jonson MS, Mc Cormick JR, Gillies CG, Gondos B, Kartagener syndrome with motile spermatozoa, *New Eng J Med* 1982;307:1131-33.
11. Seaton D. Bronchiectasis. In: Crofton and Douglas's respiratory disease; 5<sup>th</sup> edition, 2000, vol-1:794-828.
12. Greenstone M, Newman-Taylor A, Cole P. Bronchiectasis and oligospermia: two families. *Thorax* 1986; 41:80.