

# Femtosecond Laser Assisted Deep Anterior Lamellar Keratoplasty versus Manual Technique for Treatment of Keratoconus

Asaad Nooreldin\*, Ashraf Mohammed Gad EL-Kareem

Ophthalmology Department, Faculty of Medicine, Al-Azhar University, Assiut Branch, Egypt

\*Corresponding author: Asaad Nooreldin,

Email: Asaad\_nooreldin@yahoo.com, Mobile: 01026366024

## ABSTRACT

**Background:** DALK is a golden method for treatment of keratoconus with preservation of endothelium. femtosecond laser-assisted DALK (F-DALK) is a new technique used nowadays to overcome difficulties of an old one.

**Aims:** To contrast the results of manual deep anterior lamellar keratoplasty (M-DALK) with (F-DALK) in keratoconus studied cases. **Subjects and methods:** This prospective interventional research was carried out between January 2021 and December 2022. 36 eyes of 36 studied cases with advanced keratectasia were enrolled in this research and all underwent either manual (17 patients) or (F-DALK) (19 patients) at Tiba Eye Center, Assiut, Egypt. They were done by single surgeon.

**Results:** There was significant improvement in visual acuity at one month, 3 months, six months and 1 year post-operatively in 2 groups. Postoperatively, healing had been more evident post-operatively after the 6<sup>th</sup> month than after 1<sup>st</sup> and 3<sup>rd</sup> month. Side cut healing was more evident in the (F-DALK) patients than manual DALK studied cases with a statistically significant difference among the 2 groups ( $P < 0.02$ ). 12 eyes (63.2%) and 4 eyes (23.5 %) of F-DALK and M-DALK cases presented wound healing patterns Grade 4 respectively. **Conclusion:** Comparable visual and refractive results are obtained with both techniques; however, corneal wound healing patterns at the side cut were more noticeable with femtosecond assisted DALK. This observation suggests that, when femtosecond technology has been utilized to conduct the side cut for DALK, an active cornea wound healing may allow earlier suture removal.

**Keywords:** Cost effectiveness analysis, Deep anterior lamellar keratoplasty, Descemet's membrane, Endothelial cell density, Femtosecond laser, Femtosecond laser-assisted deep anterior lamellar keratoplasty.

## INTRODUCTION

For advanced cases of keratoconus with low visual acuity or contact lens intolerance, keratoplasty is regarded as the "golden" treatment. For this objective, penetrating keratoplasty has typically been utilized with encouraging visual results<sup>(1,2)</sup>. Nevertheless, PKP is linked to potentially blinding side effects including graft failure and endothelial cell rejection<sup>(3,4)</sup>.

By maintaining the studied case's own endothelium, deep anterior lamellar keratoplasty, or DALK, had been developed to reduce the difficulties associated with paraffin wax peeling<sup>(5)</sup>. But DALK has drawbacks of its own. Perfect execution of the treatment requires a higher level of surgeon experience and ability than PKP, and postoperative vision recovery is impacted by the inevitable corneal interface haze<sup>(5,6)</sup>.

New developments in the method for manual DALK trephination have somewhat overcome the latter constraint<sup>(7,8)</sup>. Another method of corneal surgery is the femtosecond laser. This innovative method improves precision and safety for a range of corneal procedures while offering the best reproducibility for corneal cutting<sup>(9,10)</sup>. Unlike M-DALK, femtosecond laser technology allows for customizable rim cuts for both donors and recipients, potentially impacting the overall integrity and function of the cornea<sup>(5)</sup>.

With this procedure, it is possible to achieve optimal apposition, precise and customized rim diameters for the

donor and recipient, perfect disparity sizes, and perhaps improved corneal shapes<sup>(7)</sup>.

Much prior research has published the outcomes of femtosecond laser-assisted DALK for keratoconus<sup>(11-18)</sup>. There is, however, few research that have contrasted the results of F-DALK with those of the conventional M-DALK<sup>(19-22)</sup>.

## THE AIM OF THE STUDY

To contrast the results of manual trephination deep anterior lamellar keratoplasty with femtosecond laser-assisted DALK in keratoconus studied cases.

## PATIENTS and METHODS

This prospective interventional research had been carried out between January 2021 and December 2022. 36 eyes of 36 studied cases with advanced keratectasia, 16 males and 20 females, had been enrolled in this research and all underwent either manual (17 patients) or femtosecond laser assisted DALK (19 patients) at Tiba Eye Center, Assiut, Egypt.

**Inclusion criteria:** The following inclusion criteria were considered in all participants: mean keratometric readings  $> 66.00$  D, clear cornea, thinnest corneal thickness more than 350  $\mu\text{m}$ .

**Exclusion criteria:** Excluded from this study were patients with; glaucoma filtering bleb or glaucoma shunt implants that may hinder the laser docking, retinal disorders, recent corneal perforation, bullous keratopathy or hydrops, and pregnant or lactating women.

### **Pre-operative evaluation of patients**

All participants underwent complete ocular examination made up of uncorrected distant visual acuity and best corrected distant visual acuity using Snellen's chart and the findings were converted into Log MAR units for the purpose of statistical analysis, slit-lamp examination of the anterior segment, corneal topography and keratometry had been done using pentacam®HR (OCULUS, Wetzlar, Germany), optical coherence tomography (Topcon 3D OCT-2000 series, Topcon Corp, Tokyo, Japan) of the anterior segment, dilated fundus assessment with indirect ophthalmoscope, and intraocular pressure measurement. Endothelium cell count (ECD) was evaluated using specular microscope (SP-3000P, Topcon Corp, Tokyo, Japan).

### **Operative procedure**

The technique was carried out under general anesthesia. Draping of the eye was done with sterile drape after skin and eye sterilization with povidone iodine (betadine) 10% and 5% respectively.

### **Surgical steps:**

Experienced surgeon carried out all operations by using the big-bubble technique in the manual group or femtosecond laser (wave light FS 200 Alcon, Fort Worth, Texas, USA) for the other group. Suction was initiated after a sterile disposable suction ring had been symmetrically positioned over the pre-marked cornea. By using X, Y and Z plane adjustments; ideal cone positioning, perpendicular appplanation, and perfect ducking had been achieved respectively during the suctioning step.

The laser beam was completely conjoined with the corneal mark and the position of the cutting pattern was in the corneal field before setting up the suction ring clip and complete eye fixation. The laser treatment was then initiated to achieve complete corneal dissection of the recipient and donor corneas. The fixation ring had been taken off and the suction had been shut off. After the studied case had eye patches placed, the 2<sup>nd</sup> part of the procedure had been performed in a main operating room.

The trephination diameter was 8.0 mm with the donor oversized by 0.25 mm, 2- 2.3 mJ side cut energy were used. The donor cornea was 1<sup>st</sup> given a full-thickness mushroom configuration side cut using the FS laser, and the recipient cornea was given a nonpenetrating mushroom configuration after that. sixty percent and eighty percent, respectively, of the thinnest corneal pachymetry was present in the recipient cornea at the depth of the anterior and posterior side incisions.

Using the Hessburg-Barron disposable vacuum trephine (Altomed Ltd, Grand blanc, Michigan, USA), manual group trephination had been performed up to sixty percent of the corneal thickness. The Fogla pointed dissector (Bausch and Lomb Storz Ophthalmic) had been used to perform lamellar corneal stromal dissection,

which created a tunnel for the air injection cannula (the Fogla twenty-seven-gauge air injection cannula, Bausch and Lomb Storz Ophthalmic).

Trypan blue dye staining assisted both groups in the debridement and peeling off the donor dermal membrane and endothelium. The recipient bed was then fastened to the donor graft using sixteen interrupted 10/0 nylon sutures.

Topical 0.5 percent moxifloxacin (4 times daily for two weeks, and then discontinued) and one percent prednisolone acetate (six times daily for four weeks) had been used to treat the eyes in the early postoperative phase. After 4 weeks, 0.1 percent fluorometholone acetate eye drops had been substituted for the prednisolone eye drops in a tapering regimen that involved taking it 4 times a day for the 2<sup>nd</sup> month, 3 times per day for the next month, twice per day for the 4<sup>th</sup> month, and once per day for up to twelve months following the procedure. Topical lubricants were used as eye drops during the recovery phase.

### **Post-operative assessment:**

All studied cases had been reassessed at 1 day, 1 week, two weeks, and then 1, 3, 6 months, and one year postoperatively. Complete ophthalmic examination at each examination was conducted including UCVA and BCVA, manifest refraction, OCT anterior segment, and signs of graft rejection, postoperative astigmatism, postoperative complications, and corneal topography.

### **Ethical Approval:**

**Tiba Eye Center's Ethics Board gave its approval for this study. Each participant provided his signed permission after receiving full information. The International Medical Association's Declaration of Helsinki, a guideline of ethics for human subject's research, served as the research's guiding.**

### **Statistical Analysis**

SPSS (Statistical Package for the Social Sciences, version 20, IBM, Armonk, New York) had been used to analyze the data that had been gathered. Nominal data had been expressed as frequency (%), and continuous data as mean  $\pm$  standard deviation (SD). Pre-operative and post-operative data of enrolled patients had been compared using Friedman test. P value was considered significant if  $< 0.05$ , and highly significant if  $< 0.001$ .

### **RESULTS**

A total of 36 eyes of 36 patients were enrolled in this research included 16 males (44.4%) and 20 females (56.6%) with a range of age between 18 - 42 years. There was no statistically significant difference among the 2 studied groups in age or gender (P 0.34). Keratoconus was the indication for keratoplasty in 28 cases (77.78%) while post-Lasik ectasia was the indication in 8 cases (22.22%).

**Table (1): Demographic data, VA and baseline k reading of studied cases**

<b>No of the patients</b>	36
<b>Age</b>	30± 12
<b>Gender M:F</b>	16:20
<b>VA</b>	1.1-1.4 log MAR
<b>Baseline K reading</b>	64+-3 D Range (61-67 )D
<b>Baseline astigmatism</b>	6.34+-1.25DC

No: number M: male F:female K:keratometry VA: visual acuity

There was significant improvement in UCDVA and BCDVA at one month, 3 months' six month and 1 year post-operatively with no statistically significant difference between the 2 groups (Table 2 and 3).

**Table (2): Pre-operative and post-operative visual outcome (M-DALK)**

	pre-operative	post-operative (Mean± SD)			P value
	(Mean± SD)	(first month)	(third month)	(sixth month) one year	
17 cases					
<b>UCDVA</b>	1.00 ± 0.80	0.70 ± 0.86	0.50 ± 0.93	0.20±0.86	<0.001**
<b>BCDVA</b>	0.90± 0.70	0.60±0.95	0.40 ± 0.85	0.1±0.74	<0.001**

\*\* Statistically significant difference

**Table (3): Pre-operative and post-operative visual outcome (F-DALK)**

	pre-operative	post-operative (Mean± SD)			P value
	(Mean± SD)	(first month)	(third month)	(sixth month) one year	
19 cases					
<b>UCDVA</b>	1.00 ± 0.90	0.60 ± 0.80	0.40 ± 0.79	0.20±0.97	<0.001**
<b>BCDVA</b>	0.80 ± 0.75	0.40±0.96	0.30 ± 0.64	0.00±0.80	<0.001**

\*\* Statistically significant difference

Postoperatively, the mean spherical error improved significantly at all follow-up periods (Tables 4) and cylindrical error improved throughout the follow-up period in both groups (Tables 5) with no statistically significant difference among the 2 groups at one, three, six months.

**Table (4): Pre-operative and postoperative spherical error between 2 groups**

	Pre-operative	Post-operative (Mean± SD)			P value
	(Mean± SD)	(1 <sup>st</sup> month)	(3 <sup>rd</sup> month)	(6 <sup>th</sup> month)	
<b>F-DALK</b>	-4.75 ± 1.45	-4.25 ± 2.25	-2.75 ± 1.00	-1.75 ± 1.00	<0.001**
<b>M-DLAK</b>	-6.75 ± 2.45	-4.50 ± 3.25	-3.25 ± 0.25	-2.45 ± 1.75	<0.001**

\*\* Statistically significant difference

**Table (5): Pre-operative and postoperative corneal cylinder**

	pre-operative	post-operative (Mean± SD)				P value
	Mean± SD	(first month)	(third month)	(sixth month)	one year	
<b>M-DALK</b>	-7.75 ± 1.92	-6.07±3.50	-5.20 ± 1.0	-4.85±1.08	-2.45 ±0.6	<0.001**
<b>F-DALK</b>	-7.00 ± 1.87	-5.00±2.50	-4.25 ± 1.0	-3.00±1.10	-2.00 ±0.6	<0.001**

\*\* Statistically significant difference

Flattest K (K1), steepest K (K 2) and K max showed a significant decrease at all follow-up periods postoperatively in both groups with no significant difference among them (Table 6 and 7).

**Table (6): Pre-operative and post-operative K reading (M-DALK)**

	Pre-operative	Post-operative (Mean±SD)				P value
	Mean±SD	(first month)	(third month)	(sixth month)	(one year)	
<b>K 1</b>	58.25 ± 8.5	40.70 ± 6.50	40.7±4.50	41.7±4.5	42.5.	0.004**
<b>K 2</b>	62.5 ± 7.25	42.60 ± 7.25	43.6±5.00	42.6±5.25	44.25	0.007**
<b>K max</b>	66.12 ± 9.39	43.09 ± 6.03	42.50±6.03	42.5±6.25	44.5	0.005**

\*\* Statistically significant difference.

**Table (7): Pre-operative and postoperative K reading (F-DALK)**

	Pre-operative	Post-operative (Mean±SD)				P value
	Mean±SD	(first month)	(third month)	(sixth month)	(one year)	
<b>K 1</b>	59.25 ± 4.5	40.50 ± 6.50	40.4±4.50	40.3±4.5	40.00	0.004**
<b>K 2</b>	61.5 ± 5.25	41.60 ± 7.25	41.5±5.00	41.20±3.25	41.15	0.007**
<b>K max</b>	67.12 ± 7.39	42.09 ± 4.03	42.00±6.03	41.75±6.25	41.75	0.005**

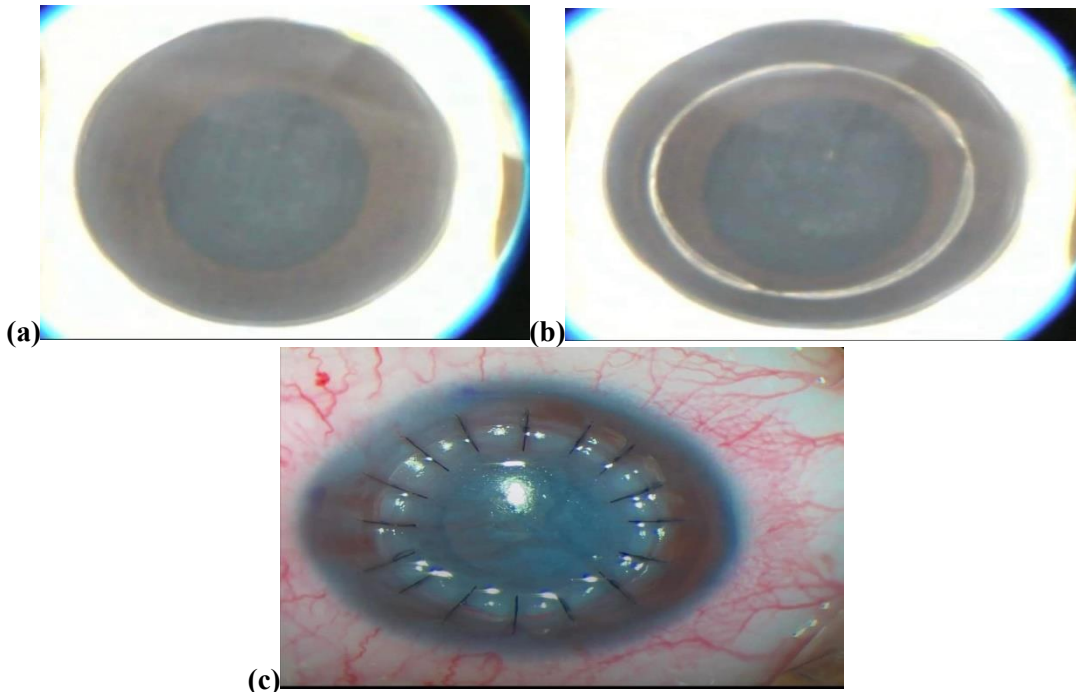
\*\* Statistically significant difference

Healing was more evident post-operatively in the 6<sup>th</sup> month than in the 1<sup>st</sup> and 3<sup>rd</sup> month. Suture removal begins at 6 months and completely removed at 1 year postoperatively.

Side cut healing was more evident in the femtosecond DALK patients than manual DALK studied cases with a statistically significant difference among the 2 groups (*P*0.02), 12 eyes (63.2%) and 4 eyes (23.5 %) of F-DALK and M-DALK cases respectively, showed wound healing patterns Grade 4.

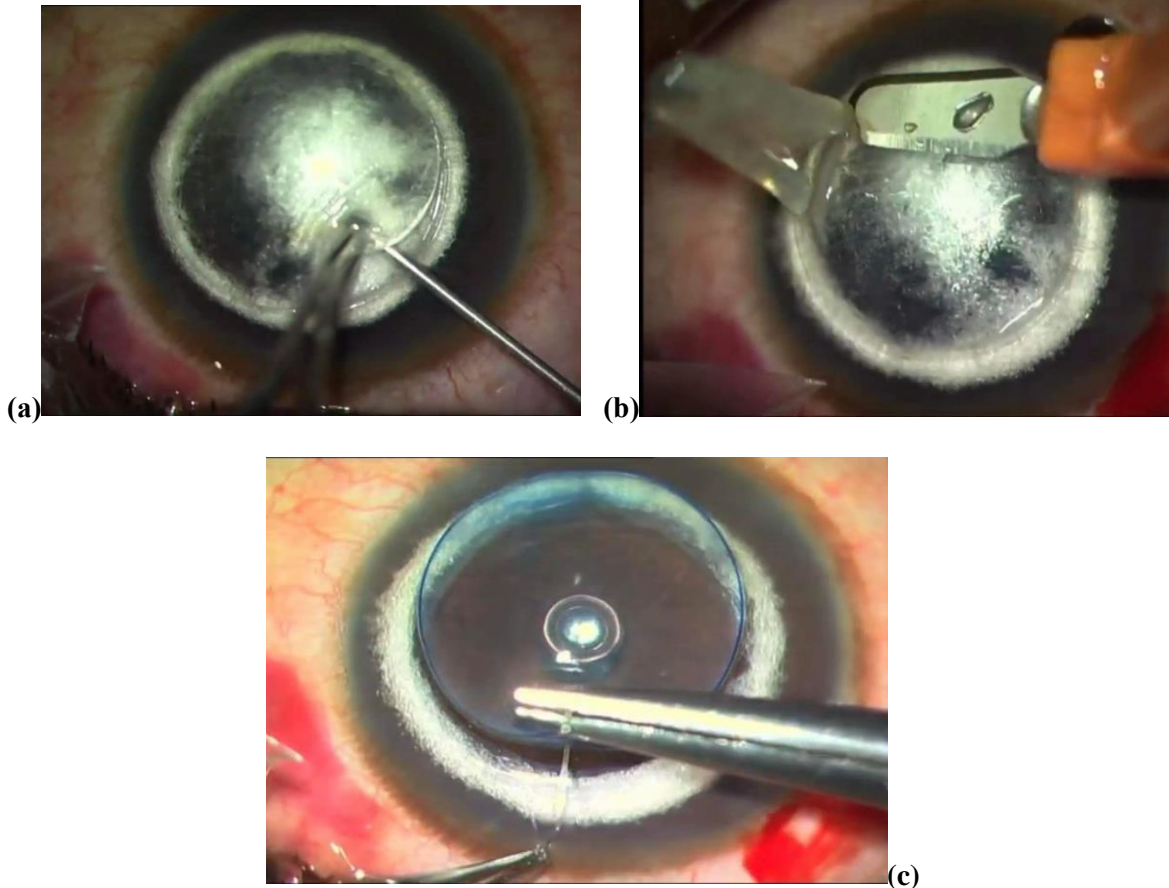
Post-operative complications were postoperative graft rejection in one case at 7 months postoperatively and 1 case of graft failure. Intraocular pressure was increased in 2 cases and controlled with topical anti- glaucoma medication. Loose and infected sutures happened in one case that was treated by topical antibiotic drops (moxifloxacin 0.5%) with removal of the loose sutures. Wound dehiscence occurred in 1 case, which was treated by resuturing.

**CASE 1: F-DALK**



**1: Intraoperative and postoperative images of a representative patient who underwent femtosecond laser- (FSL-) assisted big-bubble deep anterior lamellar keratoplasty: (a) shape and size of FSL incisions; (b) successful formation of big bubble; (c) end of the surgery and shape of corneal stitches.**

**CASE 2: M-DALK**



**1: Intraoperative images of a representative patient who underwent Manual-deep anterior lamellar keratoplasty: (a) making a dissection of lamellae by big bubble technique (b) removal of the anterior lamellae by crescent (c) start suturing of the cornea.**

**DISCUSSION**

While several studies have demonstrated the effectiveness of F-DALK in treating keratoconus, few research has yet to compare this approach to the more established M-DALK. **Shehadeh-Mashor et al.**<sup>(21)</sup> compared the results of M-DALK (n=nineteen; eighty-four percent keratoconus) with F-DALK (n=nineteen; sixty-eight percent keratoconus) employing the side-cut mushroom configuration in retrospect. They employed the big-bubble methods of Anwar or Melles. They observed no discernible change in astigmatism, refraction, or BSCVA between groups at twelve months; however, they did note that F-DALK showed a faster visual recovery at three weeks compared to M-DALK. In terms of corneal astigmatism and visual outcome, their results are consistent with ours. They could not, however, discover any appreciable variation in SE refraction.

The results for SE refraction seem ambiguous given their limited sample size, high variance in SE refraction, and inclusion of illnesses other than keratoconus. **Alio et al.**<sup>(19)</sup> revealed similar outcomes in terms of topographic cylinder and corrected visual acuity

for M-DALK (large bubble method) versus F-DALK (mushroom-shaped side-cut) at one year following the procedure in a mixed prospective/retrospective design (N=fifty; twenty-five in each group). In terms of uncorrected distant acuity one month following surgery, they discovered that F-DALK patients recovered their eyesight more quickly. **Blériot et al.**<sup>(20)</sup> used the big bubble technique to perform a retrospective comparison research between F-DALK (n = nineteen; with vertical side-cut) and M-DALK (n = seventeen) in studied cases with advanced keratoconus. They found no statistically significant difference in corrected visual acuity, mean keratometry, astigmatism, or endothelial cell count among the 2 procedures at the twelve-month follow-up.

**Li et al.**<sup>(22)</sup> retroactively used their described diamond knife lamellar dissection method to compare the outcome of F-DALK (n=89) vs M-DALK. In comparison to M-DALK cases, they observed that F-DALK patients had improved visual outcomes one year following surgery, as well as a noticeably flatter cornea and less corneal astigmatism.

Based on our findings and the results of the studies, F-DALK appears to offer studied cases with advanced keratoconus at least equivalent corrected visual acuity outcomes at twelve- and twenty-four-months following surgery compared to M-DALK. Certain investigations have reported an association between F-DALK and fast visual recovery. It's debatable right now whether the F-DALK technique provides a better long-term visual function and this needs more research<sup>(20)</sup>.

Regarding the mean keratometry values, our findings did not match with **Li et al's** research that revealed significantly lower levels in F-DALK studied cases compared to M-DALK studied cases. **Alio et al.**<sup>(19)</sup> did not mention the mean keratometry values in their research, and **Shehadeh-Mashor et al.**<sup>(21)</sup> included studied cases who did not have keratoconus, which complicates drawing conclusions about the keratometry data. The last twelve-month average keratometry in **Blériot et al.**<sup>(20)</sup> compared to M-DALK, was 45.5 and 46.5 D, respectively ( $p=0.16$ ); there are a few logical explanations for why F-DALK would result in a flatter cornea than M-DALK.

**Alio et al.**<sup>(19)</sup> have demonstrated that F-DALK exhibits more active corneal wound healing patterns at the side-cut than M-DALK. The transplanted cornea may become more flattened because of the greater contracture caused by a more noticeable corneal scar. The F-DALK procedure's more powerful flattening effect may possibly be attributed to the side-cut's customizable forms. Lastly, a flatter graft in the F-DALK group may result from the F-DALK eyes having a lower donor-recipient discrepancy than the M-DALK eyes.

In line with **Li et al.**<sup>(22)</sup>, other mentioned research<sup>(19-21)</sup> neither of which found any conclusive evidence of an advantage for F-DALK in terms of residual corneal astigmatism twelve- or twenty-four-months following surgery. A significant factor influencing post-DALK corneal astigmatism is the surgeon's suturing technique, which may get better with time. For the best outcomes, timely and appropriate removal of tight sutures following surgery may be as important.

Thus, before making any conclusions about the approach that will provide better astigmatic results, these characteristics must be controlled among groups. The F-DALK and M-DALK groups had similar rates of problems, according to our findings. The side-cut form and size of the donor and recipient cornea can be customized for each studied case using femtosecond laser technology, which has been more accurate than manual trephination. Both sides of the side-cut cannot be guaranteed to be circular by hand trephination.<sup>(21)</sup>

Furthermore, the manual procedure requires the use of speculum, which might further influence the appropriate shape of the side-cut because of applying pressure on the eye, unlike the femtosecond laser-assisted

side-cut preparation. The shape of the side-cut and the accuracy of the disparity could affect the visual performance, which had been the goal of the current research, even though using the same technique for stromal bed preparation could partially explain the similar visual result of M-DALK versus F-DALK.<sup>(19)</sup> When it came to the rim-cut shape, we discovered that under both suture-in and suture-out circumstances, the mushroom had a steeper cornea than the decagonal rim-cut form.

The observed difference in the mean keratometry value may indicate a stronger flattening impact of the decagonal than the mushroom technique, as we employed similar donor-recipient discrepancy in both procedures. Additionally, postoperative Q-value values indicated a more prolate shape for the decagonal procedure; however, the final visual acuity function and aberrometric indices did not change between the two methods.

To address unresolved difficulties, a well-designed randomized controlled experiment on this topic is needed in the future. Up until then, surgeons may utilize the findings of this publication to guide their work and design studies for the future. In summary, our research (with a suitable sample size) confirms the comparable outcomes of F-DALK and M-DALK for advanced keratoconus at twelve months about corneal astigmatism and visual recovery.

After all sutures had been removed, the 2 surgeries had been comparable in terms of those characteristics at the twelve-month follow-up. Ultimately, the F-DALK appears to be a good choice in cases of advanced keratoconus, showing outcomes that are like those of the conventional M-DALK and possibly offering some morphological and refractive benefits over the manual method.

## CONCLUSION

While the visual and refractive results obtained by manual and femtosecond-assisted DALK are similar, the corneal wound healing patterns at the side cut are more noticeable with femtosecond-assisted DALK. This observation suggests that when femtosecond technology has been utilized to make the side cut for DALK, an active cornea wound healing may allow earlier suture removal.

## DECLARATIONS

- **Consent for publication:** Each author has given his consent to submit the work.
- **Availability of data and material:** Available.
- **Competing interests:** None
- **Funding:** No fund.
- **Conflicts of interest:** no conflicts of interest.

## REFERENCES

- 1. Troutman R, Lawless M (1987):** Penetrating keratoplasty for keratoconus. *Cornea*, 6:298–305.
- 2. Tan D, Dart J, Holland E et al. (2012):** Corneal transplantation. *Lancet*, 379:1749–61.
- 3. Wagoner M, Ba-Abbad R, Al-Mohaimed M et al. (2009):** Postoperative complications after primary adult optical penetrating keratoplasty: prevalence and impact on graft survival. *Cornea*, 28:385–94.
- 4. Olson R, Pingree M, Ridges R et al. (2000):** Penetrating keratoplasty for keratoconus: a longterm review of results and complications. *Journal of Cataract and Refract Surgery*, 26:987–91.
- 5. MacIntyre R, Chow S, Chan E et al. (2014):** Long-term outcomes of deep anterior lamellar keratoplasty versus penetrating keratoplasty in Australian keratoconus patients. *Cornea*, 33:6–9.
- 6. Abdelkader A, Elewah E, Kaufman H (2010):** Confocal microscopy of corneal wound healing after deep lamellar keratoplasty in rabbits. *Arch Ophthalmol.*, 128:75–80.
- 7. Tan D, Anshu A. (2010):** Anterior lamellar keratoplasty: 'Back to the Future'- a review. *Clin Exp Ophthalmol.*, 38:118–27.
- 8. Tan D, Anshu A, Parthasarathy A et al. (2010):** Visual acuity outcomes after deep anterior lamellar keratoplasty: a case-control study. *Br J Ophthalmol.*, 94:1295–9.
- 9. Lubatschowski H, Maatz G, Heisterkamp A et al. (2000):** Application of ultrashort laser pulses for intrastromal refractive surgery. *Graefes Arch Clin Exp Ophthalmol* ,238:33–9.
- 10. Durrie D, Kezirian G (2005):** Femtosecond laser versus mechanical keratome flaps in wavefront-guided laser in situ keratomileusis: prospective contralateral eye study. *J Cataract Refract Surg.*, 31:120–6.
- 11. Chan C, Ritenour R, Kumar N et al. (2010):** Femtosecond laser-assisted mushroom configuration deep anterior lamellar keratoplasty. *Cornea*, 29:290–5.
- 12. Buzzonetti L, Laborante A, Petrocelli G (2011):** Refractive outcome of keratoconus treated by combined femtosecond laser and big-bubble deep anterior lamellar keratoplasty. *J Refract Surg.*, 27:189–94.
- 13. Buzzonetti L, Laborante A, Petrocelli G (2010):** Standardized big-bubble technique in deep anterior lamellar keratoplasty assisted by the femtosecond laser. *J Cataract Refract Surg.*, 36:1631–6.
- 14. Lu Y, Shi Y, Yang L et al. (2014):** Femtosecond laser-assisted deep anterior lamellar keratoplasty for keratoconus and keratectasia. *Int J Ophthalmol.*, 7:638–43.
- 15. Buzzonetti L, Petrocelli G, Valente P et al. (2015):** The big-bubble full femtosecond laser-assisted technique in deep anterior lamellar keratoplasty. *J Refract Surg.*, 31:830–4.
- 16. Chen Y, Hu D, Xia Y et al. (2015):** Comparison of femtosecond laser-assisted deep anterior lamellar keratoplasty and penetrating keratoplasty for keratoconus. *BMC Ophthalmol.*, 15:144.
- 17. Espandar L, Mandell J, Niknam S (2016):** Femtosecond laser-assisted decagonal deep anterior lamellar keratoplasty. *Can J Ophthalmol.*, 51:67–70.
- 18. Lu Y, Duan X, Chen X et al. (2014):** [The clinical results of femtosecond laser-assisted deep anterior lamellar keratoplasty in patients with keratoconus]. *Zhonghua Yan Ke Za Zhi.*, 50:267–72.
- 19. Alio J, Abdelghany A, Barraquer R et al. (2015):** Femtosecond laser assisted deep anterior lamellar keratoplasty outcomes and healing patterns compared to manual technique. *Biomed Res Int.*, 2015:397891.
- 20. Blériot A, Martin E, Lebranchu P et al. (2017):** Comparison of 12-month anatomic and functional results between Z6 femtosecond laser-assisted and manual trephination in deep anterior lamellar keratoplasty for advanced keratoconus. *J Fr Ophtalmol.*, 40: e193–200.
- 21. Shehadeh-Mashor R, Chan C, Bahar I et al. (2014):** Comparison between femtosecond laser mushroom configuration and manual trephine straight-edge configuration deep anterior lamellar keratoplasty. *Br J Ophthalmol.*, 98:35–9.
- 22. Li S, Wang T, Bian J et al. (2016):** Precisely controlled side cut in femtosecond laser-assisted deep lamellar keratoplasty for advanced keratoconus. *Cornea*, 35:1289–94.