

## The Blinking Test (Faheem's Approach): A Promising Tool for Assessing Tubal Patency and Blockage

Hossam Faheem<sup>1</sup>, Laila Ezzat<sup>2</sup>, Abdo Elswesy<sup>3</sup>,

Sherif Salah El-Deen Fahmy<sup>4</sup>, Aly Abdel- Bagy Mohamed<sup>4</sup>, Adham Badawy<sup>4</sup>

<sup>1</sup>Department of Gynecology and Obstetrics, Aswan General Hospital, Egypt

<sup>2</sup>Department of Gynecology and Obstetrics, Faculty of Medicine, Fayoum University, Egypt

<sup>3</sup>Department of Gynecology and Obstetrics, Ministry of Health Aswan, Egypt

<sup>4</sup>Department of Gynecology and Obstetrics, Faculty of Medicine, Aswan University, Egypt

\*Corresponding author: Hossam Faheem, Mobile: (+20) 01005818275, E-mail: [dr.hossame@gmail.com](mailto:dr.hossame@gmail.com)

### ABSTRACT

**Background:** There are various diagnostic tests available to determine tubal patency. Laparoscopy with chromopertubation, with or without contemporaneous hysteroscopy, is now the "gold standard" for tubal assessment.

**Objective:** This study aimed to evaluate the specificity and sensitivity of hysteroscopic tubal patency assessment using the tubal ostium movement (blinking test).

**Method:** This cross-sectional study was conducted at Aswan Specialized Hospital, Aswan, Egypt. The study involved 100 infertile patients in the period from Jan 2022 to June 2022. Participants were recruited from the Outpatient population visiting the Gynecological Clinic at ABC Fertility Center. Those who underwent hysteroscopy were further offered laparoscopic chromopertubation to complete the assessment, all within the same setting.

**Results:** The blinking test showed a sensitivity of 82.50% for detecting right tubal patency and 92.31% for detecting left tubal patency, along with a specificity of 100% for both right and left tubal patency. Both the positive predictive value and negative predictive value were 100%. The overall accuracy of the blinking test was 87.27% for right tubal patency and 94.55% for left tubal patency. Furthermore, the blinking test's diagnostic value was supported by the favorable area under the curve (AUC) values, ranging from 0.87 to 0.961 in the ROC curve analysis.

**Conclusion:** The blinking test showed promising results as a diagnostic method for assessing tubal patency in infertile patients. It is a useful tool for assessing tubal factor infertility because of its excellent sensitivity, specificity, positive predictive value, negative predictive value, and accuracy.

**Keywords:** Hysteroscopy, Laparoscopic chromopertubation, Infertility, Tubular patency.

### INTRODUCTION

Infertility is a prevalent concern affecting a significant number of women worldwide. Infertility, as the World Health Organization defines it, is characterized as a condition of the reproductive system in which partners are unable to conceive clinically despite having regular, unprotected sex for at least a year <sup>[1]</sup>. In accordance with this definition, the American Society of Reproductive Medicine suggests that women aged 35 and older should undergo evaluation after 6 months of unsuccessful attempts to conceive <sup>[2]</sup>.

The fallopian tube is a crucial structure connecting the ovary to the uterus, serving as the primary pathway for the transportation of gametes (eggs and sperm) and early-stage embryos. It plays a vital role in providing both mechanical transport and physiological support during reproductive processes. Any damage or impairment to the fallopian tube can disrupt the proper transport of gametes, leading to infertility. Therefore, the evaluation of tubal health is of significant importance in determining a woman's fertility potential <sup>[3]</sup>. When considering a diagnostic test for tubal assessment, it is important to prioritize factors such as cost-effectiveness, minimally invasive nature, and a reasonable balance between sensitivity and specificity <sup>[4]</sup>.

Currently, the "gold standard" for determining tubal patency is laparoscopy with chromopertubation,

with or without concurrent hysteroscopy. However, this technique needs general anesthesia and is invasive <sup>[2]</sup>.

A novel approach involving diagnostic hysteroscopy has been introduced by Dr Faheem, where the manipulation of intrauterine pressure through the use of distention media results in observable movements of the tubal ostium. These movements resemble blinking motions, indicating that the fimbria of the fallopian tube is freely open. This indirect observation can be considered an indication of tubal patency, benefiting the evaluation process.

The goal of this study was to evaluate the efficacy of laparoscopic chromopertubation and hysteroscopic tubal ostium movement (Blinking test produced by Dr Faheem) as infertility diagnostic procedures as well as evaluation of the specificity and sensitivity of hysteroscopic tubal patency assessment.

### MATERIALS AND METHOD

**Study design & participants:** This cross-sectional study was conducted at Aswan Specialized Hospital, Aswan, Egypt. The study involved 100 infertile female patients in the period from Jan 2022 to June 2022. Participants were recruited from the Outpatient population visiting the Gynecological Clinic at Aswan Specialized Hospital.

**Inclusion criteria:** Adult female patients in reproductive age who were diagnosed with primary or secondary infertility and undergoing evaluation for tubal patency.

**Exclusion criteria:** Male factor infertility and uterine factor infertility to focus specifically on cases of tubal factor infertility. Patients who had previously undergone bilateral salpingectomy or tubal ligation as these procedures would affect the assessment of tubal patency. Patients with current vaginal bleeding or gynecological infections to avoid any potential complications or confounding factors.

**Method:** Each participant underwent a comprehensive evaluation, including clinical examination, ultrasound, and laboratory investigations. Subsequently, they were offered an office hysteroscopic examination. Those who underwent hysteroscopy were further offered laparoscopic chromopertubation to complete the assessment, all within the same setting.

**Hysteroscopic examination by Faheem's approach (Blinking test):** On the fifth day following the start of menstruation, a diagnostic hysteroscopy was carried out. We used a rigid hysteroscope with a 2.9-mm diameter, a 30° forward-angled oblique lens, and a 3 mm outer sheath (Karl Storz GmbH, Tuttlingen, Germany). Using a regular saline solution, the uterine cavity was dilated, and the distension medium pressure was kept constant at 80–100 mm Hg. According to Evangelista, the hysteroscopy operation used a no-touch method known as the vaginoscopic approach<sup>[5]</sup>. Starting with the anterior and posterior walls, then moving on to the fundus and borders, the uterine cavity was thoroughly examined. We evaluated the tubal orifices' size and symmetry, any pathologies such as adhesions, polyps, hyperemia, or inflammatory changes at the tubal orifices were documented. Next, the intrauterine pressure was increased to 100 mmHg, and a close-up view of the right ostium was obtained, resembling cornoscopy. The fluid flow was then abruptly stopped, and the movement of the ostium was observed. The negative pressure in the intra-abdominal space allowed for the assessment of tubal patency. The same procedure was repeated for the left side.

**Laparoscopic Chromopertubation:** A laparoscopy procedure was performed on the patient while they were under general anesthesia. The laparoscopy involved using a 10-mm scope (Karl Storz, Tuttlingen, Germany). To facilitate the procedure, two additional 5-mm trocars were inserted in the lower abdomen. The cervix was dilated to Hegar 5, and a uterine manipulator known as the Cooper Surgical Rumi was carefully positioned. The uterine manipulator was connected to a syringe containing a solution of 20 ml of saline mixed with blue methylene dye.

A comprehensive evaluation was conducted, thoroughly examining the uterus, fallopian tubes, ovaries, and nearby organs for any signs of abnormalities, such as endometriosis, fibroids, or

adhesions. The assistant administered the methylene blue dye, and the subsequent flow of the dye through the fallopian tubes was carefully observed. To eliminate the methylene blue dye from the peritoneal cavity, a suction and irrigation cannula was inserted through the suprapubic port. Subsequently, the gas present in the peritoneal cavity was expelled, and the incision sites for the ports were sutured. Finally, the uterine cannula was extracted.

**Outcome measures:** The outcome measures for the study included the primary outcome of assessing the sensitivity and specificity of hysteroscopic tubal patency assessment using the tubal ostium movement (blinking test) compared to laparoscopic chromopertubation. The secondary outcomes looked at the overall accuracy, positive predictive value, and negative predictive value of the blinking test for tubal patency. The blinking test's sensitivity and specificity for bilateral tubal patency, bilateral tube obstruction, and unilateral patent tube were also assessed in the study. Also examined was the receiver operating characteristic (ROC) curve's area under the curve (AUC) for the blinking test's ability to identify tubal patency. The diagnostic performance and precision of the blinking test in diagnosing tubal patency and obstruction were evaluated using these outcome metrics.

**Sample size:** We calculated the sample size based on a prospective cohort study<sup>[6]</sup>. The study results showed that sensitivity for hysteroscopic flow effect was 85.3% and the specificity was 66.1% using laparoscopy finding as reference, we calculate the sample size with 80% power and a significance level of 0.05. 100 patients were found to be enough to detect 70% sensitivity and 83% specificity of diagnostic hysteroscopy.

**Ethical consideration:** Aswan Specialty Hospital and The ABC Center's Institutional Review Board granted the study ethical approval. Informed consent was obtained from each participant before their inclusion in the study. Confidentiality of patient information was strictly maintained throughout the research process. The Helsinki Declaration was adhered to at every stage of the investigation.

#### *Statistical analysis*

The obtained data were analyzed using Stata version 17 software to determine the diagnostic accuracy of the blinking test compared to laparoscopy. Both the right and left tubal patency's sensitivity, specificity, positive predictive value, negative predictive value, and total accuracy were computed. The agreement between the blinking test and laparoscopy for bilateral and unilateral tubal status was further examined. ROC curve analysis was performed to examine the diagnostic performance of the blinking test, and the AUC values were calculated for each category of tubal status.

**RESULTS**

100 patients were included in the study, with 67 (67 %) of them experiencing primary infertility and 33 (33%) having secondary infertility. The mean duration of infertility was  $3.47 \pm 1.32$  years. The average age of the participants was  $32.34 \pm 3.55$  years as presented in table 1.

**Table (1):** Baseline characteristics of the patients

Characteristics	Studied patients
Age, mean (SD), (years)	32.34 ( $\pm$ 3.55)
BMI, mean (SD),	28.69 ( $\pm$ 4.58)
History of previous cesarean section hysterotomy	20 (20%) CI 11.28%-32.94%
History of instrumental abortion	12 (12%) CI 6.08%-24.71%
Primary or secondary infertility	Primary: 67 (67 %) CI 53.60%-78.53% Secondary: 33 (33%) CI 21.47%-46.40%
Duration of infertility	3.47 ( $\pm$ 1.32)

Among the 72 (72 %) cases that were found to have right tubal patency during laparoscopy, 60 (60%) of them also showed right tubal patency through hysteroscopic tubal ostium movement (blinking test). In 70 (70%) cases, laparoscopy indicated left tubal patency, while the blinking test showed left tubal patency in 65 (65%) cases, as presented in table (2).

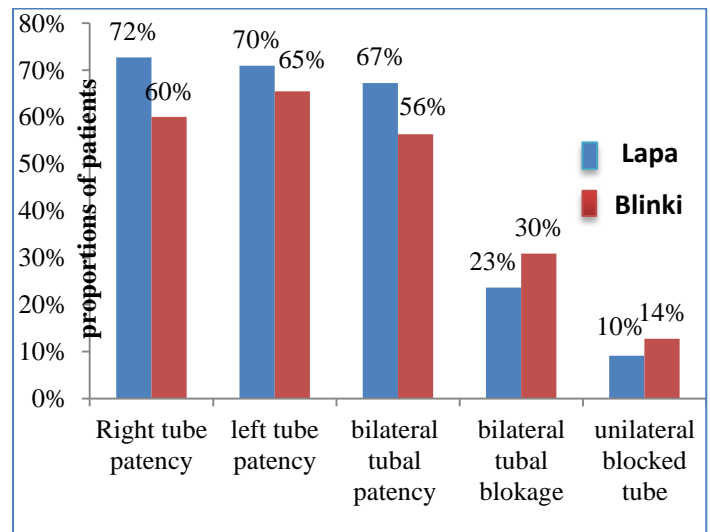
**Table (2):** Tubal Status as detected by Laparoscopy and hysteroscopic tubal ostium movement (blinking test)

Characteristics	Tubal patency by Laparoscopy (Number of patients)	Tubal patency by Blinking test (Number of patients)
Right tubal patency	72 (72%)	60 (60%)
Left tubal patency	70 (70%)	65 (65%)
Bilateral patent tubes	67 (67%)	56 (56%)
Bilateral tube blockage	23 (23%)	30 (30%)
Unilateral blocked tube	10 (10%)	14 (14%)

The blinking test exhibited a sensitivity of 82.50% and a specificity of 100% in detecting right tubal patency. Both the positive predictive value and negative predictive value were 100%. However, false-negative results were observed in 17.50% of cases, resulting in an overall accuracy of 87.27%. For left

tubal patency, the blinking test demonstrated a sensitivity of 92.31% and a specificity of 100%. The positive predictive value and negative predictive value were both 100%. False-negative results were observed in 7.69% of cases, and the accuracy of the blink test for left tubal patency was 94.55%, as presented in table (3).

Among the 67 (67%) cases identified with bilateral patent tubes during laparoscopy, 56 (56%) cases were also found to have bilateral patent tubes through the blinking test. Among the 30 (30%) cases diagnosed with bilateral blocked tubes using the blinking test, 23 (23%) cases were confirmed to have bilateral blocked tubes during laparoscopy. Furthermore, among the 14 (14%) cases that exhibited unilateral tubal blockage according to the blinking test, only 10 (10%) cases were found to have unilateral tubal blockage through laparoscopy. These findings are presented in figure (1).



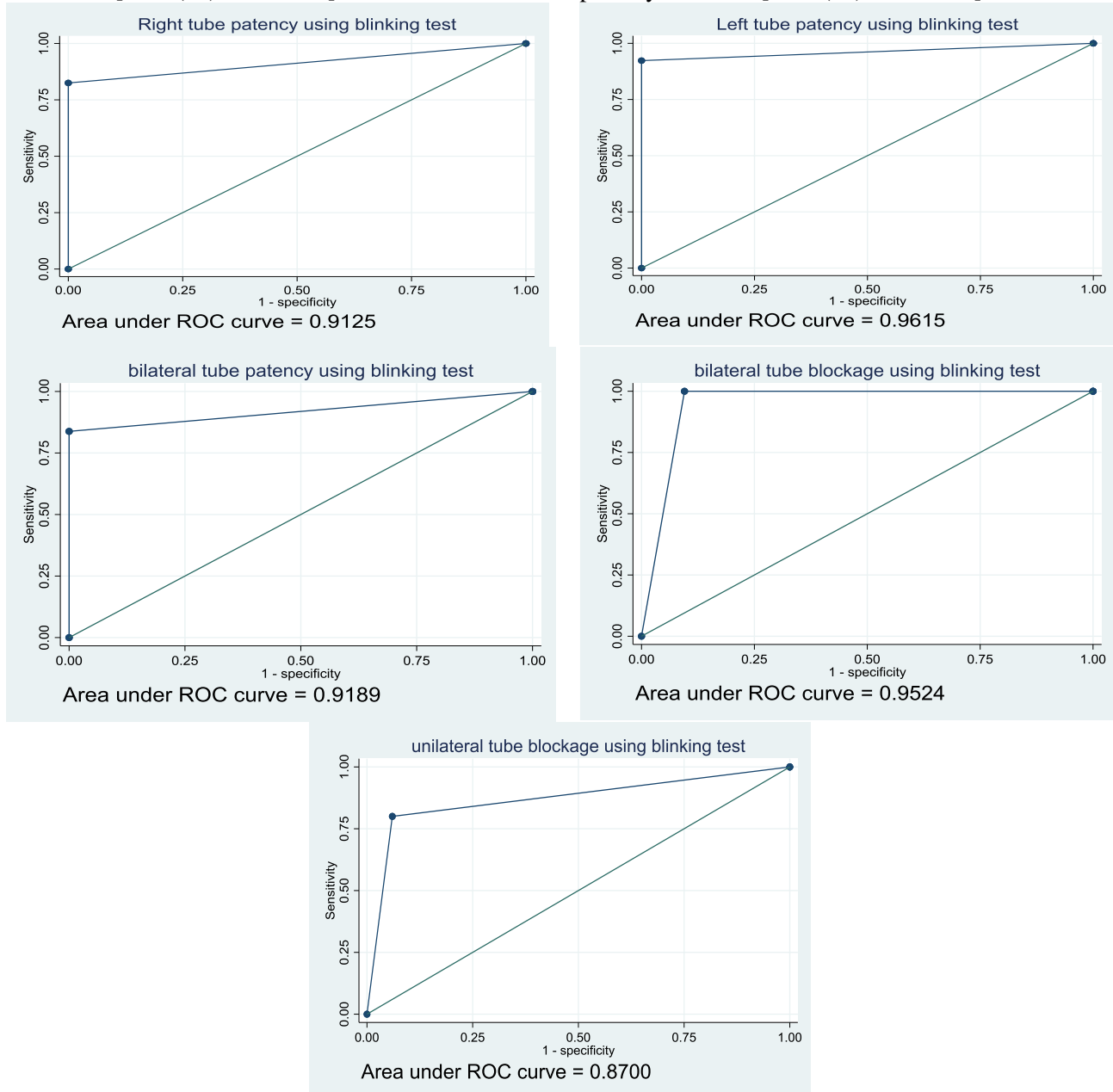
**Figure (1):** Tubal status as detected by laparoscopy and blinking test.

The blinking test exhibited a sensitivity of 83.78% and a specificity of 100% in detecting bilateral tubal patency. The positive predictive value was 100% and the negative predictive value was 73.91%, resulting in an accuracy of 88.89%. For the identification of bilateral blocked tubes, the blinking test demonstrated a sensitivity of 100% and a specificity of 90.48%. The positive predictive value and negative predictive value were 76.47% and 100% respectively leading to an accuracy of 92.73%. In the case of unilateral patent tubes, the blinking test showed a sensitivity of 80% and a specificity of 94%. The positive predictive value and negative predictive value were 57.14% and 97.92% respectively with an accuracy of 92.73%, as depicted in table (3).

**Table (3):** Sensitivity, specificity and diagnostic value of hysteroscopic tubal ostium movement (Blinking test) compared to gold standard laparoscopy

Characteristics	Sensitivity of blinking test (95% CI)	Specificity of blinking test (95% CI)	Positive predictive value (95% CI)	negative predictive value (95% CI)	Accuracy (95% CI)
Right tubal patency	<b>82.50%</b> (72.46 -92.54%)	<b>100%</b> (100 - 100%)	<b>100%</b> (100- 100%)	<b>68.18%</b> (55.87-80.49%)	<b>87.27%</b> (75.52- 94.73%)
Left tubal patency	<b>92.31%</b> (85.27-99.35%)	<b>100%</b> (100 - 100%)	<b>100%</b> (100 - 100%)	<b>84.21%</b> (74.57-93.85%)	<b>94.55%</b> (84.88- 98.86%)
Bilateral patent tube	<b>83.78%</b> (73.95-93.61%)	<b>100%</b> (100 - 100%)	<b>100%</b> (100 - 100%)	<b>73.91%</b> 62.20% 85.62%	<b>88.89%</b> (77.37% -95.81%)
Bilateral tube blockage	<b>100%</b> (100-100%)	<b>90.48%</b> (82.72-98.23%)	<b>76.47%</b> (65.26-87.68%)	<b>100%</b> (100% - 100%)	<b>92.73%</b> (82.41-97.98%)
Unilateral patent tube	<b>80%</b> (69.43-90.57%)	<b>94%</b> (87.72-100.28%)	<b>57.14%</b> (44.06-70.22%)	<b>97.92%</b> (94.14-101.69%)	<b>92.73%</b> (82.41-97.98%)

**ROC curve analysis:** Receiver operating characteristics curve analysis showed that an area under the curve of the blinking test for right tubal patency detection was 0.912 [95% (CI): 0.80-0.97], and for left tubal patency was 0.961 [95% (CI): 0.87-0.99]. The AUC for bilateral tubal patency was 0.919 [95% (CI): 0.82-0.98], for bilateral tube blockage was 0.952 [95% (CI): 0.85-0.99] and for unilateral tubal patency was 0.87 [95% (CI): 0.75-0.95] as shown in figure (2).



**Figure (2):** The ROC curve for diagnosis of fallopian tube patency with hysteroscopic tubal ostium movement (blinking test) employing laparoscopy as the gold standard for diagnosis.

## DISCUSSION

The aim of this study was to evaluate the specificity and sensitivity of hysteroscopic tubal patency assessment using the tubal ostium movement (Blinking test). The findings on the diagnostic use of the blinking test in identifying tubal patency and blockage were encouraging.

The blinking test demonstrated a sensitivity of 82.50% for detecting right tubal patency and 92.31% for detecting left tubal patency. According to these results, the blinking test provided a high degree of accuracy in identifying people with patent fallopian tubes. The high sensitivity implies that the blinking test has a low rate of false negatives, meaning it accurately detects cases where the fallopian tubes are open. This is essential for assessing infertility since precise tubal patency determination can impact therapy selections.

The specificity of the blinking test was 100% for both right and left tubal patency, indicating its ability to correctly identify cases with tubal blockage. A high specificity indicates that the blinking test detects fallopian tube blockages with a low risk of false positives. This is vital to protect patients with tubal obstruction from inappropriate interventions or therapies.

The positive predictive value of the blinking test was 100% for both right and left tubal patency, indicating that a positive result from the test is highly reliable in confirming tubal patency. The negative predictive value was also high, with values of 68.18% for right tubal patency and 84.21% for left tubal patency. This means that a negative response from the blinking test is highly certain evidence of tubal obstruction.

The overall accuracy of the blinking test was 87.27% for right tubal patency and 94.55% for left tubal patency. According to these results, the blinking test may be a reliable diagnostic method for determining tubal patency. The high accuracy is essential for clinicians in making informed decisions about the appropriate treatment options for infertile women.

When comparing the results of the blinking test to the gold standard laparoscopic chromopertubation, the blinking test showed similar sensitivity, specificity, and accuracy. This suggests that the blinking test can be a valuable easy alternative to laparoscopy in examining tubal patency. The blinking test offers patients a less invasive and more affordable choice in addition to offering accurate results.

The ROC curve analysis further supported the diagnostic usefulness of the blinking test. The AUC values ranged from 0.87 to 0.961, indicating good to excellent results of the blinking test in defining differences between tubal patency and blockage. These values suggest that the blinking test has a high discriminatory power and can be considered a reliable diagnostic tool. There are several diagnostic tests

available for assessing tubal patency. Laparoscopy with chromopertubation, with or without concurrent hysteroscopy, is currently the "gold standard" in tubal evaluation. However, this method is invasive and requires general anesthesia<sup>[7,8]</sup>.

Other diagnostic tests include hysterosalpingography (HSG), transvaginal ultrasound (TVS), and hysteroscopy. HSG is a reference standard for evaluating the condition of the fallopian tubes and tubal disorders such as salpingitis isthmica nodosa, hydrosalpinx, and tubal blockage<sup>[3]</sup>. TVS is a non-invasive technique that evaluates tubal patency by looking for fluid in the tubes<sup>[9]</sup>. Hysteroscopy is another minimally invasive method that can be used to examine tubal patency by visualizing the ostia of the fallopian tubes<sup>[6]</sup>. The sensitivity and specificity of these diagnostic tests vary depending on the method used. For example, HSG has a sensitivity of 65-90% and a specificity of 75-95%<sup>[3]</sup>. TVS has a sensitivity of 50-80% and a specificity of 80-90%<sup>[9]</sup>.

Furthermore, **Promberger et al.**<sup>[10]</sup> conducted a retrospective cohort study aimed at determining if the detection of a visible "flow" effect in the fallopian tube ostia during routine hysteroscopic examination could be used as a prognostic tool for tube patency. The study found that the hysteroscopic assessment of fallopian tube "flow" demonstrated a high level of accuracy in predicting fallopian tube patency ( $p < 0.001$ ) with a sensitivity of 86.4% and a specificity of 77.6%.

In another investigation, researchers conducted a prospective cohort study to examine whether the observation of a visible "flow" effect in the fallopian tube ostia during hysteroscopy could serve as an indicator of tubal patency. The study involved 72 infertile women who underwent surgical intervention for infertility. The primary outcome measured was the evaluation of fallopian tube patency through laparoscopic chromopertubation. The results revealed that out of the 144 assessed fallopian tubes, 61.1% were determined to be patent. The presence of a positive hysteroscopic flow effect was documented in 65.3% ostia and exhibited a high level of accuracy in predicting tubal patency ( $p < 0.001$ ). The sensitivity of the hysteroscopic assessment was found to be 85.3% with a specificity of 66.1%<sup>[6,11]</sup>.

Furthermore, in a randomized comparison between the flow technique and the Paryscope technique, it was observed that hysteroscopic prediction of fallopian tube patency showed statistical significance in both study groups ( $p < 0.05$ ). The Paryscope technique displayed superior sensitivity of 90.6% and specificity of 100% when compared to the flow technique, which exhibited a sensitivity of 73.7% and specificity of 70.7%<sup>[12]</sup>.

Overall, the blinking test showed encouraging outcomes in identifying tubal patency and blockage when compared to other diagnostic procedures. Studies on the hysteroscopic flow effect and Paryscope

approach further emphasize the diagnostic value of hysteroscopic prediction of tubal patency. Other diagnostic procedures like HSG, TVS, and hysteroscopy have different sensitivity and specificity. The findings of our study had important clinical importance. In some instances, the blinking test can be utilized to determine tubal patency without the requirement for invasive laparoscopic procedures. When determining the best course of therapy for infertile patients, such as between surgical treatments or assisted reproductive techniques, it can offer useful guidance. Furthermore, the blinking test can be easily performed in an outpatient clinic, making it more accessible and cost-effective.

**Limitations:** Firstly, the sample size was relatively small, which may affect the generalizability of the findings. It is necessary to conduct additional research with larger sample sizes to verify the findings. This study also excluded other causes of infertility and only examined infertility due to tubal factors. Therefore, the findings may not be applicable to cases with male factor infertility.

## CONCLUSION

The blinking test showed promising results as a reliable diagnostic method for assessing tubal patency in infertile patients. Its high sensitivity, specificity, positive predictive value, negative predictive value, and accuracy make it a valuable tool in the evaluation of tubal factor infertility. Further research and larger studies are warranted to validate these findings and establish the blinking test as a routine diagnostic approach in infertility clinics.

**Conflict of interest:** none declared.

**Fund:** non-fundable.

## REFERENCES

1. **Zegers-Hochschild F, Adamson G, de Mouzon J et al. (2009):** The international committee for monitoring assisted reproductive technology (ICMART) and the world health organization (WHO) revised glossary on

- ART terminology, 2009. Human Reproduction, 24 (11): 2683-2687.
2. **Practice Committee of the American Society for Reproductive Medicine (2015):** Diagnostic evaluation of the infertile female: a committee opinion. Fertil Steril., 103(6): 44-50.
  3. **Masaba E (2020):** Assessment of Tubal Patency. Textbook of Assisted Reproduction, Pp: 3-6. DOI:10.1007/978-981-15-2377-9\_1
  4. **Penzias A, Azziz R, Bendikson K et al. (2021):** Fertility evaluation of infertile women: a committee opinion. Fertility and Sterility, 116 (5): 1255-1265.
  5. **Evangelista A, Oliveira M, Crispi C et al. (2011):** Diagnostic hysteroscopy using liquid distention medium: comparison of pain with warmed saline solution vs room-temperature saline solution. Journal of Minimally Invasive Gynecology, 18 (1): 104-107.
  6. **Ott J, Hager M, Nouri K et al. (2020):** Assessment of Tubal Patency: A Prospective Comparison of Diagnostic Hysteroscopy and Laparoscopic Chromopertubation. J Minim Invasive Gynecol., 27 (1): 135-140.
  7. **Vitale S, Carugno J, Riemma G et al. (2021):** Hysteroscopy for assessing fallopian tubal obstruction: a systematic review and diagnostic test accuracy meta-analysis. Journal of Minimally Invasive Gynecology, 28 (4): 769-778.
  8. **Hager M, Simek I, Promberger R et al. (2019):** The role of diagnostic hysteroscopy in the evaluation of Fallopian tube patency: a short review. Geburtshilfe und Frauenheilkunde, 79 (05): 483-486.
  9. **Grigovich M, Kacharia V, Bharwani N et al. (2021):** Evaluating fallopian tube patency: what the radiologist needs to know. Radiographics, 41 (6): 1876-18961.
  10. **Promberger R, Simek I, Nouri K et al. (2018):** Accuracy of Tubal Patency Assessment in Diagnostic Hysteroscopy Compared with Laparoscopy in Infertile Women: A Retrospective Cohort Study. J Minim Invasive Gynecol., 25 (5): 794-799.
  11. **Yucel B, Demirel E, Kelekci S et al. (2018):** Accuracy of a new hysteroscopic method in the assessment of tubal patency: Hysteroscopic chromotubation. Gynecol Obstet Reprod Med., 24: 82-86.
  12. **Hager M, Ott J, Holzer I et al. (2020):** Hysteroscopic Assessment of Tubal Patency: A Randomized Comparison between the Flow and Parryscope Techniques. J Minim Invasive Gynecol., 27 (7): 1552-1557.