

## Nanofat for Infraorbital Rejuvenation: A Clinical and Dermoscopic Evaluation

Maryam Mohammed El-Hoseini\*<sup>1</sup>, Sara Hamdy Fouad<sup>1</sup>, Ahmed Mahmoud Zeina<sup>2</sup>, Manar Elsayed Sallam<sup>1</sup>

Departments of <sup>1</sup>Dermatology, Andrology and STDs,

<sup>2</sup>Plastic Surgery, Faculty of Medicine, Mansoura University, Egypt

\*Corresponding author: Maryam Mohammed El-Hoseini, Mobile: (+20) 01092687895, Email: m.elmansy0891@gmail.com

### ABSTRACT

**Background:** Infra-orbital dark circles (IDC) can affect people of different ages, all races and both genders. Nanofat injection is a quite popular modality in tissue reconstruction.

**Objective:** To assess the clinical effectiveness, safety and potential side effects of nanofat injection for infraorbital rejuvenation. **Patients and Methods:** The study included 30 subjects with IDC and/or tear trough deformity (TTD). They were injected with nanofat and followed up for 3 months. The clinical assessment included the grade of infraorbital hyperpigmentation, tear trough rating scale (TTRS), global evaluation of the improvement degree, and the improvement degree of skin texture and homogeneity. Dermoscopy of infra-orbital region were performed for IDC classification.

**Results:** IDC were significantly improved in 60% of the subjects. Regarding satisfaction, 15 subjects (50%) were highly satisfied, 9 subjects (30%) were satisfied and 6 subjects (20%) showed slight satisfaction.

**Conclusion:** Nanofat injection is beneficial for skin rejuvenation and per the post-operative skin texture changes. No contour irregularities or lumps were observed at three months of follow-up. Nanofat injection is safe and easy, with low tissue morbidity, making it a novel treatment modality for facial rejuvenation and restoration.

**Keywords:** Infra-orbital dark circles, Tear trough rating scale, Dermoscopic evaluation, Clinical assessment.

### INTRODUCTION

IDC refer to the darkness of the infra-orbital area below the lower eyelid. TTD applies to the infra-orbital hollow that extends inferolaterally from the medial canthus. IDC and TTD are sometimes accompanied by significant cosmetic concerns as they give a fatigued appearance and a more aging look <sup>(1,2)</sup>.

Non-surgical options such as topical agents, chemical peeling, dermal filler, autologous fat transfer, botulinum toxin, radiofrequency, and laser therapy had been used for improving and rejuvenating the infra-orbital region as they activate dermal collagen remodeling and tissue augmentation. Nonetheless, treatment of these conditions is often lengthy, so the patient and his physician should plan the appropriate treatment course to accomplish the favorite outcomes <sup>(1)</sup>.

IDC have multifactorial causes that include genetics, sun exposure, smoking, alcohol consumption, sleep disturbances, hormonal causes and extension of pigmentary demarcation lines <sup>(2)</sup>.

Another common cause is the translucent lower lid skin that overlies orbicularis oculi with the prominence of subcutaneous vessel plexus <sup>(3)</sup>.

In the previous decade, nanofat injection has been used for tissue reconstruction and augmentation. It is available, not expensive, not rejected, and does not cause allergy <sup>(1)</sup>.

In 2013, **Tonnard et al.** <sup>(4)</sup> used the nanofat to treat skin aging and it was found to be more effective and safer when compared to traditional fat grafting, which acts mainly via producing a physical volume effect. On the other hand, nanofat injection acts mainly through promotion of skin rejuvenation <sup>(2)</sup>.

So, this study aimed to evaluate the clinical efficiency, safety, and potential side effects of PPP gel vs. nanofat grafting for infraorbital rejuvenation.

### PATIENTS AND METHODS

This prospective case-control study was performed at Dermatology, Andrology and Sexually-Transmitted Diseases Department of Mansoura University Hospitals. A total of 30 cases with IDC and/or tear tough deformity were injected with nanofat. They were followed up for 3 months post-injection to evaluate the efficacy of the treatment regimen. This study was made along the period from September, 2022 to September, 2023. Thirty females aged between 18 and 65 years with IDC and/or TTD were included. Exclusion criteria included pregnancy, breastfeeding, procoagulative or thrombophilic conditions, bleeding/clotting disorders, infectious disorders, subjects on steroids, chronic disorders e.g., renal failure, liver failure/hepatitis, cardiovascular disease, diabetes, thyroid disorder, malignancy, etc., and subjects with dark circles with extended pigmentary demarcation lines.

### METHOD

The diagnosis of periorbital hyperpigmentation, via history and examination was important to recognize any etiological factor. All subjects were subjected to history taking such as (age, gender, occupation, family history, comorbidities, disease duration, duration of sun exposure, hours of sleep, hours of exposure to computer screen, faulty habits or lifestyles, cosmetic use, frequent eye rubbing, prior use of any topical medication (eye drops and ointment), history of atopy or drug administration, current treatment, blurring of vision, headache, mental stress, precipitating factors including photosensitivity, allergy, seasonal variation, presence of other pigmentations on face or on body, and presence of pre-existing diseases e.g. anemia, gut disease, liver disease, kidney disease, and thyroid disease).

Complete general and dermatological examination included physical evaluation to detect the involvement of upper lid, lower lid or both lids and extension beyond

the peri-orbital region, color of pigmentation (light brown/dark brown/reddish/bluish), presence of any peri-orbital skin disease or scars, presence of any visible bulging, shadowing effect, prominent subcutaneous vascular plexus in the infra-orbital region, pale palpebral conjunctiva, pale nails, and pale palms, and presence of hyperpigmentation in other facial areas, e.g., melasma or freckles. The lid stretch test was performed to distinguish true pigmentation from shadow effect. The lower eyelid was manually stretched to note the visible change in pigment intensity.

### Clinical Assessment

The clinical assessment included the grade of infraorbital pigmentation<sup>(5)</sup>, TTRS<sup>(6)</sup>, global assessment for improvement<sup>(7)</sup>, the improvement degree in texture and homogeneity of skin<sup>(8)</sup>, **Doghaim et al.**<sup>(7)</sup> used a 5-grade scale to describe the percent of change in skin smoothness and color uniformity, and patients' satisfaction was assessed on a quartile scale. Post-operative adverse events such as ecchymosis, pain, oedema, and erythema were assessed in follow-up visits. Serious complications like infections, fatty lumps and granulomas were also noted.

### Dermoscopic Assessment

Dermoscopy of the infra-orbital region was performed for IDC classification as follows: (a) pigmented IDC (whether epidermal "homogenous and cobble stone type" or dermal "hyperpigmented blotch, hyperpigmented globule or exaggerated hyperpigmented network), (b) vascular IDC (diffuse erythema, multiple thin vessels or diffuse vessel network), or (c) mixed IDC (both hyperpigmentation and vasculature).

### Nanofat Procedure

Donor site was selected depending upon fat distribution and preference of the patient. Excess fatty tissue from the lower abdomen or hip was generally selected as a donor site. After prep, a shallow-depth injection of 1 ml lidocaine 2% with a fine needle of 27-gauge was performed by a scalpel no. 11 at the entrance points of the cannula. Then, fat (about 10 ml) was harvested with about 250 cc tumescent solution including (1000 ml of ringer solution, adrenaline 1 mg/ml, and 30 ml lidocaine (not exceeds 35 mg/kg)). Tumescent solution was injected by lipofilling cannula. Fat was collected in accordance with the Coleman method. Fat underwent aspiration with a 10-ml Luer lock syringe and 2 mm liposuction cannula. Then it was transferred into 10 ml syringes and then centrifugation was done at 3000 rpm for 1 minute to concentrate the fat particles and separate them from fluids and debris and was then transferred to 1 ml insulin syringes. Following centrifugation, mechanical emulsification of lipoaspirate was done through shifting the fat between two syringes (10 ml each) connected together by a nanofat connector.

After about thirty passes, the lipoaspirate was emulsified. Finally, the fat became liquid and was white

in color. A 1 mm lipo-injection cannula with 1 ml insulin syringe was utilized for superficial nanofat injection intradermally and subdermally. The appearance of yellow color of patient's skin during injection was the endpoint for nanofat procedure.

The yellowish discoloration disappeared rapidly post-injection (within few hours). Nerve block was done by using topical lidocaine cream before the injection. Small fat droplets underwent injection under both eyes between the skin and muscle layer. If the TTD was prominent, some fat underwent injection above the infra-orbital bony margin. An average fat volume of 1–2 cm<sup>3</sup>, depending upon the degree of depression, was injected in bilateral infra-orbital areas. After the end of procedure, gentle massage was performed for optimum nano-fat distribution. Finally, topical antibiotic ointment (tetracycline 3%) was applied and covered by a dressing. Post-operative care included ice pack application over the injected areas. The patient was advised not to apply pressure or friction to minimize fat displacement and to avoid excessive heat. The patient was prescribed antibiotics for one-week, anti-edematous agents and analgesic drugs. Then, the patient was evaluated 1-week post-operatively, one fat injection was performed, and the patient was examined 3 months from the last treatment.

### Ethical approval:

**Mansoura Medical Ethics Committee of the Mansoura Faculty of Medicine approved this study. Each patient was instructed about the purpose of study, therapeutic options and potential adverse effects, then signed a written consent. The Helsinki Declaration was observed throughout the study's duration.**

### Statistical analysis

Data were analysed by SPSS program V 20.0. Qualitative data were presented as number and percent. Quantitative data were tested for normality by Kolmogorov-Smirnov test then described as Mean±Standard deviation, and range because the data were normally distributed.

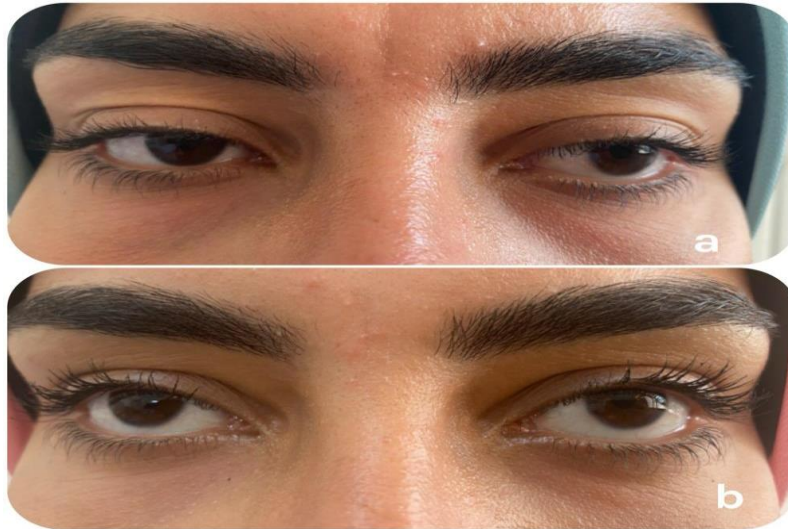### RESULTS

Thirty female patients were treated with autologous subdermal nanofat injection for IDC of various causes. The mean age was 32.83±6.77 years (Range=16-65 years). Positive family history was found in 30% of cases. For tear trough distribution, 40% of the patients were with mild tear through. At the end of follow-up, 10% patients were significantly improved not only in their TTD, but also in the associated IDC and rhytides (if present). The clinical improvement was excellent in 60% of the patients. As regards the improvement of periorbital skin texture and homogeneity, excellent texture homogeneity was detected among 70% of patients and good improvement also detected among 30 % of patients. As regards patient satisfaction, 50% were highly satisfied (Table 1).

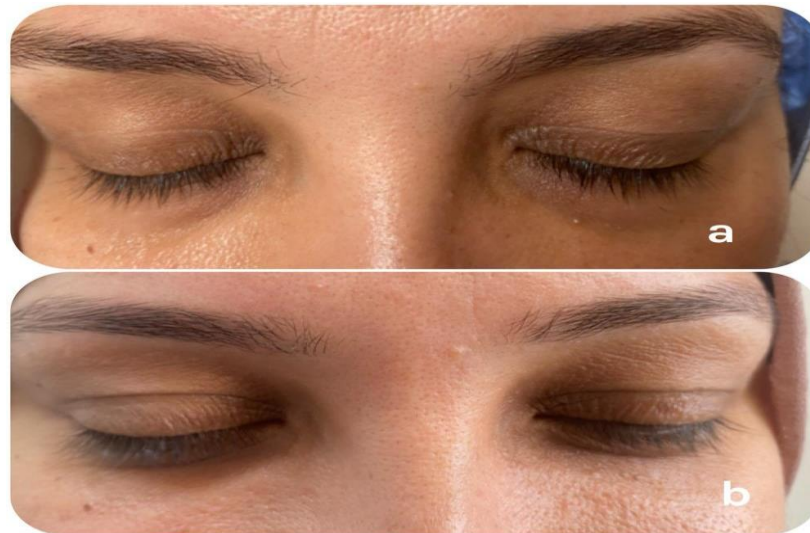**Table (1):** Demographics and clinical data of the patients

	<b>Studied patients N=30(%)</b>
<b>Demographic data</b>	
Age/ years	32.83±6.77
<b>Family history of dark circles</b>	
-ve	21(70.0%)
+ve	9(30.0%)
<b>Type of dark circles</b>	
Vascular	6(20.0%)
Pigmented	12(40.0%)
Mixed	12(40.0%)
<b>Skin type</b>	
II	15(50.0%)
III	12(40.0%)
IV	3(10.0%)
<b>Tear through</b>	
No	3(10.0%)
Mild	12(40%)
Moderate	9(30.0%)
Severe	6(20%)
<b>Degree of clinical improvement</b>	
No	0
Fair	3(10.0%)
Good	9(30.0%)
Excellent	18(60.0%)
<b>Clinical assessment</b>	
<b>Pain</b>	
No	24(80.0%)
Mild	6(20.0%)
Moderate	0
<b>Oedema and ecchymosis</b>	
No	6(20.0%)
Mild	15(50.0%)
Moderate	9(30.0%)
<b>Texture and homogeneity</b>	
Slightly improved	0
Improved	0
Greatly improved	0
Good	9(30.0%)
Excellent	21(70.0%)
<b>Patient satisfaction</b>	
Not satisfied	0
Slightly satisfied	6(20.0%)
Satisfied	9(30.0%)
Highly satisfied	15(50.0%)

Figures (1, 2) show some results of nanofat technique.

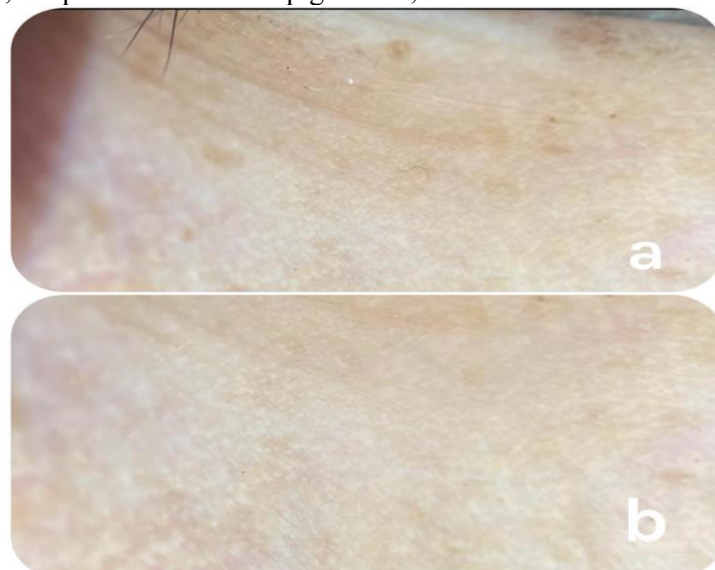


**Figure (1):** A 29-year-old female with TTD. (a) pre-treatment with nanofat. (b) at 3 months follow-up, both sides were greatly improved.



**Figure (2):** A 42-year-old female with TTD. (a) pre-treatment with nanofat. (b) at 3 months follow-up, the right side showed good improvement and the left side showed great improvement.

For dermoscopic assessment, the patients were 40% pigmented, 40% mixed and 20% vascular as in Figure (3).



**Figure (3):** Dermoscopic images of IDC (pigmented type). (a) left side pre-treatment. (b) good improvement at left side after nanofat injection

## DISCUSSION

IDC can affect people of different ages, all races and both genders. Although they are not associated with significant morbidity, IDC are sometimes accompanied by significant cosmetic concerns and thus can negatively affect individual's well-being<sup>(9)</sup>. The appropriate treatment of IDC depends upon their cause. Many topical lightening agents are utilized to treat hyperpigmentation. These include hydroquinone, retinoic acid, mequinol, and steroids. These agents are sometimes used in combinations to increase the efficacy and reduce adverse effects<sup>(10)</sup>. Our study evaluated the clinical effectiveness, safety and potential side effects of nanofat injection for infraorbital rejuvenation.

Thirty patients with IDC and/or TTD were injected with nanofat. Regarding sex, all the studied patients were females, which was in agreement with **Khlosy and Abouarab**<sup>(9)</sup>, and half of them aged between 30 and 40 years. These findings can be explained by the fact that women seek treatment of IDC more than men particularly in this age group.

Regarding tear through distribution, the current study showed for nanofat patients; 40% mild tear through, 30% moderate and 20% severe tear trough, 10% no tear trough. In terms of the dermoscopic diagnosis of the infraorbital dark circles, the present study revealed 40% pigmented, 40% mixed and 20% vascular. Also, regarding the clinical improvement, the nanofat treatment was associated with improvement of IDC.

In terms of nanofat, **Khlosy and Abouarab**<sup>(9)</sup> conducted their nanofat grafting on ten females with IDC. The nanofat was injected intradermal and subdermal. They revealed excellent improvement in five females and moderate improvement in two females, while two females showed mild improvement and only one female was not improved.

Also, **Roh and Chung**<sup>(11)</sup> treated 10 cases with IDC using at least one autologous fat transplantation. The latter was found to be effective for treating IDC because of thin and translucent skin of the lower lid.

In addition, **Akbari et al.**<sup>(12)</sup> found that nanofat grafting was associated with a significant reduction in the volume, area, depth, and percentage area of wrinkles at seven months of follow-up without significant long-lasting side effects. Furthermore, wrinkles with higher percentage area, depth and volume loss showed better improvement. **Tonnard et al.'s study**<sup>(4)</sup> stated that mechanically-processed fat completely disrupted the adipose tissue structure and produced nanofat with more regular and finer particles as compared to micro-fat. They used 27G needle to nanofat injection. Nanofat grafting often does not cause a prominent volume-adding effect. Instead, the main effect of nanofat grafting is related to stem cell activity.

**Oh et al.**<sup>(13)</sup> used a 20G cannula for the subdermal injection of the nanofat in combination with micro-fat grafting. **Khlosy and Abouarab**<sup>(9)</sup> used a 27G needle mounted on 1 ml syringe to inject the nanofat in their

first 5 patients, however sometimes; resistance during injection hindered the use of the technique. Besides, disconnection between the needle and syringe had led to spoilage of nanofat making the injection difficult. Another issue they faced was the short needle length, which necessitated multiple punctures; as a result, they used a long and thin 27G needle mounted on a metal dental syringe (which is utilized for dental anaesthesia) in the other 5 patients (50%). This was associated with a decrease of post-operative oedema and ecchymosis in such patients.

These results were explained by the fact that nanofat contains stromal vascular fraction and adipose-derived stem cells (ASC). The ASC produces large amounts of type I collagen, small amounts of collagen types V and VI and proteins, regenerates fibroblasts, and release higher amounts of cell matrix, all helps repair skin breaks and reconstruct skin structure, leading to wrinkle improvement<sup>(14)</sup>. Nanofat has been associated with elasticity improvement, due to the enhanced production of collagen and elastin, together with remodeling, which are triggered by stem cells of adipocytes that are destroyed during emulsification<sup>(15)</sup>.

With regard to the texture and homogeneity, a significant improvement was noticed after nanofat injection. This was in agreement with **Khlosy and Abouarab**<sup>(9)</sup> who have displayed that nanofat injection significantly improved the skin texture and homogeneity. Also, **Menkes et al.**<sup>(16)</sup> revealed that all their studied patients confirmed an improved skin quality following nanofat administration. In addition, a lifting effect was reported. Notably, nanofat grafting does not damage cells, and maintains cell viability. Biopsies demonstrated the increase in dermal cellularity, vascular density, as well as increased elastic and collagen fibers.

As regards satisfaction, the current study demonstrated that; nanofat patients were associated with a significant increase in satisfaction. Also, in terms of nanofat, **Khlosy and Abouarab**<sup>(9)</sup> have demonstrated that 8 patients (80%) were satisfied, while 2 cases (20%) were not. In addition, **Guo et al.**<sup>(17)</sup> conducted their study on 107 cases with depressions in the sub-orbital area and facial asymmetry, necessitating fat injection. All cases were followed for 6 - 24 months, 67.3% of cases rated the results as "very satisfied", 29.0% rated as "satisfied", 3.7% rated as "average", and none of cases rated as "not-satisfied". In contrast, **Xiao et al.**<sup>(18)</sup> found that nano fat grafting for superficial rhytids achieved high satisfactory rate (> 80%) among both physicians and patients; however, some cases were unsatisfied.

Similarly, **Fakih-Gomez et al.**<sup>(15)</sup> treated 20 females by intradermal nanofat injection to evaluate its effect on skin smoothness, pores, wrinkle, and hyperpigmentation. Though all females reported satisfaction with the rejuvenative effect of nanofat injection, 40% of females noticed wrinkles' improvement.

With regard to post-operative adverse events, our study demonstrated that there was a mild pain in the studied cases (80% no pain, 20% mild pain). In addition, there was mild oedema and ecchymosis.

The complications of lipofilling can include bruises, swelling, pain, infections, necrotic changes, as well as calcifications. **Khlosy and Abouarab** <sup>(9)</sup> revealed that post-operative oedema and ecchymosis were minimal in five patients and mild in five patients. Four out of five patients with minimal oedema and ecchymosis were injected with dental needle, which provided a controlled injection using a metal syringe without the risk of disconnection or nanoaspirate spoilage.

## CONCLUSION

In the context of infraorbital rejuvenation, nanofat seemed to be promising therapy with significant degree of improvement. Nanofat was associated with marked increase in patient satisfaction, better texture and homogeneity and minimal pain. In our study, we concluded that nanofat injection is beneficial for skin rejuvenation and per the post-operative skin texture changes. No contour irregularities or lumps were observed at three months of follow-up. Nanofat injection is safe and easy, with low tissue morbidity, thus considered as a novel treatment modality for facial rejuvenation and restoration, mainly to improve skin texture. One limitation of our study is the short follow up period; thus, additional studies with longer follow-up periods are recommended.

- **Conflict of interest:** None.
- **Sources of funding:** Our study didn't receive any grant from funding agencies.

## REFERENCES

1. **Vreck I, Ozgur O, Nakra T (2016):** Infraorbital dark circles: a review of the pathogenesis, evaluation and treatment. *Journal of Cutaneous and Aesthetic Surgery*, 9(2): 65-72.
2. **Park K, Kwon H, Youn C et al. (2018):** Treatments of infra-orbital dark circles by various etiologies. *Annals of Dermatology*, 30(5): 522-28.
3. **Lipp M, Weiss E (2019):** Nonsurgical treatments for infraorbital rejuvenation: a review. *Dermatologic Surgery*, 45(5): 700-10.
4. **Tonnard P, Verpaele A, Peeters G et al. (2013):** Nanofat grafting: basic research and clinical applications. *Plastic and Reconstructive Surgery*, 132(4): 1017-26.
5. **Ahuja S, Deshmukh A, Khushalani S (2017):** A study of dermatoscopic pattern of periorbital hypermelanosis. *Pigment International*, 4(1): 29-34.
6. **Sadick N, Bosniak S, Cantisano-Zilkha M et al. (2007):** Definition of the tear trough and the tear trough rating scale. *Journal of Cosmetic Dermatology*, 6(4): 218-22.
7. **Doghaim N, El-Tatawy R, Neinaa Y (2019):** Assessment of the efficacy and safety of platelet poor plasma gel as autologous dermal filler for facial rejuvenation. *Journal of Cosmetic Dermatology*, 18(5): 1271-9.
8. **Elnehrawy N, Ibrahim Z, Eltoukhy A et al. (2017):** Assessment of the efficacy and safety of single platelet-rich plasma injection on different types and grades of facial wrinkles. *Journal of Cosmetic Dermatology*, 16(1): 103-11.
9. **Khlosy H, Abouarab M (2020):** The efficacy of autologous nanofat injection in the treatment of infraorbital dark colouration. *The Egyptian Journal of Plastic and Reconstructive Surgery*, 43(3): 445-52.
10. **Chance E (2014):** Treatment of unwanted pigment. *Facial Plastic Surgery*, 30(01): 016-25.
11. **Roh M, Chung K (2009):** Infraorbital dark circles: definition, causes, and treatment options. *Dermatologic Surgery*, 35(8): 1163-71.
12. **Akbari F, Hadibarhaghtalab M, Parvar S et al. (2024):** Toward facial rejuvenation; A clinical trial to assess the efficacy of nano fat grafting on wrinkles. *Journal of Cosmetic Dermatology*, 23(2): 600-6.
13. **Oh D, Kim D, Roh T et al. (2014):** Correction of dark coloration of the lower eyelid skin with nanofat grafting. *Archives of Aesthetic Plastic Surgery*, 20(2): 92-6.
14. **Xu P, Yu Q, Huang H et al. (2018):** Nanofat increases dermis thickness and neovascularization in photoaged nude mouse skin. *Aesthetic Plastic Surgery*, 42: 343-51.
15. **Fakih-Gomez N, Steward E, Orte Aldea M (2021):** Nanofat in facial rejuvenation: step-by-step procedure, patient evaluation and recovery process. *The American Journal of Cosmetic Surgery*, 38(1): 27-35.
16. **Menkes S, Luca M, Soldati G et al. (2020):** Subcutaneous injections of nanofat adipose-derived stem cell grafting in facial rejuvenation. *Plastic and Reconstructive Surgery-Global Open*, 8(1): e2550. doi: 10.1097/GOX.0000000000002550
17. **Guo F, Song J, Chen Z et al. (2022):** Clinical evaluation of corrective effect of infraorbital depression by fat granule auto-transplantation via oral mucosa incision. *Annals of Translational Medicine*, 10(19): 1068. doi: 10.21037/atm-22-3872
18. **Xiao B, Zhang Z, Qiu L et al. (2019):** Clinical effect of nanofat on improving superficial Rhytides of face and neck and dark lower eyelids. *Chinese Journal of Medical Aesthetics and Cosmetology*, 6: 36-38.