

The Possible Ameliorative Role of Chrysin and Zinc on Lead Acetate Induced Nephrotoxicity in Adult Albino Rats (Biochemical, Histological and Immunohistochemical study)

Hanan I. El-Kerdasy and Amal Ghoneimy Metwally

Department of Anatomy and Embryology, Benha Faculty of Medicine, Benha University, Egypt

Corresponding author: Hanan I. El-Kerdasy, Telephone: 01007618122,

E-mail address: mhanan909@yahoo.com, ORCID: 0000-0001-9172-0289

ABSTRACT

Background and Objective: Chrysin has been used for suppression of inducible nitric oxide synthase. Zinc inhibits the production of oxygen-free radicals. This study aimed to assess the possible ameliorative role of chrysin and zinc on lead acetate nephrotoxicity.

Material and Methods: The study involved forty-five adult male albino rats that were categorized into, control group, lead acetate group, chrysin-treated group, zinc-treated group and chrysin plus zinc-treated group. At the end of the study blood samples were collected by cardiac puncture for laboratory analysis of blood urea and creatinine. The kidneys were collected and subjected to biochemical analysis, histological and immune-histochemical study.

Result: Lead acetate elevated the blood urea and creatinine level, the tissue malondialdehyde MDA level and reduced the level of antioxidant enzymes. It interrupted the normal histological structures of renal sections, elevated the main area percent of collagen fiber deposition, and P53 and TNF α positive immuno-reactivity. Both chrysin and zinc significantly declined the toxic effect of lead acetate in chrysin-treated group and zinc-treated group. Chrysin and zinc co-treatment has significantly decreased the blood urea and creatinine levels, malondialdehyde level, collagen fiber deposition, and P53 and TNF α positive immuno-reactivity and significantly increased the antioxidant enzyme levels compared to chrysin-treated group and zinc-treated group.

Conclusion: Lead acetate induced serious renal injury. Chrysin and zinc alone improved the toxic changes of lead acetate. However, coadministration of chrysin and zinc have a powerful ameliorative effect than chrysin and zinc alone.

Keywords: Chrysin, Zinc, Lead acetate, P53 immunostain and TNF α immunostain

INTRODUCTION

Lead (Pb) is a heavy metal that considered as an environmental pollutant and toxic agent. The World Health Organization lists Pb as one of the most harmful ten materials that are dangerous to human health ⁽¹⁾.

Lead toxicity is a significant health challenge and mostly caused by contaminated food, water, and air pollution ⁽²⁾.

The liver and kidneys have been described as important target organs for Pb toxicity due to their role in its metabolism ⁽³⁾. Pb can trigger apoptosis by degrading mitochondria and damaging DNA ⁽⁴⁾.

Chelating drugs that used in the treatment of lead toxicity showed some undesirable side effects and had no impact on the lead that had accumulated in tissues ⁽⁵⁾. Therefore, new alternative safer approaches are required. Plant-based compounds have gained popularity because of their natural origins, little cost, ease of accessibility, lower toxicity and fewer side effects ⁽⁶⁾.

Chrysin (5,7-dihydroxyflavone) is considered a recently studied flavonoid that commonly present in honey, propolis in addition to various compositions of plants ⁽⁷⁾. Many researchers reported that chrysin has antioxidant effects as free radicals can be eliminated by the hydroxyl groups in its construction ⁽⁸⁾.

In addition to its anti-inflammatory properties through reducing cyclooxygenase-2 (COX2), prostaglandin E and certain cytokines ⁽⁹⁾.

Zinc (Zn) is a necessary trace element that is vital for many metabolic processes and activities, such as

maintaining the structural integrity of zinc dependent proteins and reducing the toxicity of chemical components ⁽¹⁰⁾. Zinc can compete against lead for the similar binding sites on the metallothionein proteins that present in gastrointestinal tract, preventing its absorption ⁽¹¹⁾.

The current study aimed to evaluate the potential ameliorative role of chrysin and zinc on lead acetate nephrotoxicity.

MATERIAL AND METHODS

Rats

The experiment was carried out with forty-five adult male albino rats, weighing between 180 and 200 g. The rats were purchased from the animal house, Faculty of Veterinary Medicine, Benha University. The animals were reserved in typical laboratory circumstances, kept in separate cages, and given ordinary diet.

Medications

Lead acetate: was bought from Sigma-Aldrich Chemicals Company, Egypt. As a white crystalline powder, each 1.2 gm of lead acetate was melted in 200 ml distilled water. Each 1 ml contained 6 mg lead acetate

The animal was given 30 mg/kg b.wt. orally by gastric tube ⁽¹²⁾.

Chrysin: 5,7-dihydroxyflavone, 97% purity from Sigma-Aldrich Chemical Company (St Louis, MO, USA). Each 1 gm of chrysin was dissolved in 200 ml distilled water; each ml contained 5 mg chrysin. The animal was given 50 mg/kg b.wt. orally via gastric tube ⁽²⁾.

Zinc: was obtained from local pharmacy in the form of zinc sulphate 20 mg USP tablets from Reyoung Pharmaceutical Company, Egypt. Each tablet crushed and dissolved in 5 ml distilled water, each 1 ml contained 4 mg zinc sulphate. The animal was given 20 mg/kg b.wt. orally via gastric tube ⁽¹²⁾.

Experimental groups

The rats were separated for five groups, nine rats for each group. The period of the study was 35 days.

- Group I (control group) nine rats were equally divided into:
 - Subgroup Ia: animals were given 1 ml distilled water orally daily.
 - Subgroup Ib: animals were given chrysin 50 mg/kg b.wt. orally daily.
 - Subgroup Ic: animals were given zinc sulphate 20 mg/kg b.wt. orally daily.
- Group II (lead acetate group): rats were given lead acetate 30 mg/kg b.wt. orally daily ⁽¹²⁾.
- Group III (chrysin-treated group): rats were given chrysin 50 mg/kg body weight via gastric tube plus lead acetate as in group II daily ⁽²⁾.
- Group IV (zinc-treated group): rats were given zinc sulphate 20 mg/kg b.wt. orally plus lead acetate as in group II daily ⁽¹²⁾.
- Group V (chrysin + zinc treated group): rats were given both chrysin 50 mg/Kg + zinc sulphate 20 mg/Kg of b.wt. orally plus lead acetate as in group II daily.

One day next to the last dose of the drugs, the animals were anesthetized by light ether inhalation and cardiac puncture was done to collect blood samples for kidney function test. The animals were sacrificed by decapitation, then a midline abdominal incision was performed, kidneys of both sides were collected, washed by saline. Then perinephric fat and suprarenal gland were removed. Left kidneys were frozen in liquid nitrogen for biochemical study. Right kidneys were put in formalin 10% for histological and immunohistochemical stain.

Kidney function test

Blood samples from each rat were centrifuged for five minutes at 3000 rpm to isolate the serum. After that,

the serum was stored at or below -20°C for measuring serum urea and serum creatinine ⁽¹³⁾.

Biochemical analysis

Left kidney specimens were homogenised in an ice-cold buffer constituted of 50 mmol/L potassium phosphates, 1 mmol/L EDTA. Then kept at -20°C until analysis after being centrifuged for 15 minutes at 4°C . According to manufacturer's recommendations. The biochemical markers malondialdehyde MDA, catalase CAT, reduced glutathione GSH, superoxide dismutase SOD were assessed via Bio-diagnostics a colorimetric technique ⁽¹⁴⁻¹⁶⁾.

Histological study

The kidney tissues were at once fixed in formalin 10%, at that time they embedded in paraffin block, 5 μm thick cross-sections were done. They were stained by hematoxylin and eosin (H and E) and Masson's trichrome (MT) stains ⁽¹⁷⁾.

Immunohistochemical study

Renal sections were passed in xylene and alcohol then cleaned with phosphate-buffered saline (PBS). All sections were congested for one an hour in 3% bovine serum albumin in PBS, then were incubated with P53 and TNF α primary antibody. After that the sections were cleaned and incubated with biotinylated secondary antibody in 0.1% BSA in PBS for 60 minutes. Then, the 3-3'-diaminobenzidine was used as chromogen. Lastly, sections were counterstained by Mayer hematoxylin. Negative controls were obtained by substituting primary antibody with PBS ⁽¹⁸⁾.

Morphometric analysis:

Image analysis of the photomicrographs was done by using Image J software (Java; NIH, Bethesda, Maryland, USA) to evaluate the area percent of collagen fiber deposition in Masson trichrome stain. The area percent of nuclear P53 immunoreaction were measured in P53 immuno-stain. The area percent of TNF- α immunoreaction were measured in TNF- α immune-stain. The morphometric analysis was done on ten haphazardly photomicrographs at magnification x400. All data were introduced in an excel folder for statistical analysis.

Ethical approval:

All aspects of the study were approved by the Ethical Committee of Faculty of Medicine, Benha University number (RC 9-9-2023). The ethical guidelines for animal care were supervised by the animal house, Faculty of Medicine, Benha University. All the experimental procedures conformed to "Guide for the care and use of Laboratory Animals" for the use and welfare of experimental animals, published by the US National Institutes of Health (NIH publication No. 85-23, 1996).

Statistical study:

All data were evaluated by using version 20 SPSS (SPSS Inc., Chicago, Illinois, USA). The results were existing as mean \pm SD. One-way ANOVA and post hoc LSD test were used to notice significance if P value was $P \leq 0.05$.

RESULTS

Effect of chrysin and zinc on kidney function test (Table 1)

In lead acetate group the serum urea and creatinine were significantly elevated than control group. Serum urea and creatinine were significantly reduced in chrysin treated group and in zinc treated group compared with lead acetate group. Chrysin and zinc co-treatment in group V significantly decreased the serum urea and creatinine levels in comparison with groups II, III, and IV.

Effect of chrysin and zinc on biochemical analysis (Table 2)

The level of MDA in renal tissues in group II was significantly elevated than control group and the antioxidant enzymes (CAT, GSH and SOD) were significantly reduced in group II in comparison with group I. However, in groups III and IV, there were significant decrease in MDA level in comparison with lead acetate group, also a significant elevation of the antioxidant enzymes CAT, GSH and SOD in chrysin-treated group and group IV compared with group II. Chrysin and zinc co-treatment in group V significantly decreased the level of MDA in comparison with groups II, III, and IV. Also, there was significant increase in CAT, GSH and SOD compared with groups II, III, and IV.

Effect of chrysin and zinc on histological study

Renal sections stained by hematoxylin and eosin from control group (subgroup Ia, Ib and Ic) were the same as they showed normal histological structure, normal glomerulus, and the Bowman's capsule had normal urinary space. The proximal convoluted tubules (PCT) had lower columnar cells with basal spherical nuclei and narrow lumen. The distal convoluted tubules (DCT) had lower cuboidal cells with rounded central nuclei and wider lumen (Figure 1a).

Lead acetate induced changes in normal histological structures of renal sections from group II, they were represented by shrinkage glomeruli with wide urinary space, inflammatory cell-infiltration, the renal tubular cells have cytoplasmic vacuolations, and intratubular casts in the lumen. Other tubules were lined by flat cells and wide lumen (Figure 1b).

Group III, chrysin treated group showed, normal glomeruli with normal urinary space, inflammatory

cell-infiltration, normal PCT and DCT, some tubular cells had vacuolated cytoplasm and intratubular cast (Figure 1c). Sections from group IV, zinc treated group, showed normal glomeruli with normal urinary space, PCT appeared normal while, some renal tubular cells had vacuolated cytoplasm (Figure 1d). While renal sections from group V showed normal glomerulus and urinary space. The DCT had apparently normal structure (Figure 1e)

Masson trichrome stained sections from group I (Figure 2a) showed normal little distribution of collagen fibers. In the lead acetate group (Figure 2b) the sections showed marked increase in green color collagen fibers density and distribution. While the renal sections from chrysin treated group (Figure 2c) and zinc treated group (Figure 2d) showed moderate increase in the density and distribution of collagen fibers. The renal sections from group V (Figure 2e) showed little distribution of collagen fibers.

Immuno-histochemical study

P53 immunostained renal sections showed negative P53 immunoreactions in the control group (Figure 3a) and group V (Figure 3e) but there was highly diffuse positive P53 nuclear immunoreactions in group II (Figure 3b). While, renal sections from chrysin treated group (Figure 3c) and zinc treated group (Figure 3d) showed few positive P53 nuclear immunoreactions.

Renal sections stained by TNF- α immunostaining showed negative TNF- α immunoreactions in group I (Figure 4a) and group V (Figure 4e). While the sections from group II showed marked increase in TNF- α cytoplasmic immunoreactions (Figure 4b). Renal sections from group III (Figure 4c) and group IV (Figure 4d) showed moderate increase in TNF- α cytoplasmic immunoreactions.

Effect of chrysin and zinc on morphometric analysis

The main area % of collagen fibers deposition in M.T-stained renal sections revealed a significant increase in lead acetate group in comparison with control group. In comparison to group II, there was a significant reduction in chrysin treated group and zinc treated group. While there was a significant reduction in main area percent of collagen fibers deposition in group V compared to groups II, III, IV (Table 3, Figure 2f).

The area percent of P53 nuclear immunoreaction and TNF- α cytoplasmic immunoreaction in immunostained renal sections revealed a significant elevation in lead acetate group in comparison with group I. In comparison with group II, there was a significant reduction in group III and group IV. While there was a significant reduction in main area % of P53 nuclear immunoreaction and TNF- α cytoplasmic immunoreaction in group V compared to groups II, III, IV (Table 3, Figures 3f, 4f).

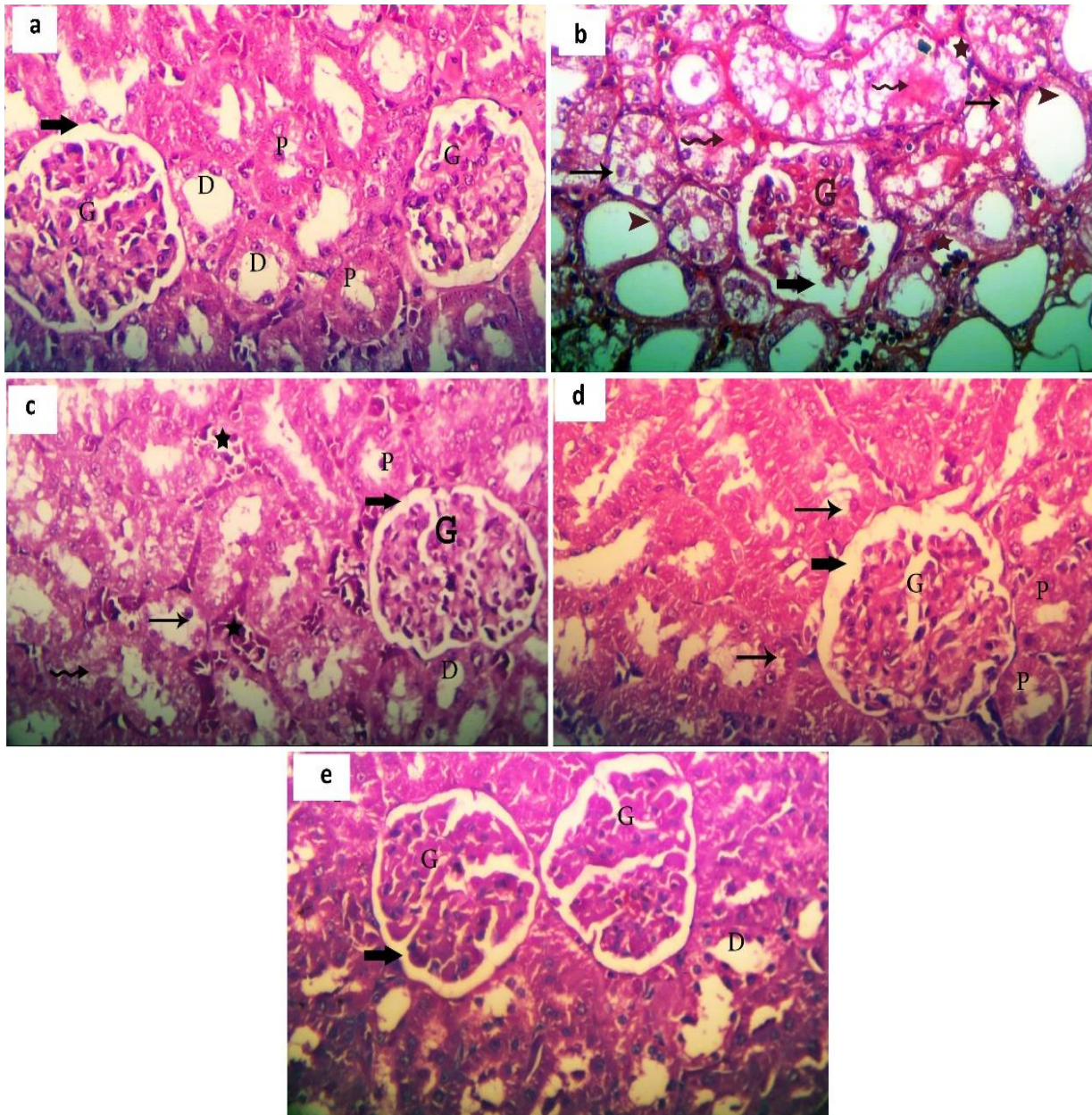


Fig. (1): Photomicrographs of renal section **(a)** from the control group showing: normal histological structure, normal glomerulus (G) Bowman's capsule has normal urinary space (thick arrow). PCT (P) have lower columnar cells with basal spherical nuclei and narrow lumen. DCT (D) have lower cuboidal cells with rounded central nuclei and wider lumen. **(b)** from the lead acetate group showing shrinkage glomeruli (G) with wide urinary space (thick arrow) inflammatory cell-infiltration (Star) the renal tubules have cytoplasmic vacuolations (arrow) intratubular cast (wavy arrow). other tubules lined by flat cells and have wide lumen (arrowhead). **(c)** from the chrysin-treated group showing normal glomeruli (G) with normal urinary space (thick arrow) inflammatory cell-infiltration (Star) normal PCT (P) and DCT (D), some renal tubular cells have vacuolated cytoplasm (arrow) intratubular cast (wavy arrow. **(d)** from the zinc-treated group showing: the glomeruli are normal (G) normal urinary space (thick arrow), normal PCT (P) some renal tubular cells have vacuolated cytoplasm (arrow). **(e)** from group V showing normal kidney tissue structure that have normal glomerulus (G) normal urinary space (thick arrow). DCT (D) have apparently normal structures (H and E X400)

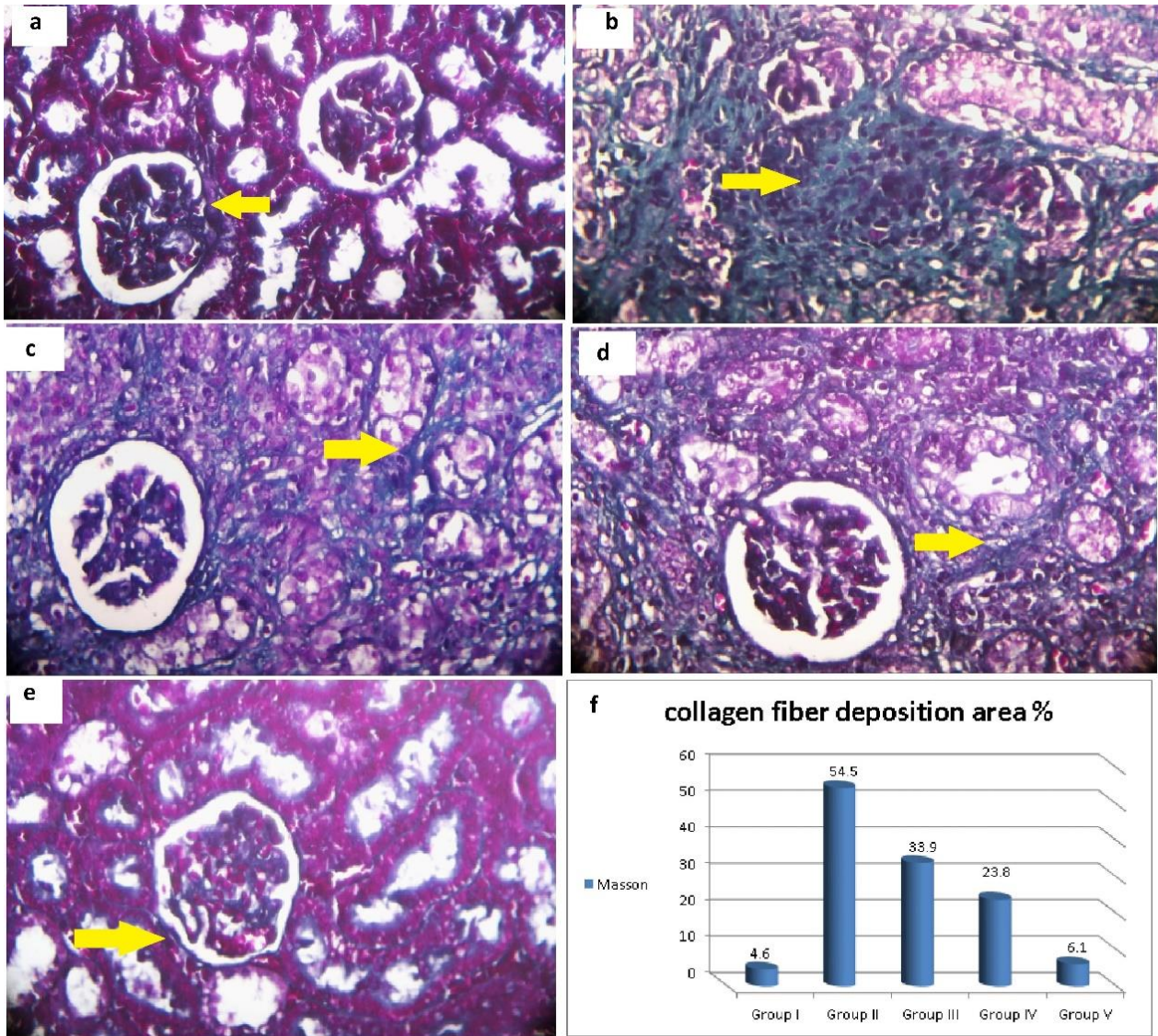


Fig. 2: Photomicrographs of renal sections from control (a) showing little distribution of collagen fibers (yellow arrow). Group II (b) showing marked increase in collagen fibers density and distribution (yellow arrow). Group III (c) and Group IV (d) showing moderate increase in the density and distribution of collagen fibers (yellow arrow). Group V (e) showing little distribution of collagen fibers (yellow arrow). (Masson Trichrome X 400) (f) Histogram showing the main area % of collagen fibers distribution

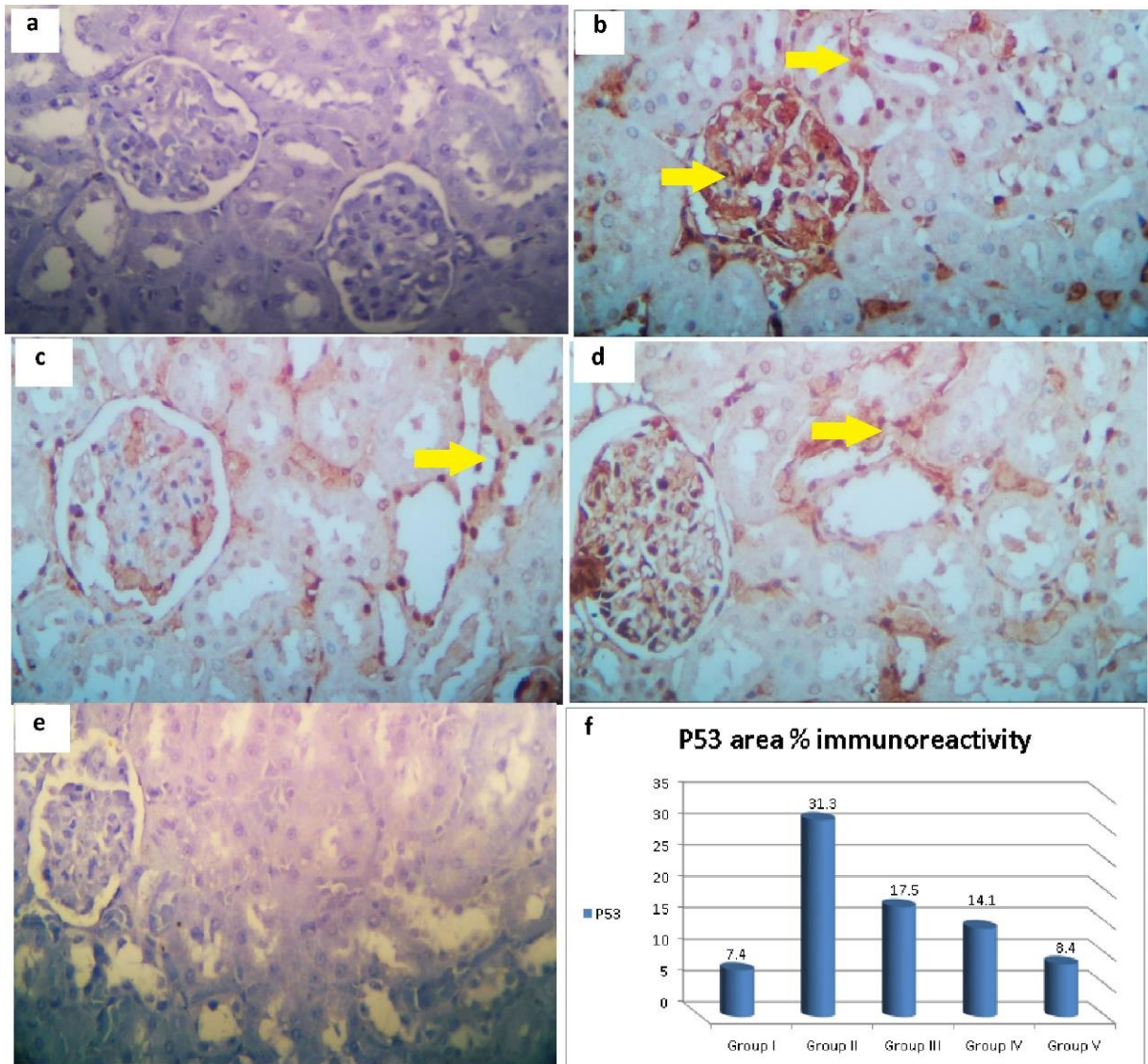


Fig. (3): Photomicrographs of renal sections from control group (a) showing: negative P53 nuclear immunoreactions. Group II (b) showing highly diffuse positive P53 nuclear immunoreactions (yellow arrow). Group III (c) showing: few positive P53 nuclear immunoreactions (yellow arrow). Group IV (d) showing: few positive P53 nuclear immunoreactions (yellow arrow). Group V (e) showing: negative P53 nuclear immunoreactions (**P53 immunostaining X 400**) (f) Histogram showing the main area % of positive P53 nuclear immunoreactions.

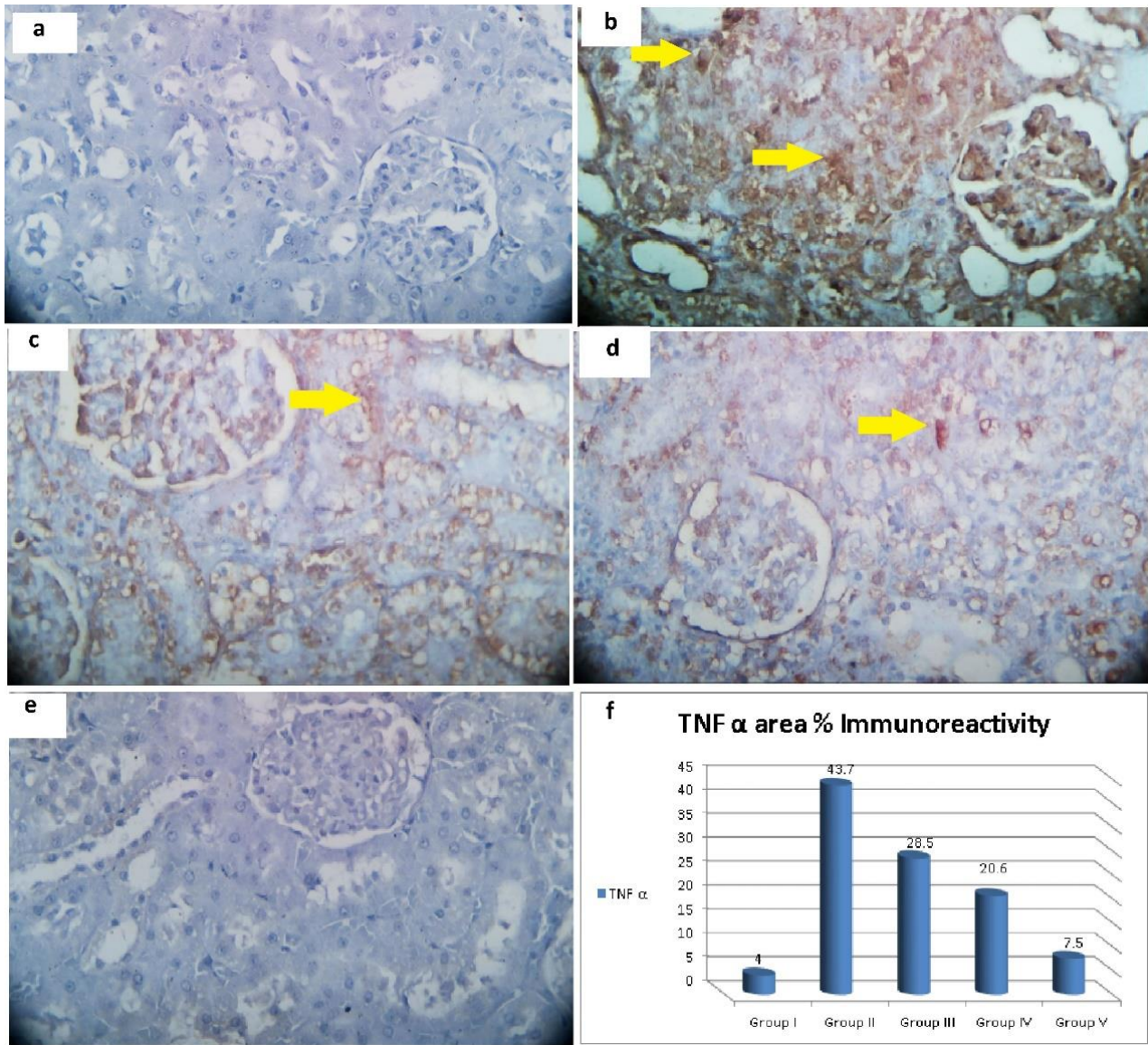


Fig. (4): photomicrographs of renal sections from the control group (a) showing: negative TNF-α cytoplasmic immunoreactions Group II (b) showing: marked increase in TNF-α cytoplasmic immunoreactions (yellow arrow). Group III (c) showing: moderate increase in TNF-α cytoplasmic immunoreactions (yellow arrow). Group IV (d) showing: moderate increase in TNF-α cytoplasmic immunoreactions (yellow arrow). Group V (e) showing: negative TNF-α cytoplasmic immunoreactions (TNF-α immunostaining X 400) (f) Histogram showing the main area % of positive TNF-α cytoplasmic immunoreactions.

Table (1): Changes in serum urea and creatinine in all groups

	Group I	Group II	Group III	Group IV	Group V
Urea(mg/dl)	24.6 ± 1.4	56.6 ± 1.1 a,c,d,e	31.1 ± 0.8 a,b,d,e	29.4 ± 0.67 a,b,c,e	26.2 ± 0.88 b,c,d
Creatinine (mg/dl)	0.68 ± 0.08	2.1 ± 0.2 a,c,d,e	1.2 ± 0.1 a,b,d,e	0.9 ± 0.07 a, b,c,e	0.78 ± 0.08 b,c,d

Data stated as mean ± SD, a: Significance vs group I, b: Significance vs group II, c: Significance vs group III, d: Significance vs group IV, e: Significance vs group V.

Table (2): Biochemical analysis in all groups

	Group I	Group II	Group III	Group IV	Group V
MDA (nmol/mg protein)	25.2 ± 1.3	41 ± 1.6 a,c,d,e	29.1 ± 1.6 a,b,d,e	27.5 ± 1.8 a,b,c,e	25.9 ± 0.87 b,c,d
CAT (U/mg protein)	34.4 ± 1.2	10.2 ± 0.95 a,c,d,e	22.2 ± 0.9 a,b,d,e	25.8 ± 1.1 a,b,c,e	33.7 ± 1.4 b,c,d
GSH (µmol /mg protein)	28.2 ± 0.99	8.8 ± 0.6 a,c,d,e	20.8 ± 0.9 a,b,d,e	22.5 ± 1.4 a,b,c,e	27.7 ± 0.9 b,c,d
SOD (U/mg protein)	5.9 ± 0.2	0.86 ± 0.2 a,c,d,e	3.8 ± 0.3 a,b,d,e	4.2 ± 0.4 a,b,c,e	5.3 ± 0.4 b,c,d

Data stated as mean ± SD, a: Significance vs group I, b: Significance vs group II, c: Significance vs group III, d: Significance vs group IV, e: Significance vs group V.

Table (3): The area % of collagen fibers deposition, P53 and TNF- α positive immunoreaction

	Group I	Group II	Group III	Group IV	Group V
Collagen deposition area %	4.6\pm0.7	54.5 \pm 12.5 a,c,d,e	33.9 \pm 9.9 a,b,d,e	23.8\pm4.7 a,b,c,e	6.1\pm1.4 b,c,d
P53 area%	7.4 \pm 0.98	31.3 \pm 4 a,c,d,e	17.5 \pm 1.1 a,b,d,e	14.1 \pm 0.9 a,b,c,e	8.4 \pm 0.96 b,c,d
TNF-α area %	4 \pm 1.2	43.7 \pm 0.75 a,c,d,e	28.5 \pm 2 a,b,d,e	20.6 \pm 1.5 a,b,c,e	7.5 \pm 1.1 b,c,d

Data stated as mean \pm SD, a: Significance vs group I, b: Significance vs group II, c: Significance vs group III, d: Significance vs group IV, e: Significance vs group V.

DISCUSSION

Numerous studies have examined the defensive properties of natural antioxidant compounds against the toxicity of heavy metals, and the findings were promising (19).

The purpose of the current study was to evaluate the ameliorative role of chrysin and zinc on lead acetate nephrotoxicity.

The kidney's primary excretory products are urea and creatinine. Major increase in their serum levels is suggestive of chronic renal disease or injury (20). In our study, the kidney function test showed that the average values of serum urea and creatinine were significantly greater in lead acetate group compared to control group ($P \leq 0.05$). Similar results were obtained by other authors (21) who mentioned that lead acetate-treated group presented significant higher levels of urea and creatinine and supposed that accelerated protein turnover and inability of glomeruli to reabsorb are the main causes of these rise in urea and creatinine. Consistent with our study some authors reported that lead acetate produced elevation of serum urea and creatinine levels probably due to lead deposition and accumulation in the renal tissue cause damage in the basement membrane of glomeruli therefore, decreasing the glomerular filtration and rise in the serum urea (22).

On the other hand, administration of chrysin and zinc alone or in combination significantly reduced the level of serum urea and creatinine compared to lead acetate group ($P \leq 0.05$). **Kucukler et al.** (2) mentioned that chrysin management can improve lead acetate-induced injuries in the kidney tissue and reduced urea and creatinine to average levels. Similarly, previous study revealed that management of rats by chrysin significantly prohibited the elevation in the serum urea and creatinine levels in cyclophosphamide induced nephrotoxicity (23).

Our findings are closely agreeing with the results of **Butt et al.** (12) who demonstrated that supplementation of zinc significantly returned the serum urea close to normal levels compared with lead-treated animals, however they reported that there was no significant impact on serum creatinine concentration.

The results of this experiment documented a marked rise in the MDA level and a concurrent decline in the antioxidant enzymes (CAT, GSH and SOD) in the renal tissues of lead acetate-treated rats in comparison to control rats ($P \leq 0.05$). This is in accordance with some authors (3) who explained that the cause of these

observations may be due to the high lead affinity for forming a strong bond with sulfhydryl (SH) groups of antioxidant enzyme, decreasing their activities and therefore resulting in oxidative stress. Previous studies reported that lead acetate produced a major reduction in the SOD and CAT activity in the kidney indicates a major oxidative stress activity (24).

In this work, group III as well as group IV presented an important decline in MDA level in renal tissues, while the antioxidant enzymes levels (CAT, SOD and GSH) were significantly elevated in comparison with group II. A more powerful impact was shown by chrysin + Zn co-treatment in group V as regard increasing antioxidant enzyme levels. Previous study described that the hydroxyl groups located at positions 5 and 7 in the chrysin structures are thought to be responsible for the compound's antioxidant properties as well as its capacity to eradicate free radicals (25). Similarly, some other authors (26) reported that treatment with chrysin increases the activity of antioxidant enzymes and protects tissues from oxidative damage.

Zinc interacts with heavy metals in their breakdown as well as toxicity (27). The results attained in our study obviously demonstrate the protective role of zinc on lead acetate toxicity in kidney tissues. Another study (28) revealed that receiving supplements of zinc and melatonin produce a protective role in renal ischemia-reperfusion (IR) by preventing oxidative damage and improving the kidney's antioxidant system.

In the current study, H and E-stained renal sections of group (II) showed major histopathological alterations represented by shrinkage of glomeruli with wide urinary space, inflammatory cell-infiltration, cytoplasmic vacuolations, and intratubular casts in the lumen. This is in agreement with **Kucukler et al.** (2) who found hydropic degeneration in tubular epithelium, necrosis and mononuclear cell infiltration in interstitial areas after lead acetate administration. **Usman et al.** (1) also stated tubular necrosis in the rat's kidneys of the lead treated group.

Our results revealed that renal sections from chrysin treated group showed normal glomeruli with normal urinary space, normal proximal and distal convoluted tubules, however some renal tubular cells had vacuolated cytoplasm. This was supported by the results of other authors (6) who confirmed no abnormalities in the kidney histology after chrysin administration to carbon tetrachloride treated rats. Co-

supplementation of zinc with chrysin in group V revealed normal glomerulus and urinary space. The proximal as well as distal convoluted tubules have apparently normal cells without vacuolated cytoplasm. This result revealed that chrysin and zinc co-treatment was returning the normal histological structures of renal sections than chrysin and zinc alone. This was in line with **Butt et al.** ⁽¹²⁾ who found that zinc treated rats showed a significant decrease in epithelial cell damage and congestion in renal tissue compared to lead acetate group.

This work revealed marked increase in the amount of collagen fibers distribution in the renal sections stained by Masson Trichome in group (II). Similarly, **Balaji et al.** ⁽²⁹⁾ documented that the kidneys' entire collagen content significantly increased in lead acetate-treated rats compared with control rats. But conversely, the renal sections from chrysin treated group and zinc treated group showed moderate increase in the density and distribution of collagen fibers. This in line with other authors ⁽³⁰⁾ who confirmed that chrysin treatment significantly decreased collagen fiber deposition and it can protect against renal tubulointerstitial fibrosis produced by cyclosporine A through Transforming Growth Factor B1(TGF- β 1) inhibition.

When DNA damage occurs and reactive oxygen species levels rise, p53 protein levels quickly rise to considerable levels ⁽³¹⁾. Also, other authors ⁽³²⁾ mentioned that lead acetate has the ability to damage DNA directly or indirectly through the induction of oxidative stress in cells and DNA. This interprets why the present study found that lead acetate seriously damages the kidneys and therefore, sections from group II showed highly diffuse positive P53 nuclear immunoreactions.

In this study groups III and IV exhibited few positive P53 nuclear immunoreactions in the current study. While renal sections of group V showed negative P53 immunoreactions. This indicated the highly ameliorative role of chrysin and zinc combination in treatment of lead acetate nephrotoxicity. This is supported by the work of **Kucukler et al.** ⁽²⁾ who stated that chrysin decreases the level of p53 by improving oxidative stress and DNA destruction because of its antioxidant influence, so protecting renal tissue from lead acetate toxicity.

This is in agreement with **Moslemi et al.** ⁽³³⁾ who found that zinc inhibits apoptosis and protects against renal ischemia-reperfusion injury, potentially as a result of lowering oxidative stress and caspase 3 activation.

Also lead acetate sections revealed marked increase in TNF- α cytoplasmic immunoreactions. This is in agreement with **Kucukler et al.** ⁽²⁾ who demonstrated that lead acetate cause marked expression of TNF- α in renal glomeruli and interstitial tissue. This may be explained by oxidative stress, which stimulates Nuclear Factor Kappa B (NF-kB) and an inflammatory mechanism is triggered, which results in liberation of pro-inflammatory cytokines, mainly TNF- α ⁽³⁴⁾.

In this experiment, administration of zinc with chrysin in group V showed negative TNF- α cytoplasmic immunoreactions as in control group. Flavonoids have an essential role in the regulation of cellular processes, including the inflammatory pathways modulation and cell cycle signals ⁽³⁵⁾. Our study found moderate TNF- α cytoplasmic expression in renal sections of chrysin treated rats. Similar results obtained by other authors ⁽²⁶⁾ who mentioned that chrysin successfully decline the rise in ferric nitrilotriacetate-mediated TNF- α and COX-2 immunoreactions.

CONCLUSION

Lead acetate has disturbed the normal histological structures of renal tissue, with elevation of main area percent of collagen fiber deposition, P53 and TNF- α positive immune-reactivity. It also increased serum urea, creatinine and level of tissue MDA, but reduced the level of antioxidant enzymes. Chrysin and zinc co-treatment highly improved the histopathological and immune-histochemical changes in renal sections and biochemical analysis.

- **Conflicts of Interest:** The authors declared no conflicts of interest regarding the publication of this paper.
- **Funding:** No fund.

REFERENCES

1. **Usman A, Kawu M, Shittu M et al. (2022):** Comparative effects of methanol leaf extract of *Moringa oleifera* and ascorbic acid on haematological and histopathological changes induced by subchronic lead toxicity in male Wistar rats. *Pharmacological Research-Modern Chinese Medicine*, 2: 100031.
2. **Kucukler S, Benzer F, Yildirim S et al. (2021):** Protective effects of chrysin against oxidative stress and inflammation induced by lead acetate in rat kidneys: a biochemical and histopathological approach. *Biol Trace Elem Res.*,199(4):1501-1514.
3. **Adebisi O, Agbaje W, Adewale O (2022):** Modulatory efficacy of *Punica granatum L.* powder ethanol extract (PLEE) on lead acetate-induced hepatic and renal toxicity. *Clinical Phytoscience*, 8(1): 1-9.
4. **Liu J, Jia D, Cai S et al. (2015):** Mitochondria defects are involved in lead-acetate-induced adult hematopoietic stem cell decline. *Toxicol Lett.*, 235(1):37-44.
5. **Caglayan C, Kandemir F, Yildirim S et al. (2019):** Rutin protects mercuric chloride-induced nephrotoxicity via targeting of aquaporin 1 level, oxidative stress, apoptosis and inflammation in rats. *J Trace Elem Med Biol.*, 54:69-78.
6. **Baykalir B, Arslan A, Mutlu S et al. (2021):** The protective effect of chrysin against carbon tetrachloride-induced kidney and liver tissue damage in rats. *Int J Vitam Nutr Res.*, 91(5-6):427-438.
7. **Hanedan B, Ozkaraca M, Kirbas A et al. (2018):** Investigation of the effects of hesperidin and chrysin on renal injury induced by colistin in rats. *Biomed Pharmacother.*, 108:1607-1616.
8. **Nageeb M, Amer M, Hendawy D et al. (2023):** The alleviative efficacy of sildenafil and chrysin against zinc

- oxide nanoparticles-provoked hepatic and blood toxicity: role of MyD88/NF- κ B1/TNF- α pathway. Beni-Suef Univ J Basic Appl Sci., 12: 105-119.
9. **Şimşek H, Akaras N, Gür C et al. (2023):** Beneficial effects of chrysin on cadmium-induced nephrotoxicity in rats: Modulating the levels of Nrf2/HO-1, RAGE/NLRP3, and caspase-3/Bax/Bcl-2 signaling pathways Gene, 875: 147502. doi: 10.1016/j.gene.2023.147502
 10. **Wani A, Ansari M, Ahmad M et al. (2019):** Influence of zinc levels on the toxic manifestations of lead exposure among the occupationally exposed workers. Environ Sci Pollut Res Int., 26(32):33541-33554.
 11. **Tariq U, Sadiq B, Hameed A (2018):** Probing the individual and synergistic effect of calcium and zinc against lead induced hematological alterations and oxidative stress. Annals of the Complementary and Alternative Medicine, 1(1):1003.
 12. **Butt M, Javed K, Tariq U (2023):** Co-supplementation of zinc and calcium suppresses bio-absorption of lead in Sprague Dawley rats. Biological Trace Element Research, 201(3): 1317-1326.
 13. **Tietz N (1990):** Clinical Guide to Laboratory Tests 2nd edn, 566 (W. B. Saunders Company).
 14. **Ohkawa H, Ohishi N, Yagi K (1979):** Assay for lipid peroxides in animal tissues by thiobarbituric acid reaction. Anal Biochem., 95(2):351-8.
 15. **Beers R, Sizer I (1952):** A spectrophotometric method for measuring the breakdown of hydrogen peroxide by catalase. J Biol Chem., 195(1):133-40.
 16. **Misra H, Fridovich I (1972):** The role of superoxide anion in the autoxidation of epinephrine and a simple assay for superoxide dismutase. J Biol Chem., 247(10):3170-5.
 17. **Suvarna S, Layton C, Bancroft J (2019):** The hematoxylin and eosin. In: Bancroft's Theory and Practice of Histological Techniques, Eighteen ed., 126-138. <https://www.semanticscholar.org/paper/Bancroft's-Theory-and-Practic...>
 18. **Hassan K, Ahmed M, Hassanein K et al. (2016):** Ameliorating effect of vitamin C and selenium against nicotine induced oxidative stress and changes of P53 expression in pregnant albino rats. Journal of Advanced Veterinary and Animal Research, 3(4): 321-331.
 19. **Khalil S, Elhady W, Elewa Y et al. (2018):** Possible role of *Arthrospira platensis* in reversing oxidative stress-mediated liver damage in rats exposed to lead. Biomed Pharmacother., 97:1259-1268.
 20. **Soussi A, Gargouri M, Akrouti A et al. (2018):** Antioxidant and nephro-protective effect of *Juglans regia* vegetable oil against lead-induced nephrotoxicity in rats and its characterization by GC-MS. EXCLI J., 17:492-504.
 21. **Ilesanmi O, Agoro E (2022):** Ameliorative effect of Trevo dietary supplement against lead acetate nephrotoxicity. Iranian Journal of Toxicology, 16(1): 35-42.
 22. **Amah U, Madu N, Ahaneku J et al. (2017):** Evaluation of nephrotoxic effect of lead exposure among automobile repairers in Nnewi Metropolis. Int J Res Med Sci., 2(3):1107-1111.
 23. **Temel Y, Kucukler S, Yildirim S et al. (2020):** Protective effect of chrysin on cyclophosphamide-induced hepatotoxicity and nephrotoxicity via the inhibition of oxidative stress, inflammation, and apoptosis. Naunyn Schmiedebergs Arch Pharmacol., 393(3):325-337.
 24. **Gargouri M, Soussi A, Akrouti A et al. (2018):** Ameliorative effects of *Spirulina platensis* against lead-induced nephrotoxicity in newborn rats: Modulation of oxidative stress and histopathological changes. EXCLI J., 17:215-232.
 25. **Eldutar E, Kandemir F, Kucukler S et al. (2017):** Restorative effects of chrysin pretreatment on oxidant-antioxidant status, inflammatory cytokine production, and apoptotic and autophagic markers in acute paracetamol-induced hepatotoxicity in rats: An experimental and biochemical study. J Biochem Mol Toxicol., 31(11).
 26. **Rehman M, Tahir M, Khan A Hamiza et al. (2013):** Chrysin suppresses renal carcinogenesis via amelioration of hyperproliferation, oxidative stress and inflammation: plausible role of NF- κ B. Toxicol Lett., 216(2-3):146-58.
 27. **Jan A, Azam M, Siddiqui K et al. (2015):** Heavy metals and human health: Mechanistic insight into toxicity and counter defense system of antioxidants. Int J Mol Sci., 16(12):29592-630.
 28. **Yilmaz M, Mogulkoc R, Baltaci A (2015):** Effect of three-week zinc and melatonin supplementation on the oxidant-antioxidant system in experimental renal ischemia reperfusion in rats. Acta Clinica Croatica, 54:4.
 29. **Balaji K, Vijayakumar J, Sankaran P et al. (2021):** Molecular studies on the nephroprotective potential of *Celastrus paniculatus* against lead-acetate-induced nephrotoxicity in experimental rats: Role of the PI3K/AKT signaling pathway. Molecules, 26(21):6647.
 30. **Nagavally R, Sunilkumar S, Akhtar M. et al. (2021):** Chrysin ameliorates cyclosporine-a-induced renal fibrosis by inhibiting TGF- β 1-induced epithelial-mesenchymal transition. Int J Mol Sci., 22(19):10252.
 31. **Xu J, Lian L, Wu C et al. (2007):** Lead induces oxidative stress, DNA damage and alteration of p53, Bax and Bcl-2 expressions in mice. Food Chem Toxicol., 46(5):1488-94.
 32. **Paulis M, Hassan O, Abbass M et al. (2018):** Structural and lipid peroxidation effects of lead on rat hippocampus and its attenuation by hydrogen rich water. J Chem Neuroanat., 91:55-62.
 33. **Moslemi F, Talebi A, Nematbakhsh M (2019):** Protective effect of zinc supplementation on renal ischemia/reperfusion injury in rat: Gender-related difference. Int J Prev Med., 10:68.
 34. **Faheem M, Akhtar T, Naseem N et al. (2023):** Chrysin Is immunomodulatory and anti-inflammatory against complete Freund's adjuvant-induced arthritis in a pre-clinical rodent model. Pharmaceutics, 15(4): 1225.
 35. **Umar M, Jabeen F, Ashraf A et al. (2022):** Evaluation of possible protective role of chrysin against arsenic-induced nephrotoxicity in rats, Toxin Reviews, 41(4): 1237-1245.