

## Safety and Complications of Diagnostic Medical Thoracoscopy: A 3-year experience of a single centre

Houssam Eldin Hassanin Abd Elnaby\*, Ahmed Ibrahim Aboseif

The Department of Chest Diseases, Faculty of Medicine, Al-Azhar University, Cairo, Egypt.

\*Corresponding author: Houssam Eldin Hassanin Abd Elnaby, Mobile: (+2)01011605616, E-mail: drhoussam151979@gmail.com.

### ABSTRACT

**Background:** Medical thoracoscopy (MT) is one of the oldest invasive interventional techniques in the recent history of respiratory medicine. Its role in clinical practice was emphasized in the last few years, and it almost replaced the traditional closed pleural biopsy method.

**Aim of the Study:** To evaluate the safety and the rate of possible complications during and after medical thoracoscopy performed for diagnostic purposes at a single centre in Cairo, Egypt.

**Patients and Methods:** This is a retrospective analytical study of data collected from the medical records of all patients (226 patients) that underwent diagnostic medical thoracoscopy at our center in successive three years.

**Results:** The mean age of the study patients was  $55.37 \pm 13.69$  years, 125 (55.3%) of them were males, while 101 (44.7%) were females and 137 patients (60.62%) had a risk of asbestos exposure. Persistent air-leak  $\geq 7$  days was the most frequent major thoracoscopic complication, detected in 10 patients (4.42%), followed by hypoxemia in 9 patients (3.98%), then post-procedure pneumonia and arrhythmia in 5 patients (2.21%) for each. The most common minor thoracoscopic complication was post-procedure pain in 74 patients (32.74%), followed by transient air-leak  $< 7$  days in 25 patients (11.61%) then post-procedure unexplained fever in 23 patients (10.17%) and subcutaneous emphysema in 19 patients (8.4%).

**Conclusion:** Medical thoracoscopy is a simple, valuable and safe diagnostic procedure, which carries a limited possibility of complications, most of them are not serious and easy to be controlled.

**Keywords:** Safety, Complications, Medical thoracoscopy.

### INTRODUCTION

Medical thoracoscopy is a minimally invasive ambulatory procedure performed under local anesthesia or conscious sedation which allows for direct visualization of the pleural cavity for biopsy targets, as well as simultaneous therapeutic interventions, including chemical pleurodesis and indwelling tunneled pleural catheter (ITPC) placement<sup>(1)</sup>.

As the differential diagnosis of pleural effusion can present a considerable challenge, and about 25-40% of the pleural effusions remain undiagnosed after fluid cytology and/or blind pleural biopsy<sup>(2)</sup>, (MT) has become increasingly used by chest physicians<sup>(3)</sup>. It is considered to be one of the main areas of interventional pulmonology<sup>(4)</sup> and an important part of a specialist pleural disease service<sup>(5)</sup>. Although the risks of (MT) are generally low, the advantages of the procedure should be weighed against the discomfort of the patient and the slight potential for morbidity and mortality. In addition, it is important for adequate precautions to be taken, including the recommended technical procedure, as well as monitoring of cardiac rhythm, haemodynamic parameters and oxygen saturation during the procedure<sup>(3)</sup>.

This study aimed at evaluating the safety and the rate of possible complications during and after medical thoracoscopy performed for diagnostic purposes at a single centre in Cairo, Egypt.

### PATIENTS AND METHODS

This was a retrospective-descriptive analytical study, included the data of 226 subjects, representing the total number of patients who underwent medical thoracoscopy at our University Hospital in Cairo, Egypt, in successive three years. This hospital is a large tertiary health care hospital, which received referrals from the four quadrants of the republic. All cases had exudative pleural effusion according to Light's criteria<sup>(6)</sup>, and the etiology of pleural effusion was still undiagnosed after initial laboratory tests including pleural fluid cytology and assessment for tuberculosis (TB).

#### *Medical thoracoscopic technique*

Thoracic ultrasound (using the apparatus Sonoscape - SS1, China) was performed before thoracoscopy to assess for the nature, amount, presence of adhesions and septations of pleural effusion and to judge the convenience and safety of the procedure; during thoracoscopy to choose the optimal entry point and to guide thoracoscope; and lastly after the end of the procedure to assess for complications<sup>(7,8)</sup>. Medical thoracoscopies were performed in the Endoscopy Suite (Interventional Pulmonology Unit) in our University Hospital, using a seven-mm rigid thoracoscope set (Karl Storz Endoscope; Karl Storz; Tuttlingen, Germany) and a three-mm biopsy forceps. The procedure was performed



This article is an open access article distributed under the terms and conditions of the Creative Commons Attribution (CC BY-SA) license (<http://creativecommons.org/licenses/by/4.0/>)

by pulmonologists under local anesthesia using lidocaine local injection with conscious sedation by intravenous midazolam, following sterile draping of the skin. Patients were placed in the lateral decubitus position with the affected hemithorax upward, and his/her arms positioned over his/her head to widen intercostal spaces <sup>(9)</sup>. Throughout the procedure, arterial blood pressure, electrocardiography and oxygen saturation were continuously monitored. Supplemental oxygen was given to maintain oxygen saturation above 90% <sup>(10)</sup>. After local anesthesia was applied into the skin and soft tissues at the site of entry; at the level of the fifth or sixth intercostal spaces in the area between the anterior and mid-axillary lines, about one-centimeter incision was done through the skin above the upper border of the lower rib, and the passage to the parietal pleura was created by blunt dissection <sup>(11)</sup>. Once the lung was collapsed; suction of pleural fluid was done by a sterile wide-pore catheter to clarify the field. The thoracoscopist inspected the whole pleural cavity in a slow circular motion, thereafter two to four biopsies were taken by the ‘lift and peel’ technique from the apparently affected areas or from different areas if no apparent pathologic abnormalities were seen <sup>(12)</sup>.

**Data collection**

Data were collected from the patients’ medical records, including demographic and clinical data, imaging findings, gross medical thoracoscopic features, histopathological yield and procedure-related complications.

**Statistical analysis:**

Statistical analysis of data was performed using Statistical Package for the Social Sciences (SPSS) version 16 (IBM corp., Armonk, NY, USA). Categorical variables were expressed as frequency (percentage), while continuous variables were expressed in the form of mean ± SD (standard deviation). P-value at the level of significance was ≤0.05.

**Ethical approval**

**The study was approved by the Ethical Board of Al-Azhar University. Because of the retrospective nature of the study, the consent condition was conceded. Confidentiality was ensured for all used data, which were recorded anonymously. This work was carried out in accordance to the Code of Ethics of the World Medical Association (Declaration of Helsinki) for studies involving humans.**

**RESULTS**

The total number of patients included in this study was 226 patients. Demographic and baseline data of the study population were displayed in table (1). The mean age of the study patients was 55.37 ± 13.69 years, 125 (55.3%) of them were males, while 101 (44.7%) were females, 59 patients (26.1%) were smokers and 137 patients (60.62%) had a risk of asbestos exposure, either through occupation and/or residence (Shubra El-Kheima or Helwan).

**Table (1): Demographic data and baseline characteristics of the study population:**

Criteria	Value [n (%)]
<b>Age</b>	
Mean age ± SD (years)	55.37 ± 13.69
Range (years)	18-86
<b>Sex</b>	
Male	125 (55.3)
Female	101 (44.7)
<b>Smoking habit</b>	
Smoker	59 (26.1)
Ex-smoker	21 (9.3)
Non-smoker	146 (64.6)
<b>Smoking index</b>	
pack/year (mean ± SD) (n=59)	43.12 ± 21.54
<b>Exposure</b>	
Occupational/residence risk of asbestos exposure	137 (60.62)

SD: standard deviation

As shown in table (2), dyspnea was the most common symptom, being existed in 219 patients (96.9%), followed by pleuretic chest pain in 129 patients (57%) and cough in 77 patients (34%). The effusion was right-sided in 130 patients (57.52%), left-sided in 88 patients (38.94%) and bilateral in 8 patients (3.54%).

**Table (2): Clinical data of the study population:**

Criteria	Value [n (%)]
<b>Symptoms</b>	
Dyspnea	219 (96.9)
Pleuretic chest pain	129 (57)
Cough	77 (34)
Toxic manifestations	48 (21.24)
Hemoptysis	9 (3.98)
<b>Side</b>	
Right	130 (57.52)
Left	88 (38.94)
Bilateral	8 (3.54)

Massive effusion was present in 145 patients (64.16%), while 81 patients (35.84%) had mild to moderate amount when assessed by ultrasound. The effusion was echogenically complex in most of patients, with no septations in 147 of them (65%), and septations in 51 patients (22.57%). The most frequently observed CT findings within the study patients; rather than pleural effusion, were pleural thickening in 58 patients (25.66%) and consolidation in 26 patients (11.5%) (Table 3).

**Table (3): Imaging data of the study population:**

Criteria	Value [n (%)]
<b>Ultrasound</b>	
<b>Amount</b>	
Mild to moderate	81 (35.84)
Massive	145 (64.16)
<b>Pattern</b>	
Complex non-septated	147 (65)
Complex septated	51 (22.57)
Anechoic	25 (11.06)
Homogenous	3 (1.37)
<b>CT</b>	
<b>Findings</b>	
Pleural thickening	58 (25.66)
Consolidation	26 (11.5)
Nodule	19 (8.4)
Mass	8 (3.54)
Mediastinal/Hilar lymphadenopathy	15 (6.63)

CT: Computed tomography

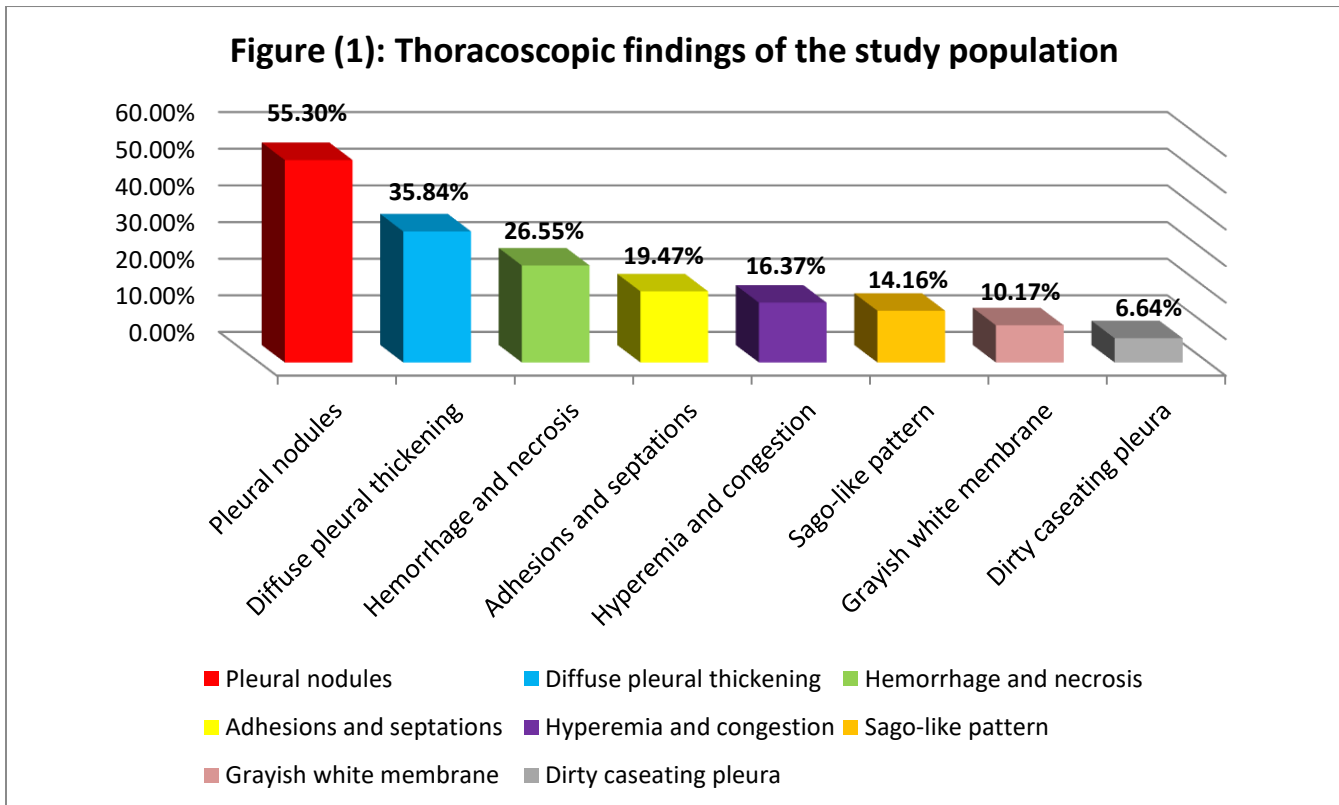
More than two thirds of the study patients 157 (69.5%) showed a malignant histopathological yield, and malignant mesothelioma versus metastatic adenocarcinoma was the leading neoplastic pattern as it was presented in 143 patients (63.27%) of the overall study population, 41 patients (18.1%) had caseating granuloma (TB), while 28 patients (12.4%) remained undiagnosed, with their biopsy reports revealing non-specific inflammation (Table 4).

**Table (4): Histopathological yeild of the study population:**

Histopathology	Value [n (%)]
<b>Malignancy</b>	157 (69.5)
Malignant mesothelioma vs. metastatic adenocarcinoma	143 (63.27)
SCC	6 (2.65)
Lymphoma	5 (2.21)
SCLC	2 (0.913)
Metastatic lieomyosarcoma	1 (0.457)
<b>Caseating granuloma</b>	41 (18.1)
<b>Non-specific inflammation</b>	28 (12.4)

SCC: Squamous cell carcinoma, SCLC: Small-cell lung cancer.

As enlightened in figure (1), pleural nodulation was the most common observed thoracoscopic finding in (55.3%) of patients, followed by diffuse pleural thickening in (35.84%), areas of hemorrhage and necrosis in (26.55%) and adhesions and septations in (19.47%).



Persistent air-leak  $\geq 7$  days was the most frequent major thoracoscopic complication, detected in 10 patients (4.42%), followed by hypoxemia in 9 patients (3.98%), then post-procedure pneumonia and arrhythmia in 5 patients (2.21%) for each, post-procedure empyema in 4 patients (1.77%), hypotension in 3 patients (1.32%), lung laceration in 2 patients (0.88%) and finally re-expansion pulmonary edema in only one patient (0.44%). No procedure-related mortalities, massive intra-pleural hemorrhage, extra-pulmonary vital organ injury nor malignant invasion of scar were recorded among the study population (Table 5).

**Table (5): Major thoracoscopic complications in the study population:**

Complication	Value [n (%)]
Procedure-related mortality	0 (0)
Massive intra-pleural hemorrhage requiring thoracotomy	0 (0)
Lung laceration	2 (0.88)
Extra-pulmonary vital structure injury	0 (0)
Re-expansion pulmonary oedema	1 (0.44)
Post-procedure empyema	4 (1.77)
Post-procedure pneumonia	5 (2.21)
Persistent air-leak $\geq 7$ days	10 (4.42)
Malignant invasion of scar	0 (0)
Arrhythmia	5 (2.21)
Hypotension	3 (1.32)
Hypoxemia	9 (3.98)

The recorded minor thoracoscopic complications were post-procedure pain in 74 patients (32.74%), transient air-leak <7 days in 25 patients (11.61%), post-procedure unexplained fever in 23 patients (10.17%), subcutaneous emphysema in 19 patients (8.4%), post-procedure cough in 17 patients (7.52%), minor intra-pleural hemorrhage in 12 patients (5.3%), operative skin-site infection in 11 patients (4.68%) and subcutaneous hematoma in 8 patients (3.54%) (Table 6).

**Table (6): Minor thoracoscopic complications in the study population:**

Complication	Value [n (%)]
Minor intra-pleural hemorrhage	12 (5.3)
Transient air-leak <7 days	25 (11.61)
Subcutaneous emphysema	19 (8.4)
Subcutaneous hematoma	8 (3.54)
Post-procedure unexplained fever	23 (10.17)
Post-procedure pain	74 (32.74)
Post-procedure cough	17 (7.52)
Operative skin-site infection	11 (4.68)

## DISCUSSION

In the case of a proven exudate with non-conclusive cytology after (repeated) thoracentesis, an additional procedure to obtain pleural tissue for histology should be the next step. This can be carried out with a minimally invasive procedure in four ways: closed pleural biopsy (Abram's biopsy), thoracoscopy, ultrasound-guided biopsy, and CT-guided biopsy (13).

Medical thoracoscopy is commonly performed as a definitive diagnostic method in undiagnosed exudative pleural effusion (14), as well as its role in the management of pleural diseases. Many authors claim that (MT) is a safe procedure with low mortality (15).

This retrospective analytical study was established to discuss the safety and complications among patients underwent (MT) for diagnostic objectives during three successive years at a single centre in Cairo, Egypt. The total number of patients implicated in the study was 226 patients.

In this study, dyspnea was the most common presenting symptom (96.9%), followed by pleuretic chest pain (57%) and cough (34%). Dyspnea was considered as

the main symptom among the vast majority (>95%) of patients, followed by chest pain and cough in many studies concerned with exudative pleural effusion (16-18).

The pleural effusion in our patients was more frequently right-sided (57.52%). However, it was left-sided in (38.94%) and bilateral in (3.54%). Right side predominance in exudative pleural effusions was documented by almost all reports (18,19).

According to the internal echogenicity, effusion can be sub-classified as anechoic, complex non-septated, complex septated or homogeneously echogenic. Effusions are usually exudates when they are septated or show a complex or homogeneously echogenic pattern (20). In the current study, the echo-pattern of pleural effusion was complex non-septated in (65%) of patients, complex septated in (22.57%), anechoic in (11.06%) and homogenous in only (1.37%). These results merge with those of *Hassan and his co-workers* (21), who concluded that complex non-septated pattern in the sonographic appearance is a useful predictor of malignant pleural effusions, whereas a complex septated pattern is a useful predictor in non-malignant effusions, after taking in

consideration that more than two-thirds of our patients had malignant effusions.

In the present study, (MT) provided definite diagnosis in 198 patients (87.6%). This yield is almost the same as the output (87.8%) obtained by *Sobh et al.* <sup>(16)</sup>. However, some studies reported better results such as *Wan et al.* <sup>(22)</sup>, *Ahmed et al.* <sup>(23)</sup>, *Wang et al.* <sup>(24)</sup> and *Chen et al.* <sup>(25)</sup>, who reached final diagnosis in (95.8%, 94%, 92.6% and 91.9%) of their patients respectively. Other studies showed lower diagnostic outcomes as those found by *Aujayeb and Jackson* <sup>(19)</sup> (78%) and *Ahmed et al.* <sup>(10)</sup> (78.7%).

In our work, malignancy was the mostly recorded histopathological pattern in 157 patients (69.5%), with 143 (63.27%) out of them showed a picture of malignant mesothelioma versus metastatic adenocarcinoma, while caseating granuloma (TB) was detected in 41 patients (18.1%). Predominant malignant pathology was reported in a lot of studies <sup>(16,19,20,23)</sup>.

In the current study, persistent air-leak  $\geq 7$  days was the most frequent major thoracoscopic complication, being detected in 10 patients (4.42%), followed by hypoxemia in 9 patients (3.98%), then post-procedure pneumonia and arrhythmia in 5 patients (2.21%) for each, post-procedure empyema in 4 patients (1.77%), hypotension in 3 patients (1.32%), lung laceration in 2 patients (0.88%) and finally re-expansion pulmonary edema in only one patient (0.44%), No procedure-related mortalities, massive intra-pleural hemorrhage, extra-pulmonary vital organ injury nor malignant invasion of scar were recorded among the study population.

Almost all major complications were easily controlled. Persistent air-leaks were usually treated conservatively, and only one case (0.44%) required referral to cardiothoracic surgeons. Hypoxemias were transient with a satisfactory response to supplemental oxygen. Pneumonias and empyemas were adequately treated with proper empiric antibiotic course modified according to culture and sensitivity results. Arrhythmias were in the form of sinus tachycardia, which improved by reassurance with no need for pharmacological management. Hypotension episodes were mild and treated by intravenous normal saline infusion. Lung lacerations improved conservatively, while re-expansion pulmonary edema was managed conservatively with no need for neither invasive nor non-invasive ventilation, proving that medical thoracoscopy is a safe and easy to perform maneuver with minimal risks.

Our procedure-related major complications are adherent to those obtained by a large Asian study included 1926 patients, with 662 of them (34.4%) underwent (MT) for diagnostic targets. This study recorded mortality in (0.1%) of the study patients, lung laceration in (0.3%), major bleeding in (0.3%) and re-expansion pulmonary edema in (0.1%) <sup>(22)</sup>. Our results also agree with *de*

*Campos and co-workers* <sup>(26)</sup>, as they concluded that thoracoscopy in the hands of experienced physicians is safe, with large series reporting mortality rates of (<0.1%) and empyema in (2-3%). *Brimms et al.* <sup>(15)</sup> revealed no mortalities nor major bleedings among their 57 patients, which match with our observations. However, they recorded higher rates of hypotension (7%), pneumonia (7%), empyema (3.5%) and persistent air-leak (17.5%). As well, *Ahmed et al.* <sup>(10)</sup> reported no procedure-related deaths nor massive bleedings, pleuro-pulmonary infections in (1.6%), lung laceration in (2.4%) and persistent air-leak in (11%), within 127 patients underwent diagnostic medical thorascopies. *Thomas et al.* <sup>(27)</sup> detected persistent air-leak in (3.7%) out of the 407 patients participated in their study, which is a close figure to ours. On the other side, *Wang and his colleagues* <sup>(24)</sup> registered lower possibilities of hypotension (0.5%) and empyema (0.4%) than those obtained by us.

In our study, the most common minor thoracoscopic complication was post-procedure pain in 74 patients (32.74%), followed by transient air-leak <7 days in 25 patients (11.61%), then post-procedure unexplained fever in 23 patients (10.17%), subcutaneous emphysema in 19 patients (8.4%), post-procedure cough in 17 patients (7.52%), minor intra-pleural hemorrhage in 12 patients (5.3%), operative skin-site infection in 11 patients (4.68%) and subcutaneous hematoma in 8 patients (3.54%).

Likewise major complications, minor complications were simply managed. Pains were treated by non-steroidal anti-inflammatory drugs (NSAIDs). Transient air-leaks were managed conservatively. Fevers responded sufficiently to antipyretics. Subcutaneous emphysemas completely disappeared within ten days, only on oxygen administration with no need for any invasive action. Cough attacks were cured by cough sedatives. Minor intra-pleural bleedings were stopped spontaneously or by direct compression. Operative skin-site infections were responsive for topical and systemic antibiotics and subcutaneous hematomas were treated with cold fomentations for the first 24 hours, followed by warm fomentations after that, side by side with oral anti-edema drugs.

Minor complications met in this study are almost the same as a Chinese study with a total of 833 patients. The later study detected pain in (44%) of the study population, subcutaneous emphysema in (8%), fever in (5.3%) and minor bleeding in (4.6%) <sup>(24)</sup>. Similarly, our observations are very close to those of a small study included 36 patients, which recorded surgical emphysema in (8.3%) of patients, entry-site wound infection in (5.6%) and minor bleeding in (2.8%) <sup>(28)</sup>. Additionally, the results of the current work coincide with those of *Brimms et al.* <sup>(15)</sup>, who reported pain, wound-site infection and surgical emphysema within (15.8%, 7% and 5.3%) of their study

population respectively. Our detections are also in the nearby of a study performed by *Wan et al.* <sup>(22)</sup>, who found pain in (38.9%) of their patients and cutaneous infection at entry site in (7.1%). However, they reported a lower rate of subcutaneous emphysema (3.2%) and a higher rate of post-procedure fever (20.8%) when compared to us. Our rates of minor complications are higher than that recorded by a small Egyptian study with overall 50 patients, which showed infection at drain site in (4%), surgical emphysema in (4%) and transient air-leak in (2%) of patients <sup>(23)</sup>. On the same pathway, a Japanese study reported lower rates of fever and subcutaneous emphysema (3.9% and 0.8% respectively) <sup>(10)</sup> than those revealed in this study.

## CONCLUSION

Medical thoracoscopy is a simple, valuable and safe diagnostic procedure, which carries a limited possibility of complications, most of them are not serious and easy to be controlled.

**Financial support and sponsorship:** Nil.

**Conflicts of interest:** None.

## REFERENCES

- Murthy V, Bessich J (2017):** Medical thoracoscopy and its evolving role in the diagnosis and treatment of pleural disease. *J Thorac Dis.*, 9(suppl 10): S1011-S1021.
- Light R (2006):** The undiagnosed pleural effusion. *Clin Chest Med.*, 27: 309-319.
- Loddenkemper R, Mathur P, Noppen M, Lee P (2011):** Medical Thoracoscopy/Pleuroscopy. Manual and Atlas. Stuttgart and New York, Pbl. Thieme, 8(2): 157-167.
- Seijo L, Sterman D (2001):** Interventional pulmonology. *N Engl J Med.*, 344: 740-749.
- Hooper C, Lee Y, Maskell N (2010):** Setting up a specialist pleural disease service. *Respirology*, 15: 1028-1036.
- Light R (2002):** Clinical practice. Pleural effusion. *N Engl J Med.*, 346: 1971-1977.
- Feller-Kopman D, Reddy C, DeCamp M et al. (2018):** Management of malignant pleural effusions. An official ATS/ STS/STR clinical practice guideline. *Am J Respir Crit Care Med.*, 198: 839-849.
- Medford A, Agrawal S, Bennett J, Free C, Entwisle J (2010):** Thoracic ultrasound prior to medical thoracoscopy improves pleural access and predicts fibrous septation. *Respirology*, 15: 804-808.
- Maturu V, Dhooria S, Bal A et al. (2015):** Role of medical thoracoscopy and closed-blind pleural biopsy in undiagnosed exudative pleural effusions. *J Bronchol Intervent Pulmonol.*, 22: 121-129.
- Ahmed S, Saka H, Mohammadien H et al. (2016):** Safety and complications of medical thoracoscopy. *Advances in medicine*, 10: 1-6.
- Lee P, Mathur P, Colt H (2010):** Advances in thoracoscopy: 100 years since Jacobaeus. *Respiration*, 79: 177-186.
- Alraiyes A, Dhillon S, Harris K, Kaphle U, Kheir F (2016):** Medical thoracoscopy: technique and application. *Pleura*, 3: 1-11.
- Botana-Rial M, Leiro-Fernández V, Represas-Represas C et al. (2013):** Thoracic ultrasound-assisted selection for pleural biopsy with Abram's needle. *Respir Care*, 58(11): 1949-1954.
- Rahman N, Ali N, Brown G et al. (2010):** Local anaesthetic thoracoscopy: British Thoracic Society pleural disease guideline 2010. *Thorax*, 65(Suppl 2): ii54-60.
- Brims F, Arif M, Chauhan A (2012):** Outcomes and complications following medical thoracoscopy. *Clin Respir J.*, 6: 144-149.
- Sobh E, Elsayy S, Ahmed M (2020):** Yield of medical thoracoscopy in undiagnosed exudative pleural effusion: a 3-year retrospective multicenter study. *Al-Azhar Assiut Med J.*, 18: 203-208.
- Baess A, Sweed R (2019):** Experience in medical thoracoscopy: a four-year retrospective study. *Egypt J Bronchol.*, 13: 73-80.
- Ahmed E, Abou Bakr S, Eid H, Shaarawy A, Elsayed W (2017):** Role of ultrasonography in the diagnosis of pleural effusion. *Egypt J Bronchol.*, 11: 120-127.
- Aujayeb A, Jackson K (2020):** A review of the outcomes of rigid medical thoracoscopy in a large UK district general hospital. *Pleura and Peritoneum*, 5(4): 20200131.
- Karkhanis V, Joshi J (2012):** Pleural effusion: diagnosis, treatment and management. *Open Access Emergency Medicine*, 4: 31-52.
- Hassan W, Alkarn A, Kamel M (2015):** Can chest ultrasonography differentiate between benign and malignant effusions? *Egyptian J. Bronchol.*, 9: 165-169.
- Wan Y, Zhai C , Lin X et al. (2019):** Safety and complications of medical thoracoscopy in the management of pleural diseases. *BMC Pulmonary Medicine*, 19: 125.
- Ahmed M, Abdel Halim H, Aziz E, El-Shorbagy R (2016):** Outcomes and complications of medical thoracoscopy in undiagnosed exudative pleural effusion. *Egypt J Bronchol.*, 10: 93-99.
- Wang X, Yang Y, Wang Z et al. (2015):** Efficacy and safety of diagnostic thoracoscopy in undiagnosed pleural effusions. *Respiration*, 90: 251-255.
- Chen R, Zhang Y, Wang J, Wu H, Yang S (2018):** Diagnostic value of medical thoracoscopy for undiagnosed pleural effusions. *Exp Ther Med.*, 16: 4590-4594.
- de Campos J, Vargas F, de Campos Werebe E et al. (2001):** Thoracoscopy talc poudrage: a 15-year experience. *Chest*, 119: 801-806.
- Thomas M, Ibrahim W, Raza T et al. (2017):** Medical thoracoscopy for exudative pleural effusion: an eight-year experience from a country with a young population. *BMC Pulmonary Medicine*, 17: 151.
- Yousef A, Morsi A, El-Shabrawy M, El Shahaat A (2016):** The role of medical thoracoscopy in the diagnosis of exudative pleural effusion at the Chest Department of Zagazig University Hospitals. *Egypt J Bronchol.*, 10: 225-231.