

Enhanced Bone Tendon Healing Using Anatomic Single-Bundle Anterior Cruciate Ligament Reconstruction with Remnant Augmentation

Alaa Mohammed Mohammed Alswiei, Adel Mohammed Salama,

Mohamed Hamed Fahmy Afifi, Hossam Fathi Mahmoud Mohamed

Department of Orthopedic Surgery, Faculty of Medicine, Zagazig University, Sharkia, Egypt

Corresponding Author: Alaa Mohammed Mohammed, Email: alaaswei1@gmail.com

ABSTRACT

Background: When dealing with anterior cruciate ligament (ACL) tears, anatomic single-bundle reconstruction with remnant-preserving method offers numerous advantages, including enhanced revascularization and graft ligamentization, prevention of synovial fluid bath to the tunnels, and enhanced bone tendon healing

. **Objective:** assess the efficacy and outcome of anatomic single-bundle reconstruction with remnant-augmenting technique in patients with an ACL tear.

Patients and Methods: At the Orthopedic Departments of Zagazig University hospital, 18 patients with complete ACL damage were studied in prospective cohort research. The study was carried out from 2-11/2021. All patients received an anatomic single-bundle reconstruction using a remnant-preserving approach, and all patients were periodically monitored clinically and radiographically for a week, then every 2, 4, 6, and 12 weeks after the index procedure. **Results:** 33.3% of studied patients were complicated; superficial Infection was in 27.8%, Failure was just in one case and stiffness 2 cases only there were no other complications. VAS was significantly higher among complicated cases at the post but Lysholm knee score was significantly lower at pre and post and regard IKDS was significantly lower at post only.

Conclusion: Patients with ACL tears benefit more from anatomic single-bundle restoration using the remnant-augmenting method, which improves proprioceptive functions, stability, and healing of the graft.

Keywords: Anterior Cruciate Ligament Reconstruction, Anatomic Single-Bundle, Remnant Augmentation.

INTRODUCTION

One of the most common orthopedic sports injuries, anterior cruciate ligament rupture has an incidence rate of thirty to eighty in each one hundred thousand, according to a 21-year population-based study⁽¹⁾.

The gold standard treatment for anterior cruciate ligament (ACL) ruptures is arthroscopically assisted anterior cruciate ligament (ACL) reconstruction. help restore knee stability, regain pre-injury sports ability, and prevent meniscal or chondral injury as well as osteoarthritis⁽²⁾.

The anteromedial (AM) and the posterolateral (PL) bundles of the functional ACL are two separate sections. The rebuilt ACL graft's anatomical placement has equivalent forces to the normal ACL. A normal anatomical repair is the ultimate goal of the various ACL reconstruction procedures⁽³⁾.

The single-bundle approach for ACL reconstruction has long been the standard treatment because of its excellent clinical outcomes. Double-bundle ACL surgery has gradually replaced single-bundle ACL reconstruction in recent years. This technique is regarded to be superior in theory to the single-bundle technique in ACL reconstruction⁽⁴⁾.

Although the double-bundle technique has better results in terms of rotational laxity, the most recent meta-analyses have shown no significant difference between the two techniques in terms of functional recovery. Single-bundle ACL reconstruction is still the most often utilized procedure, as its clinical outcomes have improved over time⁽⁵⁾.

Neuromuscular coordination is dependent on proprioceptive input since it affects the knee and ACL's biomechanical function. The precise complicated interplay between the neurological and musculoskeletal systems is critical to restoring knee function following an ACL injury, not just surgical methods⁽²⁾.

In addition to the ACL's tibial connection, the synovium's inner membrane contains mechanoreceptors that mediate knee proprioception. Remaining mechanoreceptors can be discovered in the stump of a torn ACL, attached to the posterior cruciate ligament, three years following ACL rupture, according to Georgoulis et al findings. 's Because of this, it is important to preserve as much of the original tissue as possible, even in the case of chronic injuries⁽⁶⁾.

Studies have shown the advantages of anatomic single-bundle reconstruction with remnant-preserving technique, including enhanced revascularization and graft ligamentization, improved bone tendon healing, prevention of synovial fluid bath to the tunnels, preservation of proprioceptive cells as well as early rehabilitation. This method also makes it easier to arrange the tunnels accurately, compared to the usual method. However, the procedure is more difficult to perform because of the higher incidence of impingement and cyclops lesions⁽⁷⁾.

An anatomical single-bundle reconstruction using a remnant-augmenting approach to increase ACL stability, graft healing, proprioceptive functions, and clinical results are the objectives of this study.

PATIENTS AND METHODS:



This article is an open access article distributed under the terms and conditions of the Creative Commons Attribution (CC BY-SA) license (<http://creativecommons.org/licenses/by/4.0/>)

At the Orthopedic Departments of Zagazig University hospital, 18 patients with complete ACL damage were incorporated in prospective cohort research, the study was carried out from 2-11/2021.

Ethical Considerations:

Approval of the study was obtained from the Zagazig University academic and ethical committee (ZU-IRB#6660). Every patient signed informed written consent for the acceptance of the operation. This work has been carried out following The Code of Ethics of the World Medical Association (Declaration of Helsinki) for studies involving humans.

Inclusion criteria: Patients aged more than 18 years, physical examination and MRI confirmed the presence of a partial ACL injury, patient's ACL that was more than half intact, bridging the tibia/femur and not more than half of its length was found to be intact by arthroscopic evaluation. The PL bundle contained the ACLs that had been ruptured, while the AM bundle had the ones that had not been damaged, Normal alignment, normal contralateral knee.

Exclusion criteria: Patients having radiographic evidence of degenerative alterations (joint space narrowing) and chondral injury of Grade 3-4, Instabilities in the rotation Patients who have had a meniscal injury should seek immediate medical attention. In patients with a history of previous surgeries on the knee or a fracture around the knee, combined ligamentous injuries, and clinical signs of mal alignment (valgus or varus).

This is what all of the participants in this research had to go through:

1. A thorough review of the patient's medical history and an orthopedic examination.
2. X-rays; Injured and normal knees before and after reconstruction are shown in AP and lateral views.
3. For confirmation of the ACL tear and exclusion of any additional knee ailments, the knee was scanned with a magnetic resonance imaging (MRI) machine following the ACL reconstruction procedure.
4. All patients had full preoperative lab investigation before surgery including:
Complete blood picture, Random blood sugar, Viral screen, Coagulation studies (PT/PTT) as well as Kidney and liver function tests.
5. **Evaluation according to rating scales:** When assessing subjective factors in this study, the Lysholm knee score was used. When assessing objective criteria, the IKDC knee assessment form was employed ⁽⁸⁾.
6. **The IKDC rating scale:** The International Knee Documentation Committee (IKDC) uses a four-

tiered rating scale to classify patients based on seven sets of characteristics ⁽⁹⁾.

7. Surgical technique:

An intravenous cephalosporin was used to provide broad-spectrum antibiotics before anesthetic induction. Depending on the patient's condition, either spinal or general anesthesia was used.

The proximal thigh of the patient was locked in a leg restraint supine posture. Anterolateral and anteromedial (AM) portals were established using the leg-drop posture and regular arthroscopy was conducted with 90 degrees of knee flexion.

The semitendinosus and gracilis tendons were extracted through a tiny incision located 2 cm medial to the tibial tubercle after an arthroscopic evaluation and treatment of probably related pathologies. After harvesting, each graft was folded in half and put together with whip-stitched sutures. Tightening and lengthening each tendon was accomplished by passing them into an adjustable block.

Arthrex drill guides with marking hooks for tibial tunnel preparation make it easy to create one that's the same diameter as your hamstring graft. This pin's intra-articular extrusion point is aimed directly at the tibial insertion site, the midpoint of medial and lateral intercondylar eminence midlines. Using a marking hook, a cannulated reamer, and a 3.2-mm guidewire, the tibial insertion site is marked and reaming is carried out. The millimeter-by-millimeter tunnel was drilled under arthroscopy supervision. Shaver and thermal device were used to debride and expose AM and PL bundles' anatomical attachment points on the distal end of the remaining bone stump. For the placement of the femoral tunnel, the AM and PL footprints are separated at the femoral attachment by the lateral intercondylar ridge and the lateral bifurcate ridge. Between the AM and PL marks, a femoral tunnel mark is next inserted. This procedure is carried out by inserting an instrument known as FlipCutter into the joint through an instrument known as an anterograde guide tube. A probe is used to rotate the blade 90 degrees into the cutting position, and the blue hub is spun clockwise to lock it in place. To a depth of 25 mm, a retrograde force is used to continue forward drilling. The tibial tunnel is used to collect the looped wire from the joint. Two leading sutures are used to transmit the 4-stranded autogenous hamstring graft from the tibial tunnel to the femoral tunnel. The graft is pre-tensioned once it has been inserted. This procedure involves the use of two bioabsorbable interference screws, as well as a spiked washer and screw.

Lysholm knee score and IKDC 2000 were used to monitor all patients for two years. Additionally, a knee X-ray (AP and lateral) was taken to evaluate the knee's tunnel position and the progression of degenerative alterations.

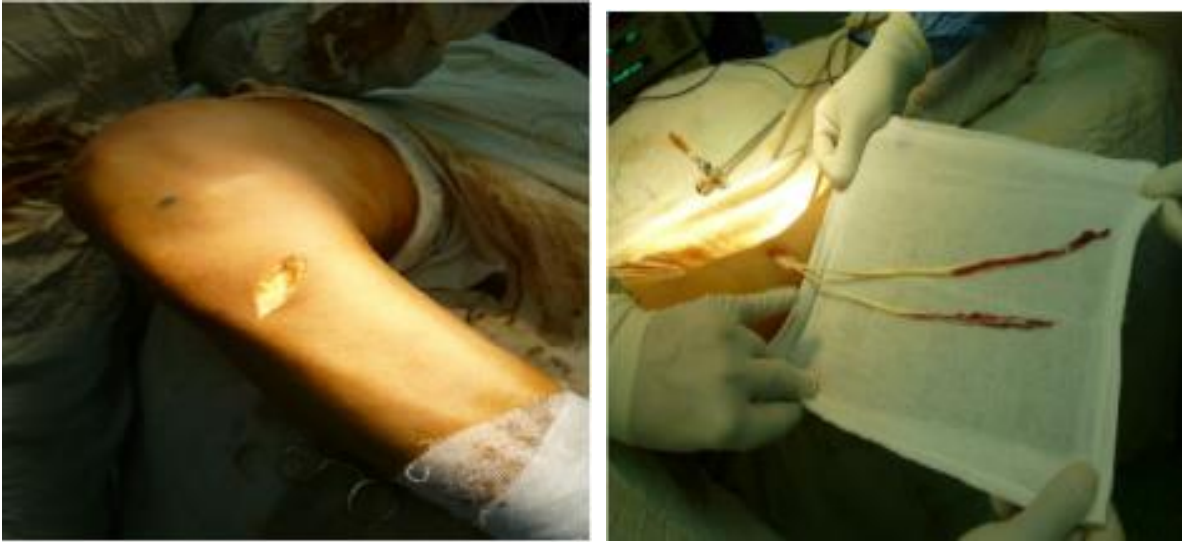

Fig. (1): Harvesting the tendons

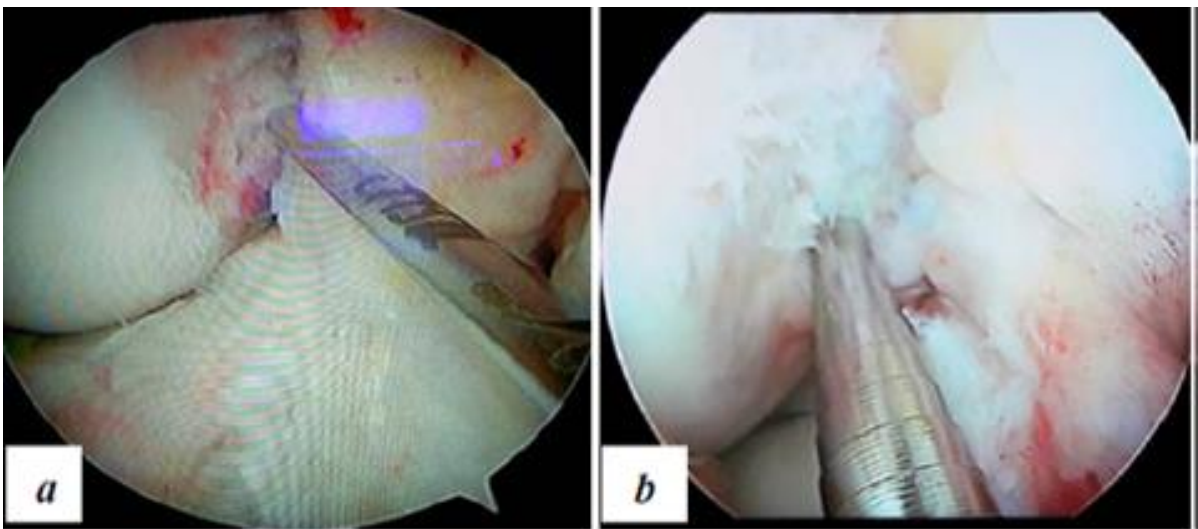


Fig. (2): a, b, Drilling for a femoral tunnel was done in this knee's medial portal, and this picture shows where it was done

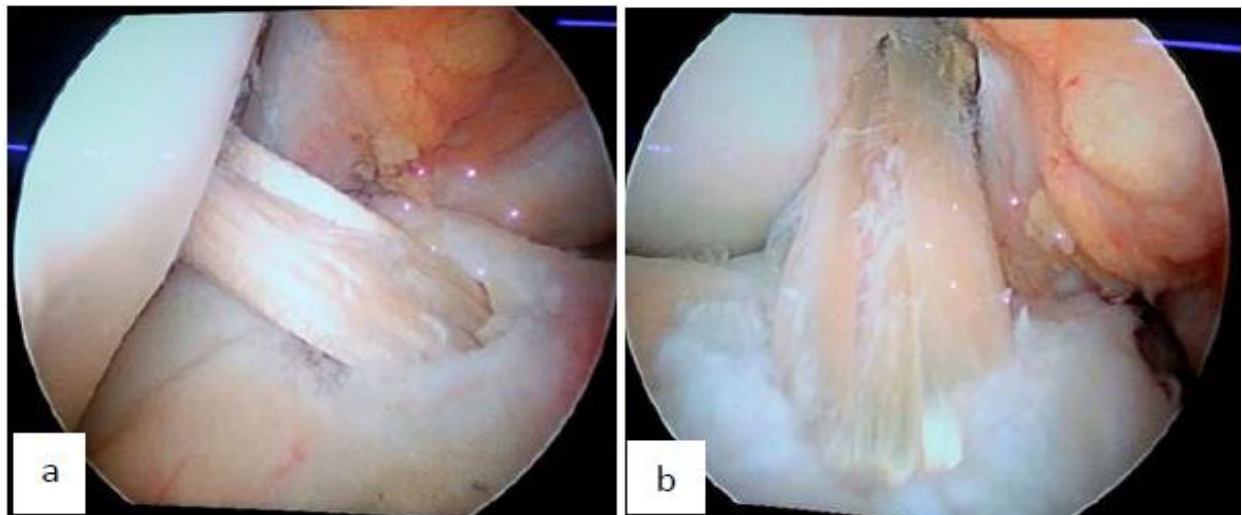


Fig. (3): a: view from the anterolateral portal after tibial fixing of the graft. b: Post-tibial fixation graft medial portal views.

Statistical analysis:

To analyze the data acquired, it was loaded into a computer and run via the Statistical Package of Social Services, version 20. (SPSS). Tables and graphs were used to present the findings. The Shapiro–Wilk test was used to examine the distribution properties of variables as well as the homogeneity of variance. The quantitative data was reported in the form of the mean, median, standard deviation, and confidence interval. The frequency and proportions of qualitative data were used to present the information. For quantitative independent data, the student’s t-test (T) and the Mann-Whitney test (MW) were employed to examine the data as needed. To examine qualitatively independent data, researchers employed the Pearson Chi-Square Test and the Chi-Square for Linear Trend (χ^2). P-value equals or less than 0.05 was considered significant.

RESULTS

Age ranged from 18 to 50, with a 36.057.47 distribution. Males accounted for 72.2 percent of the total sex population. There were 55.6 percent of right-side injuries and 44.4 percent of left-side injuries; the majority of these injuries were sports-related, and 44.4 percent were related (Table 1).

VAS significantly decreased but LYSHOLM and IKDS significantly increased from pre to post (Table 2).

Superficial Infection was in 27.8%, failure just in one case and stiffness 2 cases only. 33.3% of studied patients were complicated (Table 3).

VAS was significantly higher among complicated cases at the post, but LYSHOLM was significantly lower at pre and post and regard IKDS was sig lower at post only (Table 4).

Table (1): The study group's age and sex composition and injury characters among studied patients

		Age	
Mean± SD		36.05±7.47	
Median (Range)		36.5 (18-50)	
		N	%
Sex	Male	13	72.2
	Female	5	27.8
	Total	18	100.0
		N	%
Side	Left	8	44.4
	Right	10	55.6
Mechanism	FALL	5	27.8
	RTA	2	11.1
	Sport	11	61.1
Associated injury	-VE	10	55.6
	+VE	8	44.4
	Total	18	100.0

Table (2): VAS, LYSHOLM, and IKDS distributed pre and post among the studied group

	Pre	Post	Paired t	P
VAS	5.94±1.43	1.21±0.41	10.703	0.00**
LYSHOLM	67.5±7.52	89.72±6.52	15.119	0.00**
IKDS	68.33±7.07	88.05±8.59	9.667	0.00**

Table (3): Complication distributed among the studied group

		N	%
Superficial Infection	-VE	13	72.2
	+VE	5	27.8
Failure	-VE	17	94.4
	+VE	1	5.6
Stiffness	-VE	16	88.9
	+VE	2	11.1
	Total	18	100.0
		N	%
Overall complication	Non	12	66.7
	Complicated	6	33.3
	Total	18	100.0

Table (4): Relation with Complication

			Non complicated	Complicated	t/ X2	P
Age			36.25±8.99	35.66±3.38	0.152	0.881
Interval surgery			3.41±0.9	3.0±1.09	0.863	0.401
Hospital stay			2.66±0.65	2.33±0.51	1.089	0.292
VAS pre			6.25±1.6	5.33±0.81	1.305	0.210
VAS post			0.65±0.23	2.0±0.75	4.000	0.001**
LYSHOLM PRE			70.0±7.38	62.5±5.24	2.209	0.042*
LYSHOLM POST			92.91±2.57	83.33±7.52	4.062	0.001**
IKDS Pre			70.41±7.52	64.16±3.76	1.898	0.076
IKDS POST			92.91±3.34	78.33±7.52	5.788	0.00**
Sex	Male	N	8	5		
		%	66.7%	83.3%		
	Female	N	4	1	0.55	0.45
		%	33.3%	16.7%		
Side	Left	N	5	3		
		%	41.7%	50.0%		
	Right	N	7	3	0.11	0.73
		%	58.3%	50.0%		
Mechanism	FALL	N	4	1		
		%	33.3%	16.7%		
	RTA	N	2	0	2.12	0.34
		%	16.7%	0.0%		
	sport	N	6	5		
		%	50.0%	83.3%		
Associated injury	No	N	5	5		
		%	41.7%	83.3%		
	Yes	N	7	1	2.81	0.094
		%	58.3%	16.7%		
Total		N	12	6		
		%	100.0%	100.0%		

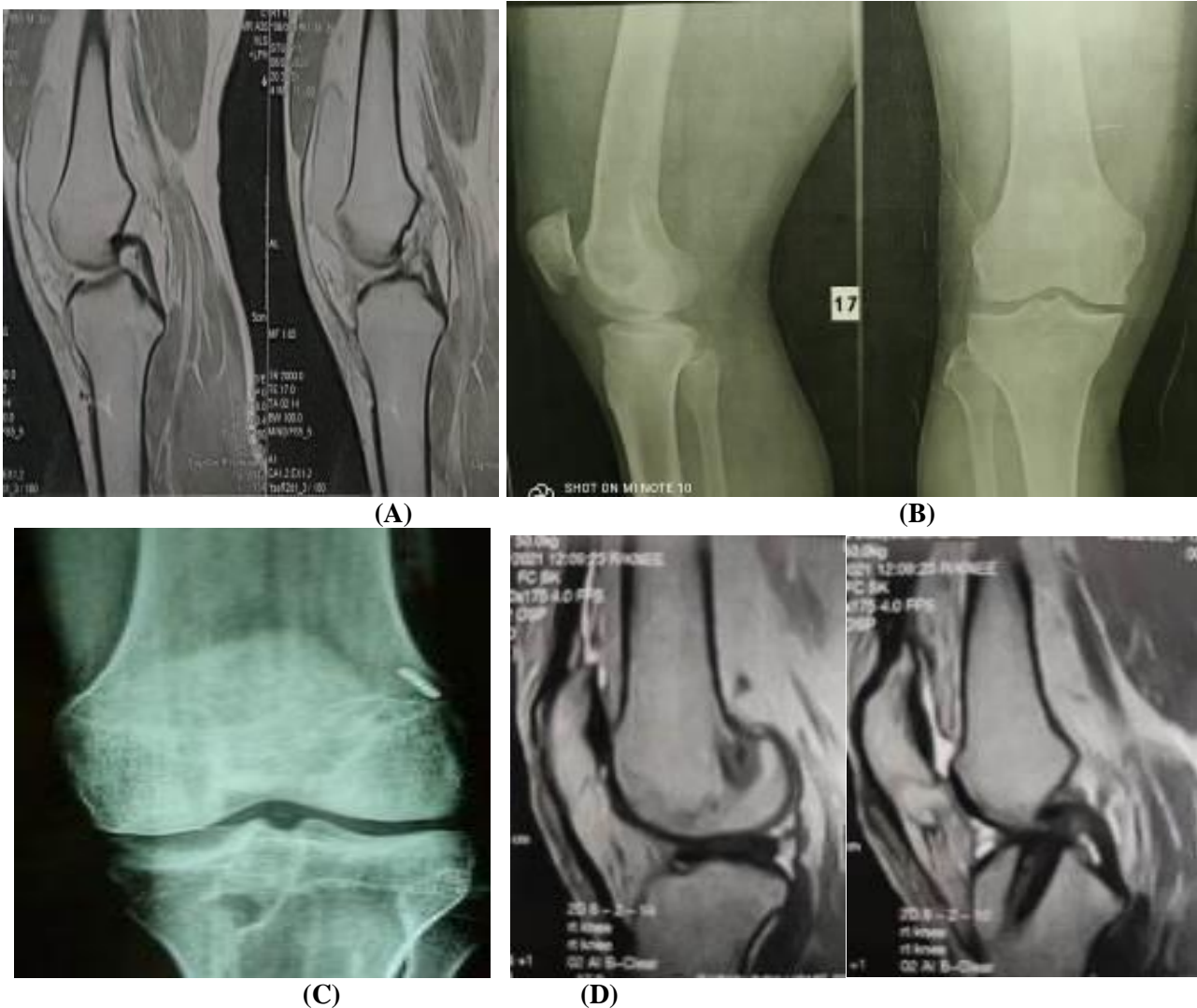


Fig. (3): A 41 years old male, who is a teacher, complained of recurrent giving way of right knee following indirect twisting knee trauma during sport 24 months preoperatively he sought medical treatment but didn't improve. A) Preoperative X-ray AP and lateral views. B) Sagittal MRI, C) X-ray showing position of the femoral and tibial tunnel, D) Postoperative Sagittal MRI.

DISCUSSION

Preservation of the ACL remnant as a biosleeve for the graft is important from the standpoint of accelerating the healing process, maintaining the proprioceptive nerve fibers, improving the biological environment for healing, and maintaining the anchor point at the native tibial attachment in addition to yielding a lower incidence of bone tunnel enlargement, as well as lessening the risk of bone tunnel infection. In our procedure, we are attempting to take advantage of some of the advantages of preserving the ACL's tibial remnant through an anatomic single-bundle ACL reconstruction⁽¹⁰⁾.

The average age of the participants in this study was found to be 36.05 ± 7.47 at least 18 years old, and no older than 50 years old. Males accounted for 72.2 percent of the total sex population, which is in agreement with the study of **Sonnery-Cottet et al.**⁽¹¹⁾ who found that the mean age was $30 + 10.2$ years, they were 22 (56.4%) males and 17 females (43.6%). **Kim et al.**⁽¹²⁾ found that the mean age for the single-bundle

reconstruction with remnant Group (n = 44) was 29.8 ± 5.4 , they were 34 (77.23%) males and 10 (22.77%) females.

According to the results of this study, 55.6 percent of the injuries were sports-related, whereas 44.4 percent had an accompanying injury. There were 16 cases (58.3%) with a right ACL tear and 8 cases (33.3%) with a left ACL injury, in agreement with **Megahed et al.**⁽¹³⁾. More than half of the people evaluated had additional injuries, with 14 of the patients being sport-related (58.3%), seven being RTA (29.9%), and three being a fall downstairs (12.5%).

The current study showed that the VAS significantly decreased but LYSHOLM and IKDS significantly increased from pre to post. **Sonnery-Cottet et al.**⁽¹¹⁾ found that significant differences were found between preoperative and postoperative subjective and objective IKDC evaluations ($P < .01$), Lysholm score ($P < .001$).

Park et al.⁽¹⁴⁾ reported that preoperatively, the VAS scores were 4.6 ± 2.0 in the Aug group, and

postoperatively it was 1.9 ± 1.0 and. These results indicate that there was a highly significant difference in the VAS pre and postoperatively. Preoperatively, the Lysholm scores Preoperatively were 48.6 ± 9.7 in the Aug group, Postoperatively, it was 88.3 ± 4.9 with a highly significant difference in the Lysholm pre and postoperatively. Preoperatively, the IKDC subjective knee evaluation form scores were 47.1 ± 16.3 in the Aug group and 83.3 ± 8.4 Postoperatively.

Huang et al. ⁽¹⁵⁾ reported that in Remnant preservation the mean IKDC score was 92.3 ± 8.5 postoperatively with a highly significant difference in the Lysholm pre and postoperatively.

Kim et al. ⁽¹²⁾ reported that the preoperative mean IKDC subjective score was 49.8 ± 16.3 and it was 72.5 ± 18.5 post-operative with a highly significant difference in the IKDC subjective score pre and postoperatively.

Total LYSHOLM score improved greatly from 54.33 ± 14.04 to 94.37 ± 8.14 as reported by **Megahed et al.** ⁽¹³⁾ **Fahmy et al.** ⁽¹⁶⁾ observed that the pre and post total mean for the lysholm score indicated a highly significant improvement from the preoperative-to-post operative total mean (53 ± 13) and (93.4 ± 16.8) respectively.

IKDC SCORE improved significantly in the current trial from 45.83 ± 7.46 to 78.12 ± 6.04 . Also, Improving the IKDC SCORE considerably for the anatomic single-bundle group was reported by **Hussein et al.** ⁽¹⁷⁾.

Morey et al. ⁽¹⁸⁾ found that the subjective improvement of the IKDC compared to preoperative values was highly significant (52.4 ± 7.2 vs 92.8 ± 6.2) with P-value < 0.001 .

The current study showed that 33.3% of studied patients were complicated; superficial Infection was in 27.8%, Failure just in one case and stiffness 2 cases only there were no other complications, according to **Megahed et al.** ⁽¹³⁾, there were five cases (or 20.8%) that were difficult (1 case had a deep infection and 4 cases had a superficial infection). One patient had an intraoperative lateral femoral cortical blowout, which was documented by **Fahmy et al.** ⁽¹⁶⁾ in their study (3.3 percent). One patient developed a superficial wound infection at the graft site after surgery (3.3 percent). Also, a tourniquet neuropraxia occurred in a single instance (3.3 percent). Finally, two cases of postoperative saphenous nerve neuropraxia have been reported (6.6 percent). **Gundavarapu and colleagues** ⁽¹⁹⁾ found that The only serious consequence they encountered was a surface infection in three patients (7.5 percent). 3 patients (7.5 percent) were unable to regain their movement after the procedure.

The current study showed that VAS was significantly higher among complicated cases at the post, but LYSHOLM was significantly lower at pre and post and regard IKDS was sig lower at post only

Complex patients had higher VAS scores at post-treatment, according to **Barenius, and colleagues** ⁽²⁰⁾.

According to Kim and colleagues ⁽¹²⁾, the Lysholm score was lower in complicated patients before and post, but the difference was not statistically significant, whereas the IKDC score showed a significant difference between complicated patients pre and after management.

CONCLUSION

Patients with ACL tears benefit more from anatomic single-bundle restoration using the remnant-augmenting technique, which improves stability, graft healing, and proprioceptive functions are more effective in terms of re-creating the ACL's architecture and achieving acceptable clinical outcomes.

Financial support and sponsorship: Nil.

Conflict of interest: Nil.

REFERENCES

1. **Sanders T, Kremers M, Bryan H et al. (2016):** Incidence of anterior cruciate ligament tears and reconstruction: a 21-year population-based study. *The American Journal of Sports Medicine*, 44: 1502-1507.
2. **Apivatgaroon A (2018):** Anatomic Single-Bundle ACL Reconstruction with Remnant Augmentation Technique. <https://www.intechopen.com/chapters/61094>
3. **Golan E, Meredith S, Nakamura T et al. (2019):** Anatomic reconstruction of anterior cruciate ligament: concept, indication and its efficacy. *Annals of Joint*, 4: 1-5.
4. **Chen H, Chen B, Tie K et al. (2018):** Single-bundle versus double-bundle autologous anterior cruciate ligament reconstruction: a meta-analysis of randomized controlled trials at 5-year minimum follow-up. *Journal of Orthopaedic Surgery and Research*, 13(1): 1-12.
5. **Zaffagnini S, Di Sarsina T, Grassi A et al. (2017):** "Over the Top" Single-Bundle ACL Reconstruction with Extra-articular Plasty. In: *Rotatory Knee Instability*. Springer, Cham. Pp. 331-340.
6. **Sha L, Xie G, Zhao S et al. (2017):** morphologic and quantitative comparison of mechanoreceptors in the tibial remnants of the ruptured human anterior cruciate ligament. *Medicine*, 96: 5-9.
7. **Mayr H, Bruder S, Hube R et al. (2018):** Single-bundle versus double-bundle anterior cruciate ligament reconstruction—5-year results. *Arthroscopy: The Journal of Arthroscopic & Related Surgery*, 34(9): 2647-2653.
8. **Ahmed K, Said H, Ramadan E et al. (2019):** Arabic translation and validation of three knee scores, Lysholm knee score (LKS): Oxford knee score (OKS): and International Knee Documentation Committee Subjective Knee Form (IKDC). *SICOT J.*, 5: 6-11.
9. **Huang C, Chen W, Tsai M et al. (2017):** Comparing the Chinese versions of two knee-specific questionnaires (IKDC and KOOS): reliability, validity, and responsiveness. *Health and Quality of Life Outcomes*, 15(1): 1-10.
10. **Lee B, Kwon S, Choi H et al. (2015):** Anatomic single-bundle anterior cruciate ligament reconstruction with remnant preservation using an outside-in technique. *Arthroscopy Techniques*, 4(4): 331-334.
11. **Sonnery-Cottet B, Zayni R, Conteduca J et al.**

- (2013): Posterolateral bundle reconstruction with anteromedial bundle remnant preservation in ACL tears: Clinical and MRI evaluation of 39 patients with 24-month follow-up. *Orthopaedic Journal of Sports Medicine*, 1(3): 232-236.
12. **Kim S, Jung Y, Song M *et al.* (2014):** Comparison of double-bundle anterior cruciate ligament (ACL) reconstruction and single-bundle reconstruction with remnant pull-out suture. *Knee Surgery, Sports Traumatology, Arthroscopy*, 22(9): 2085-2093.
13. **Megahed R, Mahmoud H, Farhan A (2021):** Arthroscopic anatomic single-bundle anterior cruciate ligament reconstruction using hamstring tendon. *European Journal of Molecular & Clinical Medicine*, 8(03): 1-5.
14. **Park S, Oh H, Park S *et al.* (2012):** Clinical outcomes of remnant-preserving augmentation versus double-bundle reconstruction in the anterior cruciate ligament reconstruction. *Arthroscopy: The Journal of Arthroscopic & Related Surgery*, 28(12): 1833-1841.
15. **Huang H, Nagao M, Nishio H *et al.* (2021):** Remnant preservation provides good clinical outcomes after anterior cruciate ligament reconstruction. *Knee Surgery, Sports Traumatology, Arthroscopy*, 21: 1-10.
16. **Fahmy F, Abd El Fatah Kotb H, El-Elesh A (2015):** Arthroscopic Anatomic Single Bundle Anterior Cruciate Ligament Reconstruction. *British Journal of Science*, 12 (2): 89-97.
17. **Hussein M, van Eck C, Cretnik A *et al.* (2012):** Prospective randomized clinical evaluation of conventional single-bundle, anatomic single-bundle, and anatomic double-bundle anterior cruciate ligament reconstruction: 281 cases with 3-to 5-year follow-up. *The American Journal of Sports Medicine*, 40(3): 512-520.
18. **Morey V, Nag H, Chowdhury B *et al.* (2015):** A prospective comparative study of clinical and functional outcomes between anatomic double-bundle and single-bundle hamstring grafts for arthroscopic anterior cruciate ligament reconstruction. *International Journal of Surgery*, 21: 162-167.
19. **Gundavarapu A, Kumar M, Singh V *et al.* (2020):** Study of functional outcome following arthroscopic anatomical ACL reconstruction using an autologous hamstring graft. *International Journal of Orthopaedics*, 6(4): 867-871.
20. **Barenius B, Ponzer S, Shalabi A *et al.* (2014):** Increased risk of osteoarthritis after anterior cruciate ligament reconstruction: a 14-year follow-up study of a randomized controlled trial. *The American Journal of Sports Medicine*, 42(5): 1049-1057.