

Indications, Creation, and Complications of Colostomy in Neonates: Single Tertiary Center Experience Over Three Years

Mohamed M. Shalaby

Pediatric Surgery Department, Tanta University, Egypt

*Corresponding Author: Mohamed Mahmoud Shalaby, Mobil: 00201064665637, Email: mohamedmshalaby@gmail.com

ABSTRACT

Background: The congenital anomalies that indicate colostomies in neonates at any tertiary paediatric surgery centre are Hirschsprung's disease, anorectal anomalies, and colonic atresia and they constitute the main bulk of colostomy workloads.

Objective: In this study, we aimed to evaluate the indications, site of creation, type of colostomy, and complications of colostomy in new-born in the last three years in a single tertiary center.

Patients and Methods: This study was a retrospective cohort study that was carried out in the Paediatric Surgery Department, Tanta University Hospital, Egypt to evaluate the indications, site of creation, types of colostomies, and complications of colostomy in new-born over three years from March 2018 to March 2021.

Results: High anorectal malformations (90%) and Hirschsprung's disease (5%) were the most common causes of creation of neonatal colostomy. Out of 120 neonates, 71 (59 %) patients were males, and 49 (41 %) patients were females. The gestational age ranged between 35 and 40 weeks with a mean of 37.55 ± 1.43 weeks (mean \pm SD). Complications of colostomy were seen in 38 (31.6%) neonates. Most common complications were skin excoriation in 22 (18 %) patients, stomal prolapse in 5 (4%) patients, bleeding from stoma site in 4 (3%) cases, wound infection in 3 (2.5%) cases, parastomal hernia in 2 (1.6%) patients, and dehiscence and stomal stenosis in one (0.8%) patient for each.

Conclusions: Expert paediatric surgeons should perform or assist in colostomy creation operations in neonates and should pay close attention to proper choice of the site of colostomy with early management of complications and early closure of the colostomy.

Keywords: Anorectal malformation, Colostomy, Hirschsprung's disease, neonates.

INTRODUCTION

A stoma is defined as surgical procedure made in the intestine to convert faeces and flatus to outside. The congenital indications for colostomies in neonates at any tertiary paediatric surgery center are Hirschsprung's disease, anorectal anomalies, and colonic atresia and this constitutes the main bulk of colostomy workloads⁽¹⁻³⁾.

The primary goal of colostomy surgery is to divert stool until the time for the specific definitive treatment. The site and the type of the least troublesome stoma have been major subjects for discussion amongst podiatric surgeons. Clinical studies have established the high morbidity associated with neonatal colostomy and that transverse colostomy has a higher rate of complications than sigmoid colostomy^(4,5).

However, debate continues regarding the type of the diverting colostomy and despite being the most performed procedure in children; few research has been reviewed this subject. In this study, we aimed to evaluate the indications, site of creation, type of colostomy, and complications of colostomy in new-borns in the last three years in a single tertiary center.

PATIENTS AND METHODS

This study is a retrospective cohort study that was carried out in the Paediatric Surgery Department, Tanta University Hospital, Egypt. The study included all the neonates who underwent colostomy that were done by well-trained paediatric surgeons in that period over the last three years from March 2018 to March 2021.

We excluded the neonates with extreme low birth weight or with congenital severe medical illness, which were incompatible with life. Patients' medical records including the detailed demographic and clinical data, the physical examination, and the relevant investigations for the studied patients were recorded.

Preoperative management were done based on the congenital anomalies; invertogram film was done after 24-48 hours of birth for high anorectal malformations, colostomy was performed only in obstructed Hirschsprung cases as trans-anal pull through was the main method for Hirschsprung disease. The type of colostomy, site of colostomy creation, its complications, and the operative time were recorded for each patient.

All the studied patients started feeding once colostomy was functioning except with any contraindication for feeding and according to the general condition of the patients. All patients started intravenous antibiotics for 24-48 hours post colostomy creation. All the colostomies' new-born babies with failure to thrive were admitted for nutritional rehabilitation by supplementary feeding under care of paediatric nutritionist. Follow up for colostomies patients after hospital discharge was achieved at the out-patient clinic every 2 weeks till closure of colostomy.

Ethical consent:

An approval of the study was obtained from Tanta University Academic and Ethical Committee.

Every parent of every patient signed an informed

This article is an open access article distributed under the terms and conditions of the Creative Commons Attribution (CC BY-SA) license (<http://creativecommons.org/licenses/by/4.0/>)



written consent for acceptance of the operation. This work has been carried out in accordance with The Code of Ethics of the World Medical Association (Declaration of Helsinki) for studies involving humans.

Statistical analysis

The collected data were coded, processed, and analysed using the SPSS (Statistical Package for the Social Sciences) version 22 for Windows® (IBM SPSS Inc, Chicago, IL, USA). Quantitative data were presented as mean and standard deviation (SD), while qualitative data were presented as frequency and percentage.

RESULTS

High anorectal malformations (90%) and Hirschsprung’s disease (5%) were the most common causes of creation of neonatal colostomy (Table 1).

Table (1): Indications of colostomy.

Indication:	N= (120) %
High anorectal malformation	108 (90%)
Hirschsprung’s disease	6 (5%)
Colonic atresia	3 (2.5%)
Vestibular anus	3 (2.5)

Out of 120 neonates, 71 (59 %) patients were males, and 49 (41 %) patients were females. The gestational age ranged between 35 and 40 weeks with a mean of 37.55 ± 1.43 weeks (mean ± SD).

Twenty-three (19%) cases were preterm (less than 37 weeks) and 97 (81%) cases were full term (between 37 and 42 weeks). None of our cases were post term (more than 42 weeks). Birth weight ranged between 1700 and 3400 grams with a mean of 2945.6 ± 446.3 grams (mean ± SD). No cases had very low birth weight (less than 1500 grams) as it was excluded from the start, 13 (10.8%) cases had low birth weight (between 1500 and 2499 grams), and 107 (89.2%) cases had average birth weight (between 2500 and 4000 grams). No cases were overweight (more than 4000 grams). Operative time ranged between 38 and 55 minutes, with a mean of 43.05 ± 6.23 minutes (mean ± SD). Divided colostomy was performed in 64 (53.3%) cases and loop colostomy were performed in 56 (46.7%) cases. All created colostomies were done at the level of sigmoid colon (sigmoid colostomy).

The complications of the operations are shown in table 2.

Table (2): Complications of colostomies.

Complications:	N= (120 patients) %
Parastomal skin excoriation	22 (18 %)
Stomal bleeding	4 (3%)
Stomal prolapse	5 (4%)
Wound infection	3 (2.5%)
Parastomal hernia	2 (1.6%)
Stomal stenosis	1 (0.8%)
Wound dehiscence	1 (0.8%)

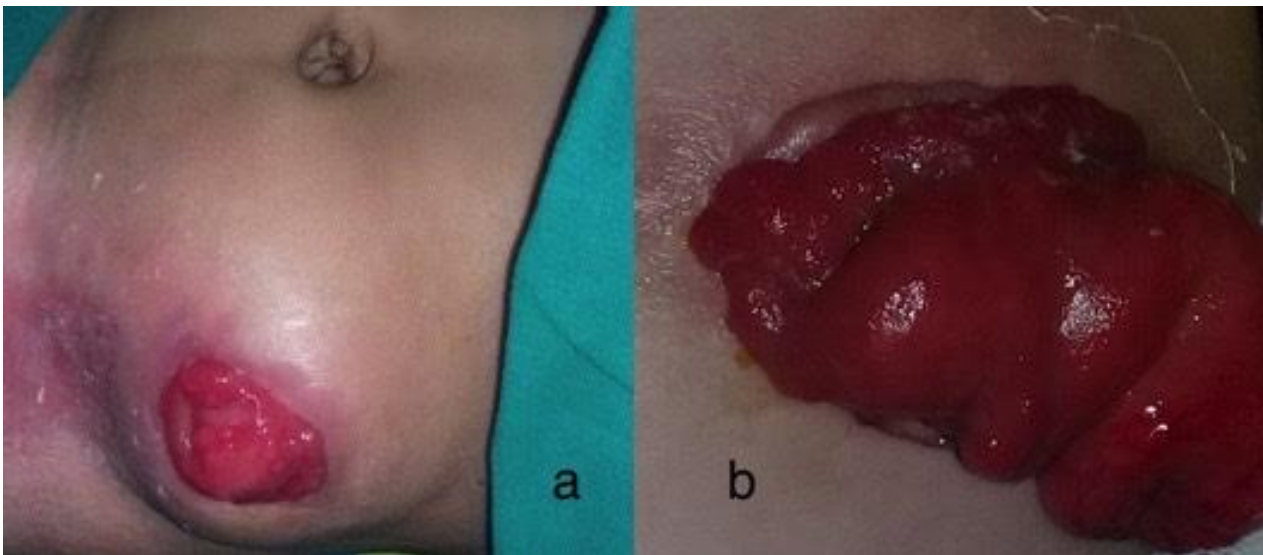


Figure (1): Complication of colostomies. (a) parastomal hernia (b) prolapse.

DISCUSSION

As colostomy is a life-saving operation that is highly indicated in some neonatal surgical emergencies, we decided to focus on reviewing the indications, types, site, and complications of colostomy in Tanta University Hospital in last three years.

In this study the main indication for colostomy creation was the high anorectal malformation that represented about 90% of the performed colostomy creation operations. This agrees with the reports of **Millar *et al.*** ⁽⁶⁾, from South Africa, over 90% of neonatal colostomies were performed for large bowel obstruction from Hirschsprung's disease or anorectal anomalies. Although, colostomy is a common paediatric surgery procedure, it may be associated with morbidity and mortality ⁽⁴⁾. The most common complications of colostomy are peristomal dermatitis, parastomal hernia, loss of bowel and stricture scar of colostomy ^(7,8). The worldwide incidence of colostomy-related complications and morbidity has been reported to be high and ranged from 28-74% in various studies ⁽⁹⁻¹¹⁾.

In this study we performed 107 (89.2%) cases with an average birth weight (between 2500 and 4000 grams) and we excluded the extreme low birth weight because they would be associated with high rate of complications that may be unrelated to colostomy creation morbidity. In our current study, complications of colostomy were reported in 38 (31.6%) neonates.

Complications of colostomy creation were less because well trained senior staff was responsible for neonatal colostomy performance either by operating the case or assistance of junior pediatric surgeons. The most common complication in this study was parastomal skin excoriation that was recorded in 18 (45%) patients. The causes for a high incidence of skin excoriation in the study were due to poor care of our patients with colostomy as most of these patients were uneducated and were from remote areas. Dressing and local ointment (petroleum jelly and zinc oxide) was advised to all patients. Stomal prolapse was reported in 5 (4%) patients and affected mostly the distal limb as the distal limb was mostly dilated and hypertrophied especially in Hirschsprung's disease.

Local stoma bleeding occurred in 4 (3%) of our patients and was due to sepsis and jaundice, however it was managed with compression dressing. A parastomal hernia was developed in two patients (1.6%) and occurred due to the poor abdominal wall muscle with the local infection. Stomal stenosis occurred in one patient (0.8%); the reasons for stenosis were due to the

small colostomy opening and the ischemia of the margins of the stoma.

CONCLUSION

Colostomy in neonates is associated with significant morbidity in developing countries. To minimize the morbidity and mortality risk, the expert paediatric surgeons should perform or assist in colostomy creation operations and should pay close attention to proper choice of the site of colostomy with early management of complications and early closure of the colostomy.

Financial support and sponsorship: Nil.

Conflict of interest: Nil.

REFERENCES:

1. **Osifo O, Osaigbovo E, Obeta E (2008):** Colostomy in children: Indications and common problems in Benin City, Nigeria. *Pakistan J Med Sci.*, 24: 199–203.
2. **Andivot T, Bail J, Chio F *et al.* (1996):** Complications of colostomies. Follow-up study of 500 colostomized patients. *Ann Chir.*, 50: 252–257.
3. **Engida A, Ayelign T, Mahteme B *et al.* (2016):** Types and indications of colostomy and determinants of outcomes of patients after surgery. *Ethiop J Health Sci.*, 26: 117–120.
4. **Chandramouli B, Srinivasan K, Jagdish S *et al.* (2004):** Morbidity and mortality of colostomy and its closure in children. *J Pediatr Surg.*, 39: 596–599.
5. **Levitt M, Kant A, Peña A (2010):** The morbidity of constipation in patients with anorectal malformations. *J Pediatr Surg.*, 45: 1228–1233.
6. **Millar A, Lakhoo K, Rode H *et al.* (1993):** Bowel stomas in infants and children. A 5-year audit of 203 patients. *S Afr J Surg.*, 31: 110–113.
7. **Holschneider A, Puri P (2008):** Hirschsprung's disease and allied disorders. 3rd ed. Berlin, Germany: Springer-Verlag. Pp. 107-113. https://link.springer.com/chapter/10.1007/978-3-540-33935-9_8
8. **Zani A, Lauriti G, Li Q *et al.* (2017):** The timing of stoma closure in infants with necrotizing enterocolitis: A systematic review and meta-analysis. *Eur J Pediatr Surg.*, 27: 7–11.
9. **Bethell G, Kenny S, Corbett H (2017):** Enterostomy-related complications and growth following reversal in infants. *Arch Dis Child Fetal Neonatal Ed.*, 102: 230–234.
10. **Yang H, Han J, Youn J *et al.* (2018):** The optimal timing of enterostomy closure in extremely low birth weight patients for acute abdomen. *Sci Rep.*, 8: 15681.
11. **Bonasso P, Dassinger M, Mehl S *et al.* (2020):** Timing of enterostomy closure for neonatal isolated intestinal perforation. *J Pediatr Surg.*, 55: 1535–1541.