

Role of Corticosteroids versus Hyaluronic Acid in Healing of Sciatic Nerve Injury in Male Albino Rats

Alaa Nabel El Sadek¹, Mohamed Ali Nasr¹, Osama El Sayed Ibrahim Abdo*¹, Mostafa Mohamed El Aidy²

Departments of ¹Plastic and Microscopic Surgery and ²General Surgery, Faculty of Medicine, Zagazig, Egypt

*Correspondence author: Osama El Sayed Ibrahim Abdo, Mobile: (+20)01007246633, E-mail: drosamarashed@gmail.com

ABSTRACT

Background: Peripheral nerve lesions are common and severe injuries that impact about 2.8% of traumatic patients annually, and result in lifetime disability if untreated. **Objective:** This study aimed to investigate the effect of corticosteroids vs hyaluronic acid in peripheral nerve healing in rats.

Patients and methods: This was experimental and histopathological study that had included (18) Sprague-Dawley rats with an average weight of 300–350 gm. All rats were divided into three groups (n=6 per group). Group 1; Corticosteroids was injected under epineurium after primary repair. Group 2; Hyaluronic acid group: the site of anastomosis was coated by hyaluronic acid after primary repair. Group 3; Primary repair only was done.

Results: 100% of cases in group 1 and group 2 showed satisfactory wound healing and 83.3% in group3 showed satisfactory wound healing with no significant difference between them. **Conclusion:** There was an increase in the number of regenerated nerve fibers in the corticosteroids and hyaluronic acid especially on the distal end in comparison to the control group.

Keywords: Corticosteroids, Hyaluronic acid, Peripheral nerve, Rats.

INTRODUCTION

Peripheral nerve lesions are common and severe injuries that impact about 2.8% of traumatic patients annually, and result in lifetime disability if untreated⁽¹⁾. Nowadays, various methods are used to guide regenerating nerve fibers into the correct distal endoneurial tubes during surgical repair. The most used strategies developed for nerve repair include end-to-end anastomosis of nerve stumps or bridging by autografts⁽²⁾. However, a major problem for nerve repair is the formation of fibroblastic scars at the site of anastomosis⁽³⁾.

Even with well repaired nerve, half of the regenerating axons may grow into scar tissue, which may lead to local neuroma and impedes axonal regeneration to the target. Consequently, regenerating nerve function is generally far from satisfactory thus, production of fibroblastic scars during nerve anastomosis impedes the regeneration of repaired nerves⁽⁴⁾. Scar tissue prevents nerve regeneration primarily by increasing nerve adhesion, which provides a direct physical block to the nerve, and by inhibiting angiogenesis⁽⁵⁾. The scar grows into the site of the lesion, and hinders extension of the regenerating nerve fibers⁽⁶⁾.

The prevention of scar hyperplasia has become a hot topic in neural regeneration research. However, outcomes have not been satisfactory in both basic and clinical studies⁽⁷⁾. There have been many strategies for reducing the impact of scar on nerve regeneration. The first approach has been to separate the nerve ends from the surrounding tissue to prevent tissue adhesions by nerve conduit and The second approach has been the application of topical pharmacological agents at the site of anastomosis like corticosteroids or hyaluronic acid⁽⁸⁾.

The aim of the current study was to investigate the effect of corticosteroids vs hyaluronic acid in peripheral nerve healing in rats.

MATERIALS AND METHODS

This is an experimental study on 21 rats, it was done at Zagazig University Hospital at October, 2018. There was animal loss of 3 rats died in the postoperative period. On final assessment, 18 rats were available.

Ethical approval:

We confirm that a high standard of ethics was applied in carrying out all aspects of the current investigation. All experimental procedures and protocols for animals approved to the Institutional Animal Care and Use Committee Zagazig University ZU-IACUC.

In our study we used (18) Sprague-Dawley rats with an average weight of 300–350 gm. Sciatic nerve of 18 rats were cut on left sides and repaired by nylon 10/0 under microscope and divided into three group 6 rats in every group. Group (1); Corticosteroids group: Corticosteroids was injected under epineurium after primary repair. Group (2); Hyaluronic acid group: The site of anastomosis was coated by hyaluronic acid after primary repair. Group (3); Control group: Primary repair only was done.

Surgical Procedure:

The rats were anaesthetized by intraperitoneal and/or intramuscular injection of 0.005 mg/gm ketamine. Hair was shaved from left hind limb and the mid-back. The rats were placed in a prone position on a rodent operating board. A 1–2 cm skin incision began 0.5 cm



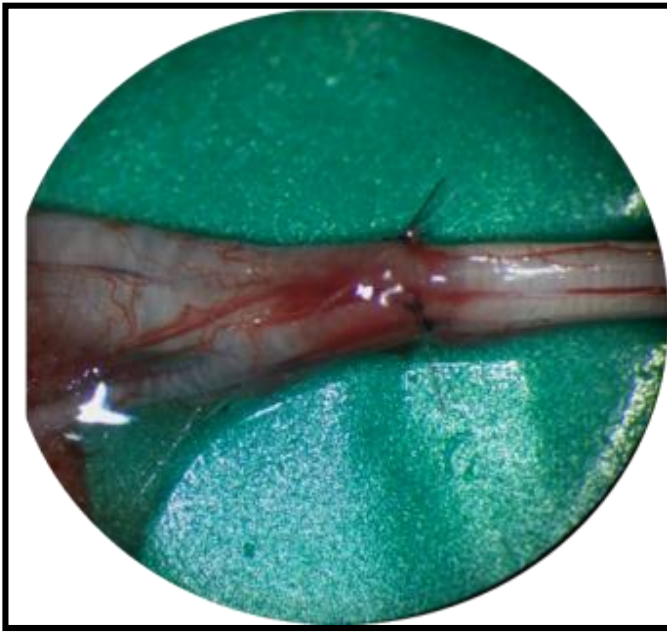
This article is an open access article distributed under the terms and conditions of the Creative Commons Attribution (CC BY-SA) license (<http://creativecommons.org/licenses/by/4.0/>)

lateral to the spine in the line between the flank and the hind limb and continued laterally above the crista iliaca after good sterilization of the area with povidone iodine 10%. The incision was undermined by blunt dissection until the fascial line was identified between the biceps and gluteal muscle groups.

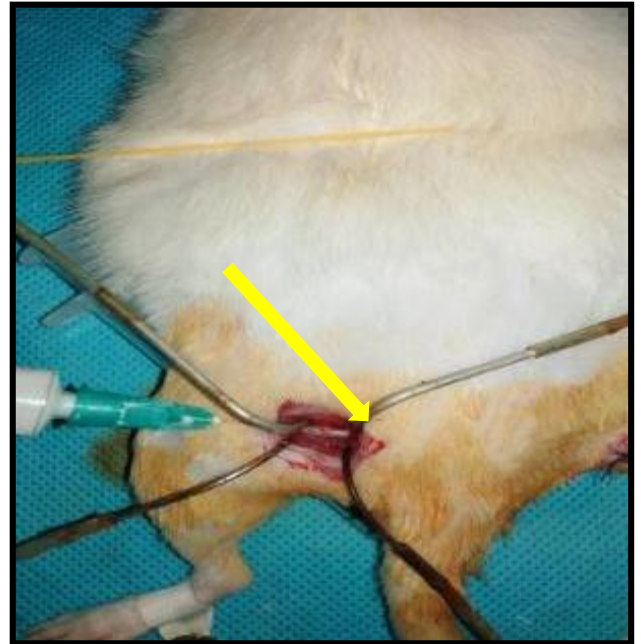
Gentle blunt spreading in this fascial plane exposed the sciatic nerve. Careful spreading without tension increased exposure of the nerve without hemorrhage from the gluteal or popliteal vessels. With

gentle handling of the nerve the background material was put under the nerve then we did nerve transection proximal to the splitting of the nerve. We did immediate primary epineurial repair by nylon 10/ 0.

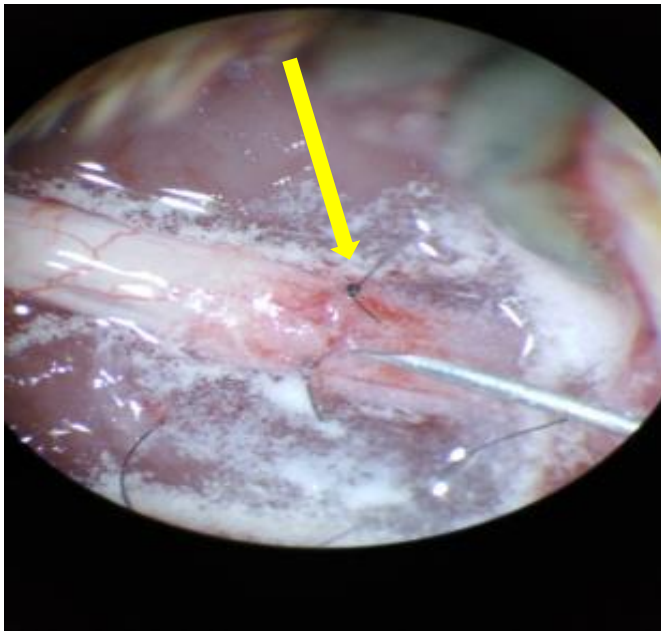In Group 1: We infiltrated the epineurium at the site of repair and proximal and distal to it with 5 mg methylprednisolone acetate by 28 G syringe (Corticosteroids group) (Fig. 1)



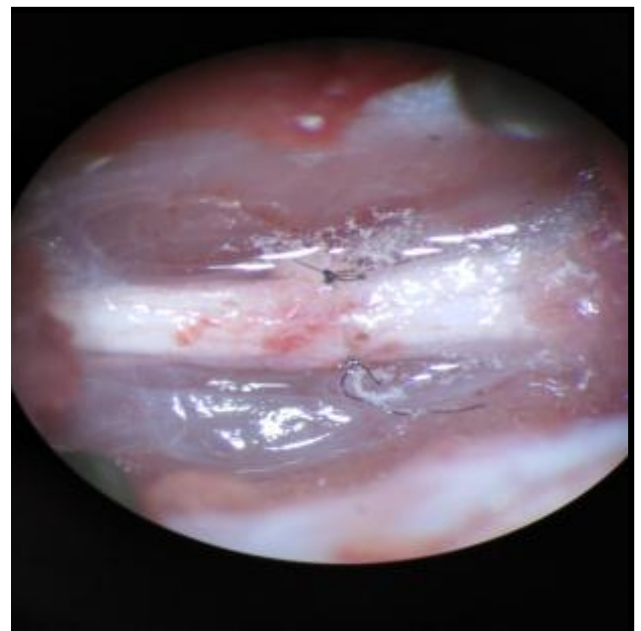
A



B



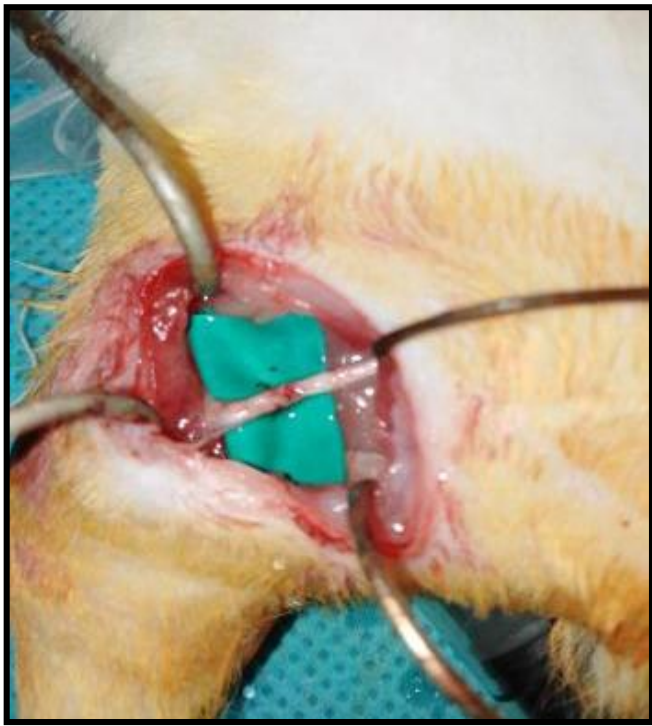
C



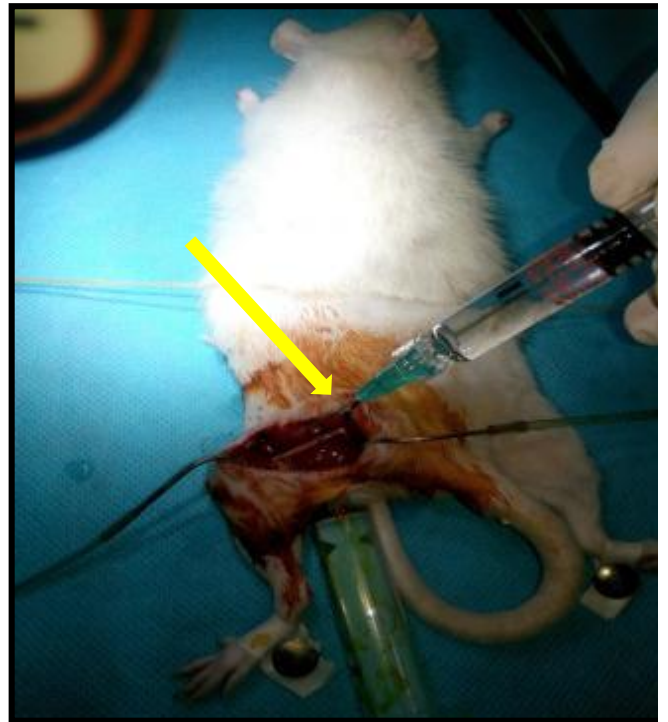D

Fig. (1): Sciatic nerve after good repair (a). During infiltration of methylprednisolone acetate (yellow arrow) (b, c). Focusing on another nerve after good infiltration with Methylprednisolone acetate (d).

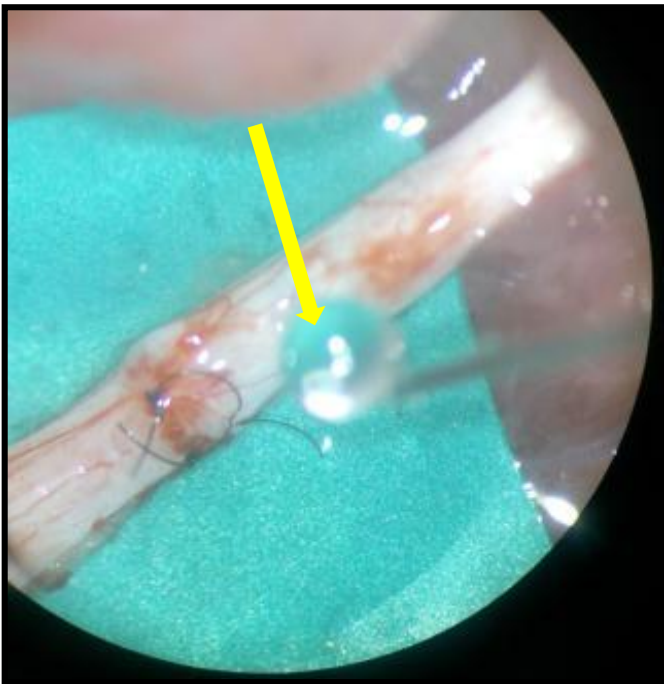In Group 2: The site of anastomosis was coated with 0.2 ml (about 2-3 drops) of hyaluronic acid (Hyaluronic acid group) (Fig. 2).



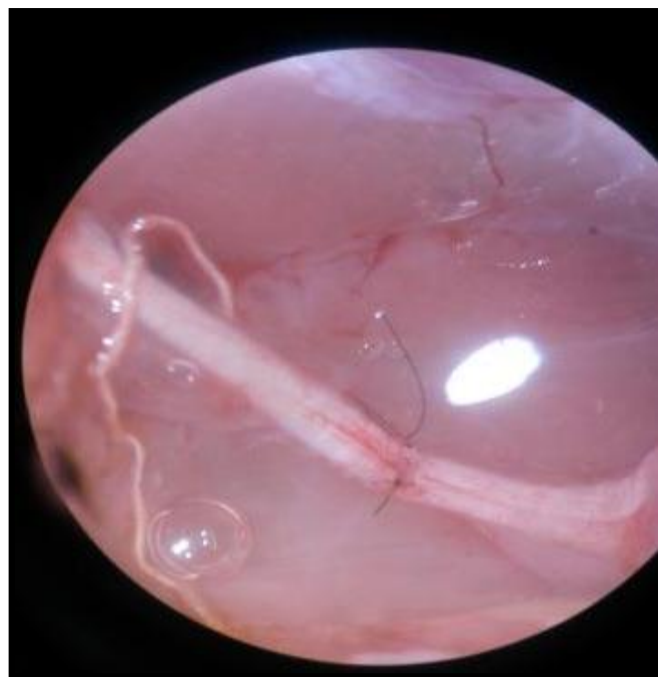A



B



C



D

Fig. (2): Sciatic nerve after good repair (a). During coating with hyaluronic acid (yellow arrow) (b, c). Focusing on another nerve after good infiltration with hyaluronic acid (d).

In Group 3: We did nothing except the repair (Control group) (Fig. 3).

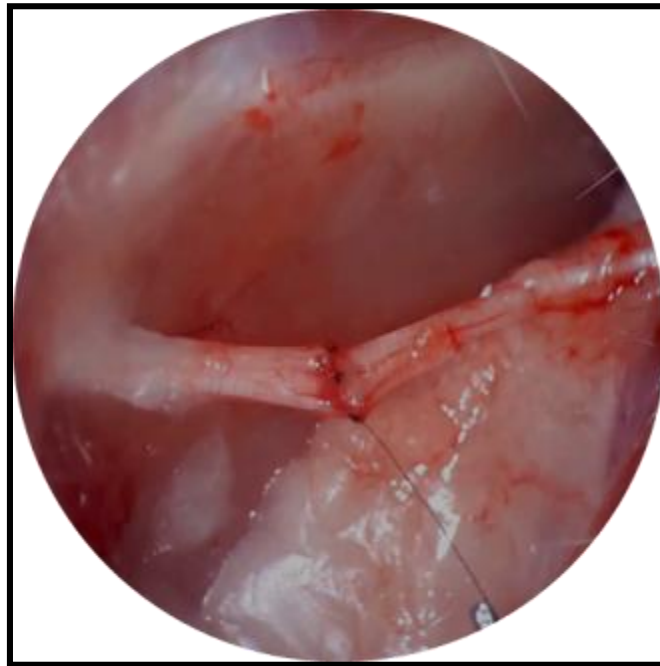


Fig. (3): Left side sciatic nerve after good repair

The wound was closed in layers Vicryl 4/0 for the muscle and prolene 4/0 for the skin in all rats and the skin was painted with povidone iodine 10 %. A surgical microscope and dissecting lenses were used to facilitate and properly perform dissection and re-anastomosis of the nerves in all rats.

Clinical follow up:

After recovery, each rat was kept in a separate cage and checked on, under the supervision, every day for the first four weeks and then every week until the end of the follow-up period (8 weeks).

Rats were checked for feeding, cleaning, wound healing and daily dressing and administration of ceftriaxone 0.2 mg/gm antibiotic for 7 days once daily IM and to detect any unlikely postoperative complications that might arise. Three rats died. Two rats died in the first week and one in the second week and the feet of the hind limbs were examined for any abnormal observations, such as

ulceration and paralysis. After complete skin healing, rats were left to live normally in groups until the end of the follow-up period.

Statistical analysis

Data were collected throughout laboratory investigations and outcome measures were coded, entered using Microsoft Excel software. Data were then imported into Statistical Package for the Social Sciences (SPSS version 20.0) software for analysis. According to the type of data; qualitative were represented as number and percentage while quantitative data were represented by mean ± SD. Quantitative data were compared by one-way ANOVA test. P value < 0.05 was considered significant.

RESULTS

Table 1 shows that there was significant difference between the studied groups as regard average number of nerve fibers counted by the two observers in proximal segment.

Table (1): Comparison between the three studied groups as regard average number of nerve fibers counted by the two observers in proximal segment

	G1 n=6	G2 n=6	G3 n=6	P value
Average number of nerve fibers				
Mean ±SD	146.50 ± 10.13	153.17± 9.57	131.5± 6.86	<0.003
Range	(135–156)	(144–168)	(120–140)	

Table 2 shows that there is significant difference between the studied groups as regard average number of nerve fibers counted by the two observers in distal segment.

Table (2): Comparison between the three studied groups as regard average number of nerve fibers counted by the two observers in distal segment.

	G1 n=6	G2 n=6	G3 n=6	P value
Average number of nerve fibers				
Mean ±SD	135.17± 12.49	148±7.61	116.6± 5.0	<0.001
Range	(120–151)	(140–158)	(110–120)	

Table 3 shows that there is high significant difference between the studied groups as regard the neurotization index.

Table (3): Comparison of the neurotization index (mean of distal count/ mean of proximal count X 100) in the three studied groups

	G1 n=6	G2 n=6	G3 n=6	P value
Neurotization index				
Mean ±SD	92.27± 5.58	96.6± 1.49	88.71± 4.2	<0.02
Range	(83.33–97.40)	(94.05–98.64)	(82.09–93.75)	

DISCUSSION

In this study, macroscopic evaluation demonstrated that the adhesion of nerves to adjacent tissues was significantly reduced in the experimental groups as compared with that of the control group. Histological analysis determined that the scar tissue formation of the experimental groups was significantly lower than that of the control group. Histomorphological analysis of the organization of the nerve repair sites revealed that the experiment groups was significantly better than that of the control group.

In this study we used the neurotization index to compare nerve regeneration in experimental groups and control group. It indicates the number of axons that successfully crossed the repair site from the proximal to the distal segment. This index was reported to indicate the quantity of nerve regeneration after neuroanastomosis⁽⁹⁾.

The histomorphometric results of this study showed that the corticosteroid-treated group and hyaluronic acid-treated group showed a significant increase in the number of regenerating nerve fibers compared with the control group. This supports the results recently reported by⁽¹⁰⁾.

The present results showed a statistically significant difference in the outcome of nerve regeneration between the corticosteroid-treated groups and hyaluronic acid-treated groups and control groups.

CONCLUSION

The result was satisfactory and showed that there is an increase in the number of regenerated nerve fibers in the corticosteroids and hyaluronic acid especially on the distal end in comparison to the control group. So, we recommend more parameters as thickness of regenerated

nerve fibers, electro-physiological evaluation, muscle wet-weight and immunohistological evaluation.

REFERENCES

1. **Belkas J, Shoichet M, Midha R (2004):** Peripheral nerve regeneration through guidance tubes. *Neuro Res.*, 26:151-160.
2. **Isaacs J, Cheatham S, Gagnon E et al. (2008):** Reverse end-to-end neurotization in regenerating nerve. *J Reconstr Microsurg.*, 24: 489-496.
3. **Ngeow W (2010):** Scar less: a review of methods of scar reduction at site of peripheral nerve repair. *Oral Surg Oral Med Oral Pathol Oral Radiol Radiol Endod.*, 109:357-366.
4. **Sedy J (2010):** Traumatic neuroma and scar tissue. *Int J Oral Maxillofac Surg.*, 39:310-311.
5. **Abrams M, Widenfalk J (2004):** Emerging strategies to promote improved functional outcome after peripheral nerve injury. *Restor Neurol Neurosci.*, 23:367-382.
6. **Park J, Lee J, Han C et al. (2011):** Effect of hyaluronic acid-carboxymethylcellulose solution on perineural scar formation after tibias nerve repair in rat. *Clin Orthop Surg.*, 3:315-324.
7. **Silver J, Miller J (2004):** Regeneration beyond the glial scar. *Nat Rev Neurosci.*, 5:146-156.
8. **Jeong B, Gutowska A (2002):** Lessons from nature: stimuli-responsive polymers and their biomedical applications. *Trends Biotechnol.*, 20:305-311.
9. **Martins R, Siqueira M, Da Silva C et al. (2005):** Overall assessment of regeneration in peripheral nerve lesion repair using fibrin glue, suture, or a combination of the 2 techniques in a rat model. Which is the ideal choice?. *Surgical Neurology*, 64: 10-16.
10. **Dam-Hieu P, Lacroix C, Said G et al. (2005):** Reduction of postoperative perineural adhesions by Hyalogluid gel: an experimental study in the rat sciatic nerve. *Operative Neurosurgery*, 56: 425-430.