

## Trapezium Fracture: Case Report

Mohammed Aljuhani\*, Eyad Alakkas, Mohammed Alamri, Ahmed Alnajrani

Department of Orthopedic Surgery, East Jeddah Hospital, Jeddah, Saudi Arabia

\*Corresponding author: Mohammed Abdulwahab Aljuhani, Mobile: +966548557799, E-Mail: mohalh@hotmai.com

### ABSTRACT

**Background:** Trapezium fractures are extremely uncommon, accounting for only 4% of all hand injuries. Trapezium fractures are a very infrequent kind of carpal bone injury. They can happen alone or in conjunction with another carpal bone lesion.

**Cases report:** A 19-years old female right hand dominant with no medical conditions presented to the Emergency Department at East Jeddah Hospital as a case of motor vehicle accident (MVA). She was sitting in the back chair where she put her both hands in hyperextension over the seat in front to protect her during the injury. She came complaining of left hand pain and swelling.

**Conclusion:** We report this case of trapezium fracture, which is a rare injury with our management done by using open reduction and Herbert's screws fixation. The patient got successful early mobilization. We achieved good clinical and functional outcomes as well as satisfaction.

**Keywords:** Trapezium fracture, Hand pain, Hand swelling.

### INTRODUCTION

Trapezium fractures are very rare and can lead to a significant deficit of hand function if missed. Isolated fractures of the trapezium account for 3–5% of all carpal fractures<sup>(1, 2)</sup>. However, they should not be missed because inadequate treatment of trapezium fractures can lead to permanent impairment based on the substantial forces experienced at the trapeziometacarpal (TMC) joint in pinch and grip<sup>(3,4)</sup>.

The trapezium forms a double-saddle articulation with the base of the thumb metacarpal allowing motion in two planes—both flexion/extension and abduction/adduction. The volar “beak” ligament from the metacarpal to the trapezium is a key structure in maintaining joint stability and resisting dorsal radial subluxation during a key pinch. The trapezium body articulates with the carpal bones. The trapezial ridge is a volar structure that serves as a radial attachment for the transverse carpal ligament<sup>(5)</sup>.

Trapezium fractures include body and ridge fractures. Fractures of the trapezial ridge can result from a direct blow or from an avulsion injury. Pain in the thenar area following a wrist injury should alert surgeons to the possibility of a scaphoid fracture, but trapezial fractures can occur, albeit more rarely<sup>(6)</sup>.

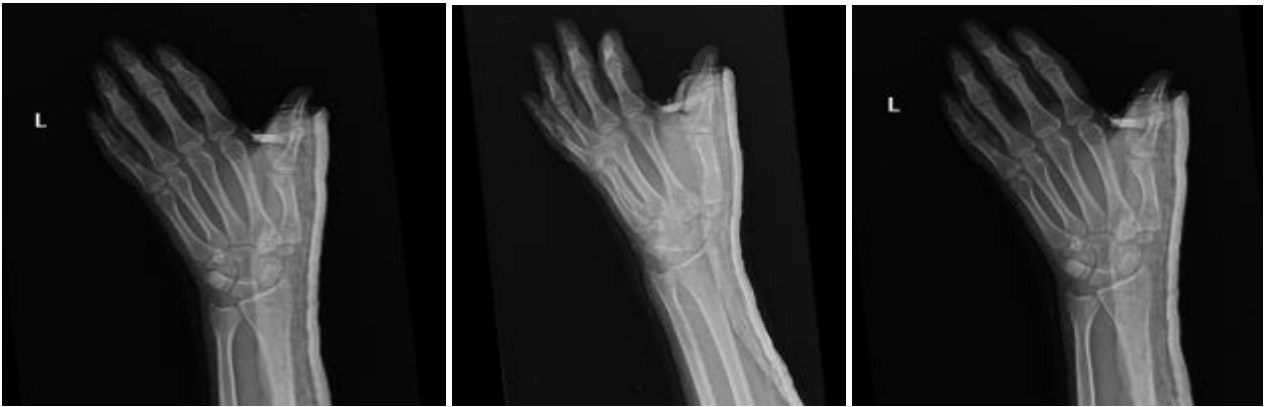### CASE REPORT

A 19-years old female right-hand dominant with no medical conditions.

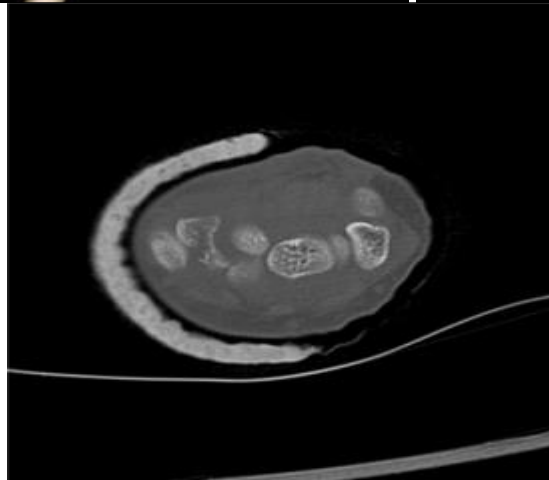
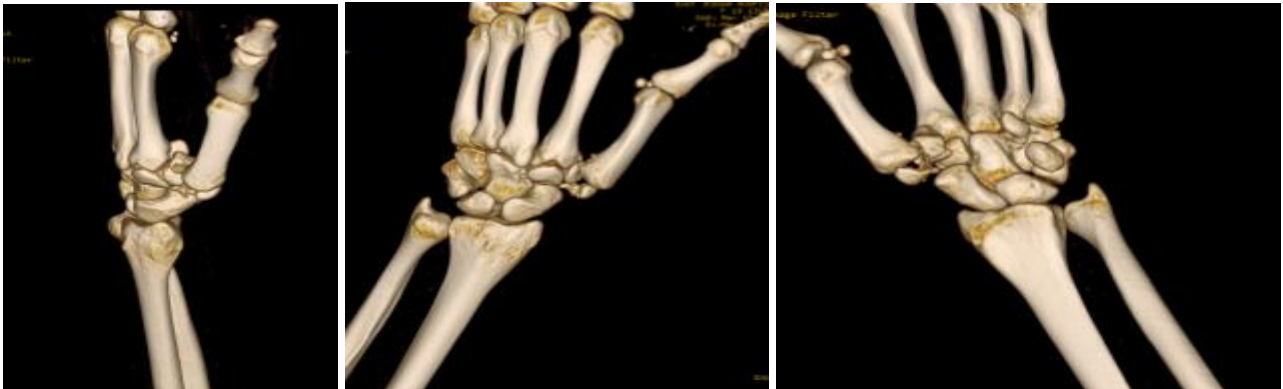- She presented to the Emergency Department at East Jeddah Hospital as a case of motor vehicle accident (MVA). She was sitting in the back chair where she put her both hands in hyperextension over the seat in front to protect her during the injury. She came complaining from left-hand pain and swelling.
- After a primary and secondary survey and clearance from other specialties, our examination was localized to the left hand. There was swelling and no signs of open fracture with tenderness at the base of the left thumb.
- X-ray revealed trapezium fracture in the body vertical intra-articular type so we proceeded for CT scan for preoperative planning.
- Dorsoradial skin incision on the base of thumb about 3 cm has been used for reduction and fixation that was completed by 2 Herbert' screws. Then, post operative slab was made.
- Patient was discharged and follow up at the clinic after 2 weeks where sutures and slab were removed with the advice of protected weight lifting and early range of motion to avoid stiffness. After that regular follow up to assess union and alignment that showed good healing signs up to full healing in 2 months with a good range of motion.
- The last visit after 1.5 years, the patient was satisfied doing her daily activity with a full range of motion of the thumb and index with no complaint of pain except with lifting heavy objects sometimes.



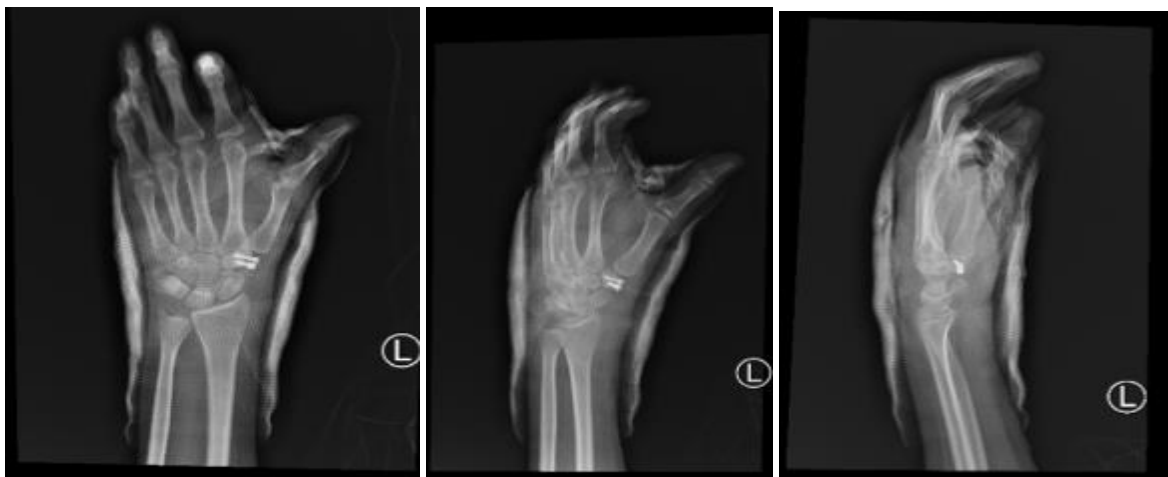This article is an open access article distributed under the terms and conditions of the Creative Commons Attribution (CC BY-SA) license (<http://creativecommons.org/licenses/by/4.0/>)



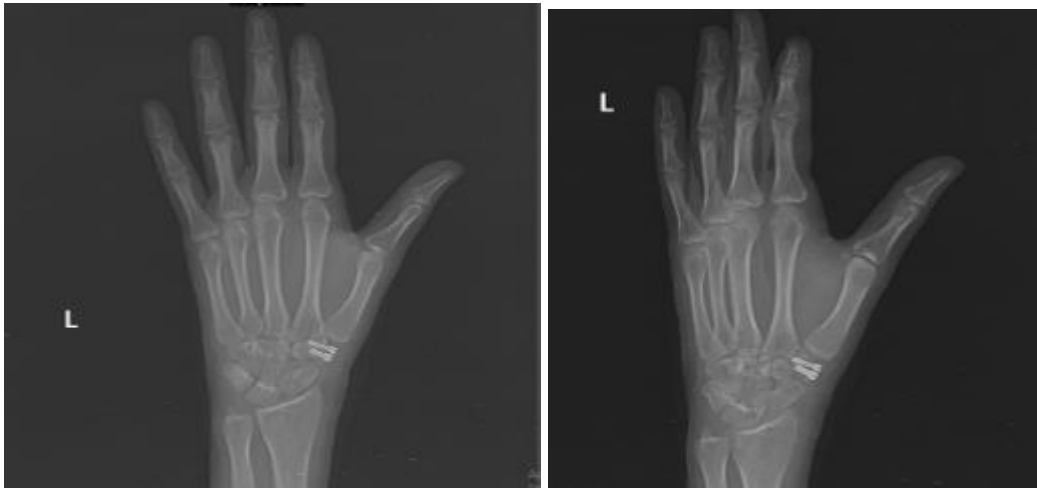**Figure (1):** Preoperative X-ray.



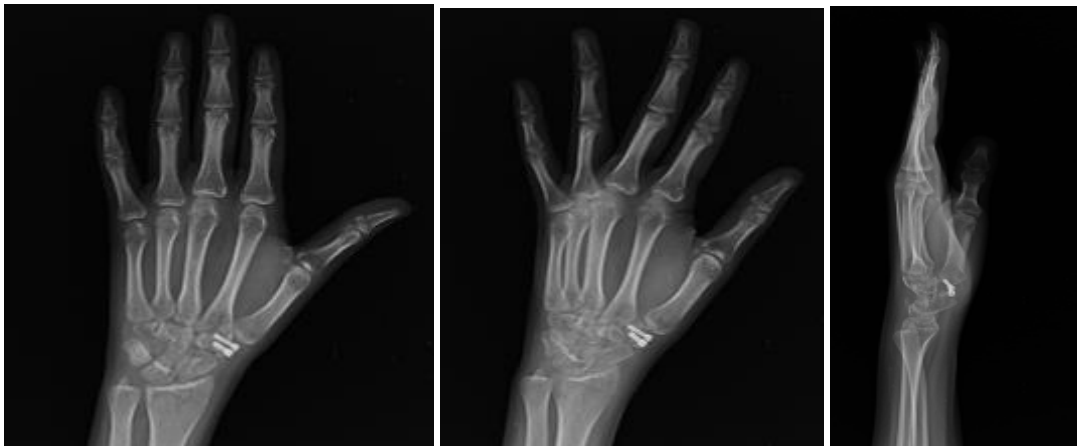
**Figure (2):** Preoperative CT.



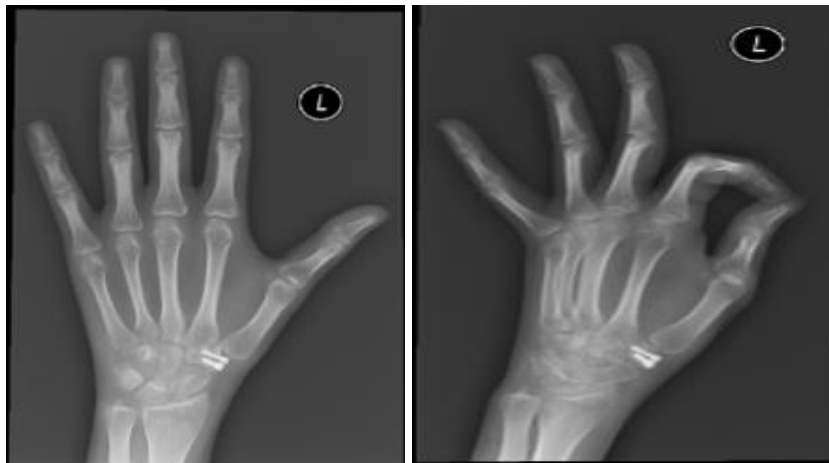**Figure (3):** Day 1 postoperative X-ray.



**Figure (4):** 2 weeks postoperative X-ray.



**Figure (5):** 1 month postoperative X-ray.



**Figure (6):** 3 months postoperative X-ray.

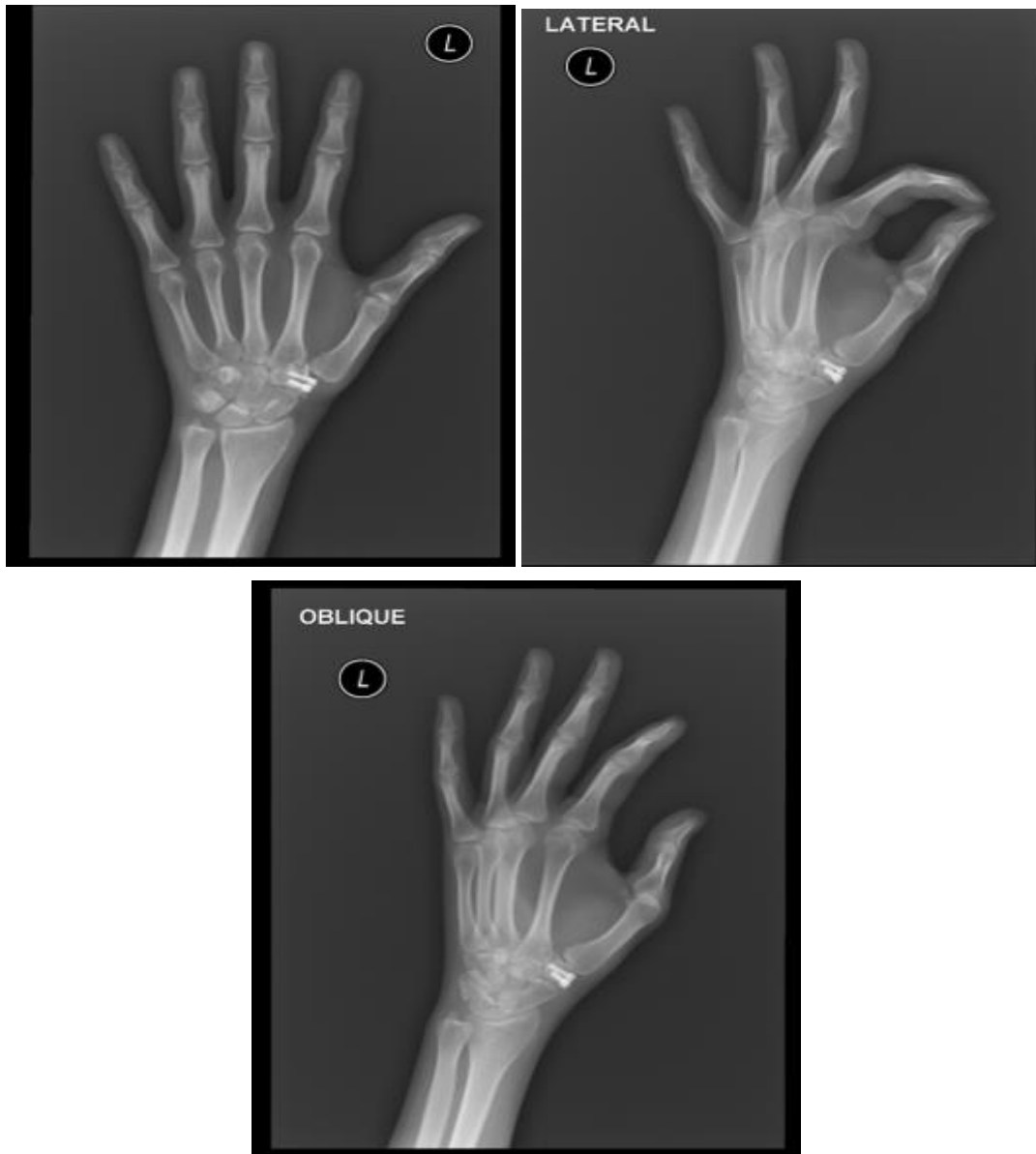


Figure (6): 1.5 year postoperative X-ray.

#### Ethical approval:

An approval of the study was obtained from East Jeddah Hospital, (Jeddah, Saudi Arabia) Academic and Ethical committee. The patient signed informed written consent for the acceptance of the operation and for publication of this case report. This work has been carried out in accordance with the Code of Ethics of the World Medical Association (Declaration of Helsinki) for studies involving humans.

#### DISCUSSION

Trapezium fractures often result from high energy trauma and occur in association with other injuries; most commonly fracture of the first (thumb) metacarpal followed by other carpal bone injuries and the distal radius<sup>(7)</sup>. In a trans-trapezium fracture-dislocation the body of the trapezium is usually split vertically<sup>(8)</sup>. Several methods have been described in the literature for the treatment of this rare fracture,

from conservative treatment in plaster to open reduction and internal fixation<sup>(9)</sup>.

Treatment of trapezium fractures includes several management options. Nonoperative treatment consists of immobilization for 4 to 6 weeks<sup>(10)</sup>. The results of the conservative treatment with a plaster cast for most non-displaced trapezium fractures diverge from successful<sup>(11)</sup> to dismal<sup>(12)</sup>. Although, a universal protocol for the treatment of this injury is lacking, it is commonly accepted that intra-articular fractures require accurate reduction and restoration of the articular surface. This is supported by two series which emphasized the need for accurate reduction of the articular surface with displacement > 2 mm<sup>(4, 13)</sup>. **Inston et al.**<sup>(14)</sup> described the use of a Herbert' screw, which gave dynamic compression of the fragments reporting very good success.

In this case report, the patient sustained a trans-trapezium fracture that was successfully treated. Intraoperative dorsoradial skin incision on the base of the thumb about 3 cm have been done for reduction

and fixation by 2 Herbert' screws and post-operative slab was made, which resulted in an excellent functional outcome at 1.5 year follow-up.

## CONCLUSION

We report this case of trapezium fracture, which is a rare injury with our management done by using open reduction and Herbert's screws fixation. The patient got successful early mobilization. We achieved good clinical and functional outcomes as well as satisfaction.

**Conflict of interest:** The authors declare no conflict of interest.

**Funding sources:** The authors have no funding to report.

## REFERENCES

1. **Borgeskov S, Christiansen B, Kjaer A et al. (1966):** Fractures of the carpal bones. *Acta Orthopaedica Scandinavica*, 37: 276–287.
2. **Bosmans B, Verhofstad M, Gosens T (2008):** Traumatic thumb carpometacarpal joint dislocations. *Journal of Hand Surgery*, 33: 438–441.
3. **Cooney W, Chao E (1977):** Biomechanical analysis of static forces in the thumb during hand function. *J Bone Joint Surg.*, 59: 27-36.
4. **Martins I, Vasques A, Pereira F et al. (2017):** Open Reduction and Fixation of Trapezium Fracture. *MOJ Orthop Rheumatol* 9 (3): 00356. DOI: 10.15406/mojor.2017.09.00356
5. **Suthersan M, Chan S (2011):** Isolated comminuted fracture of the trapezium: a case report and review of the literature. *Internet J Orthop Surg.*, 18 (2): 1-4.
6. **van Onselen E, Karim R, Hage J et al. (2003):** Prevalence and distribution of hand fractures. *J Hand Surg Br.*, 28: 491-99.
7. **McGuigan F, Culp R (2002):** Surgical treatment of intra-articular fractures of the trapezium. *J Hand Surg AM.*, 27 (4): 697-703.
8. **Kukreti S, Harrington P (2004):** Carpometacarpal joint dislocation of the thumb associated with fracture of the trapezium: a case report. *Eur J Orthop Surg Traumatol.*, 14 (1): 38-39.
9. **Ramoutar D, Katevu C, Titchener A et al. (2009):** Trapezium fracture - a common technique to fix a rare injury: a case report. *Cases Journal*, 2: 8304.
10. **Urch E, Lee S (2015):** Carpal fractures other than scaphoid. *Clin Sports Med.*, 34 (1): 51-58.
11. **Van Schil P, De Smet C (1986):** Simultaneous fracture of carpal scaphoid and trapezium. *Br J Hand Surg.*, 11 (1): 112-114.
12. **Jones W, Ghorbal M (1985):** Fractures of the trapezium. A report on three cases. *J Hand Surg.*, 10B: 227-230.
13. **Balci A, Basara I, Çekdemir E et al. (2015):** Wrist fractures: sensitivity of radiography, prevalence, and patterns in MCDT. *Emerg Radiol.*, 22: 251-56.
14. **Inston N, Pimpalnekhar A, Arafa M (1997):** Isolated fracture of the trapezium: an easily missed injury. *Injury*, 28 (7): 485-488.