



Ain Shams University

The Egyptian Journal of Medical Human Genetics

www.ejmhg.eg.net
www.sciencedirect.com



CASE REPORT

Familial Peters Plus syndrome with absent anal canal, sacral agenesis and sensorineural hearing loss: Expanding the clinical spectrum

Rabah M. Shawky *, Solaf M. Elsayed, Heba S. Abd-Elkhalek, Shimaa Gad

Genetics Unit, Children's Hospital, Ain Shams University, Cairo, Egypt

Received 23 April 2013; accepted 21 May 2013

Available online 23 July 2013

KEYWORDS

Peters anomaly;
Corneal opacity;
Absent anal canal;
Deafness

Abstract Peters anomaly is a rare form of anterior segment dysgenesis in which abnormal cleavage of the anterior chamber occurs involving the central or entire cornea. It may be associated with other ocular or systemic abnormalities. Peters Plus syndrome, also known as Krause–Kivlin syndrome, characterized by additional anomalies including short stature with developmental delay, facial dysmorphism, genitourinary abnormalities; syndactyly; brachycephaly; and cardiac, neural, and hearing abnormalities. Here we report an 8 month old boy with typical features of Peters Plus syndrome including eye anomalies, dysmorphic features, global developmental delay, growth retardation, bilateral talipes equinovarus, complex renal anomalies, absent anal canal, sacral agenesis and sensorineural hearing loss. To our knowledge, the last three features were not reported before.

© 2013 Production and hosting by Elsevier B.V. on behalf of Ain Shams University.

1. Introduction

Peters Plus syndrome (PPS) is a very rare autosomal recessive condition characterized by a variety of anterior eye chamber anomalies, of which the Peters anomaly occurs most frequently. Other major symptoms include a disproportionate short stature, developmental delay, characteristic craniofacial features, and cleft lip and/or palate [1]. Alternate terms for Peters plus

syndrome have included Krause–Kivlin syndrome and Krause–van Schooneveld–Kivlin syndrome being the first to report these cases [2,3]. Additional features include short-limb dwarfism, a thin upper lip, hypoplastic columella, and a round face [4].

Here we report a patient with Peters Plus syndrome with absent anal canal, complex renal anomalies and sensorineural hearing loss which to our knowledge, has not been reported before.

2. Case report

Our patient is an 8 month old male infant, fourth in order of birth of one and half cousin Egyptian parents, the age of mother was 39 years and the father was 36 years. The patient was born by normal vaginal delivery after uncomplicated pregnancy. The mother took only multivitamin supplementation in

* Corresponding author. Address: Faculty of medicine, Ain Shams University, Cairo, Egypt. Tel.: +20 2 22585577.

E-mail address: shawkyrabah@yahoo.com (R.M. Shawky).

Peer review under responsibility of Ain Shams University.



Production and hosting by Elsevier

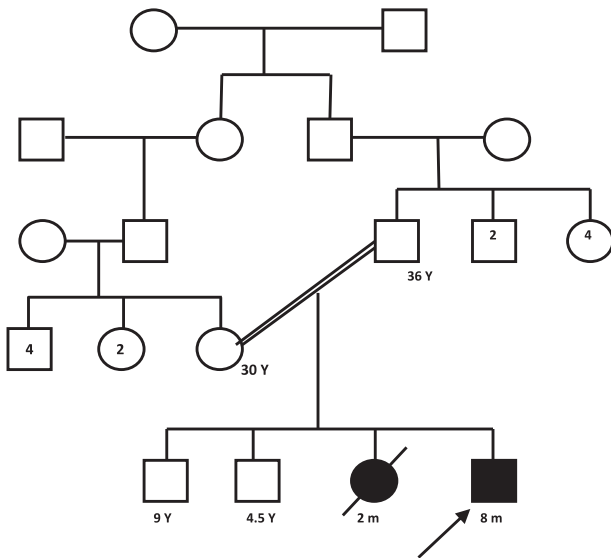


Figure 1 Family pedigree.

the first trimester. The patient was referred to the Genetics Clinic, Children's Hospital, Ain Shams University due to the presence of multiple congenital anomalies. Family history revealed a probably similarly affected female sib with imperforate anus and corneal opacity who died at the age of two months, Fig. 1.

At birth the patient was diagnosed with imperforate anus and corneal opacity. Colostomy was done at the age of 3 days. At presentation (at the age of 8 months), he had global developmental delay as he could not support his neck, could not recognize his mother or follow objects. His weight was 4.2 kg (<3rd percentile), length was 56 cm (<3rd percentile), and skull circumference was 37 cm (<3rd percentile, microcephaly), with widely open anterior fontanel. Facial features

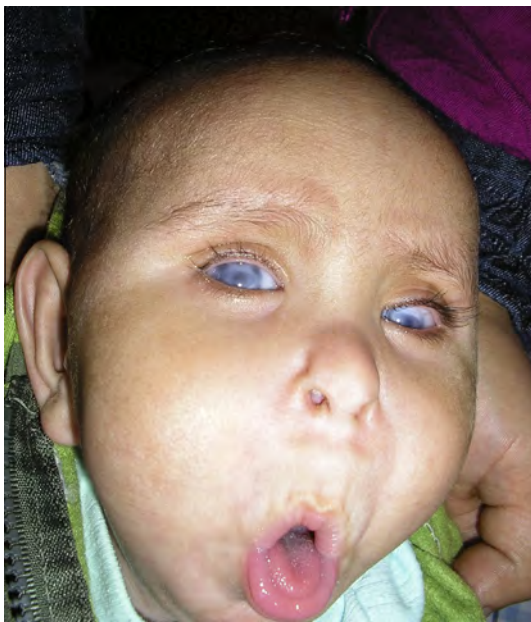

Figure 2 Anteroposterior view of patient showing Peters anomaly and dysmorphic features.

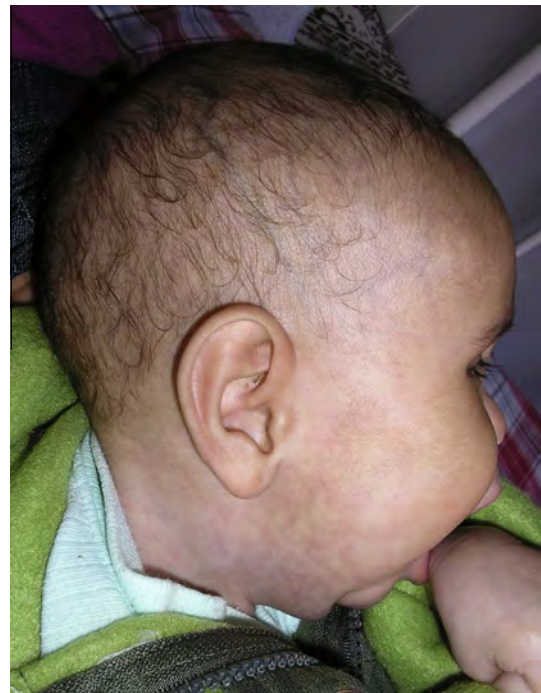

Figure 3 Lateral view of the patient showing low set ears and retro-micrognathia.

included high forehead, depressed nasal bridge with bulbous nose, low set ears, long philtrum, retro-micrognathia. Both eyes showed bilateral corneal opacity, and searching nystagmus, (Figs. 2 and 3). Lower limbs showed bilateral knee dimpling and bilateral talipes equinovarus, (Fig. 4).

Chest, heart and abdominal examination showed no abnormalities except for colostomy at the left iliac region. Neurological examination revealed global developmental delay, normal tone and reflexes. Hearing impairment was clinically evident.

Ocular ultrasonography showed that both eyes had increased corneal thickness with mild central thinning and diffuse highly echogenic corneal opacity. The descemet's endothelial complex was distorted. The anterior chamber was shallow. The iris is seen adherent to the back of the cornea at multiple points with associated angle occlusion in all

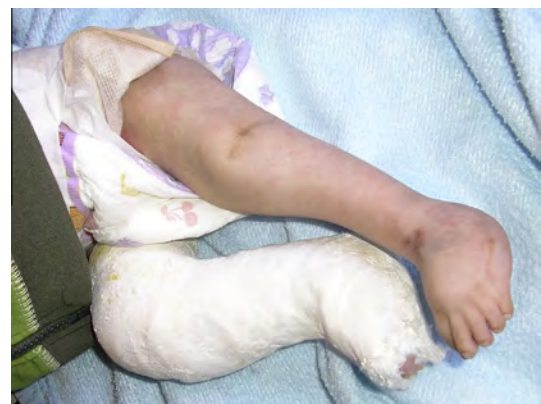

Figure 4 Patients' legs showing talipes equinovarus and knee dimples.

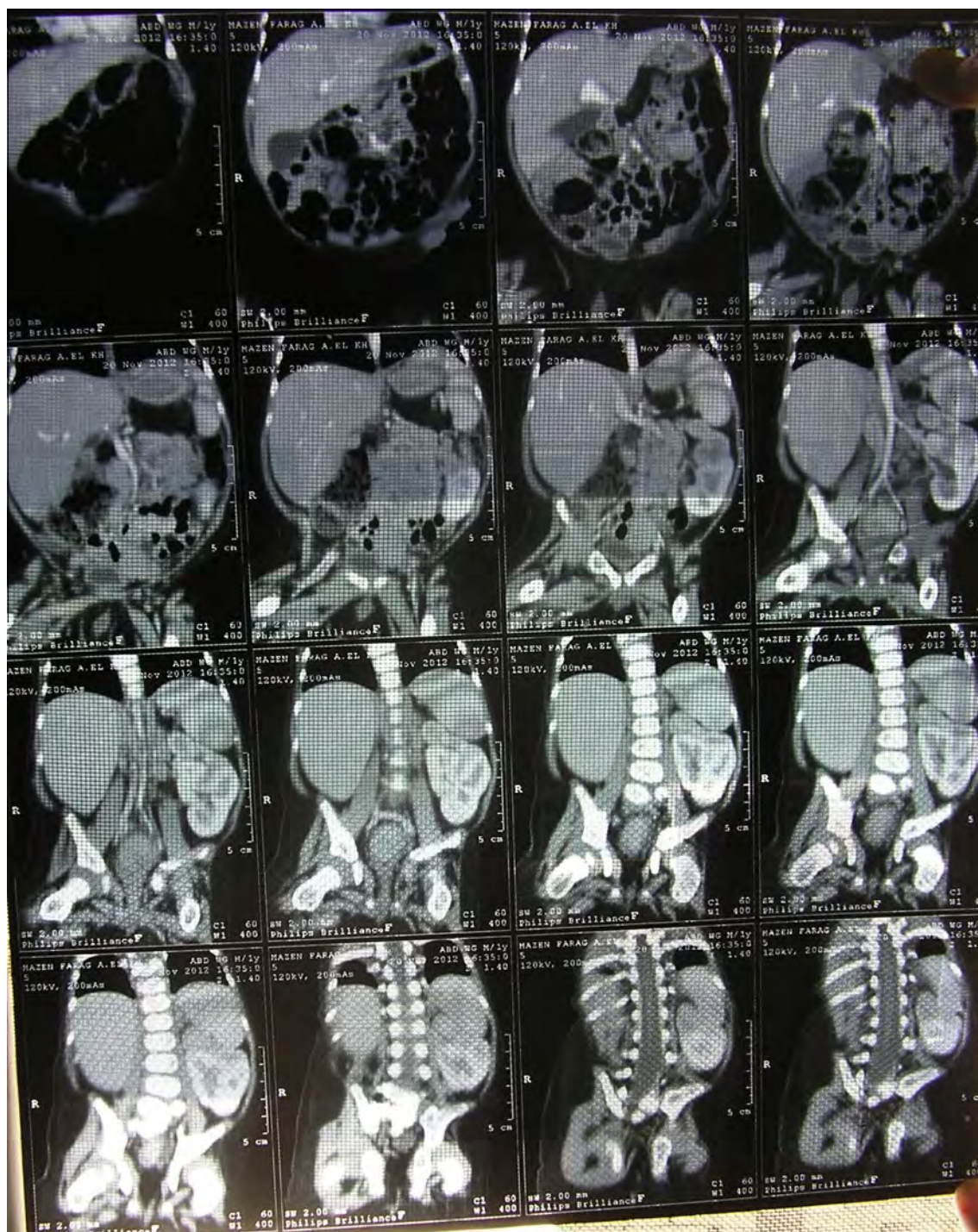


Figure 5 Multislice CT of abdomen and pelvis.

quadrants by synechia. The anterior surface of the lens was regular. Visual evoked potential showed bilateral functioning visual pathways.

Audiometry showed bilateral sensory neural hearing loss. Echocardiography, electroencephalogram and MRI brain showed no abnormality. Karyotype revealed 46, XY normal male karyotype.

Multi-slice CT of the abdomen and pelvis with both IV and oral contrast revealed that the right kidney was crossing to the

left side and fusing superiorly and partly posterior to the left kidney with the right ureter passing across the midline to the right side of the urinary bladder. The left ureter was shorter with dilated distal segment just before ureterovesical junction. The bowel loops were seen dilated with complete absence of anal canal. The distal lumbosacral segment of the spinal canal was capacious with segmentation anomalies, malalignment of L5 and S1 vertebrae together with S1 spinal bifida and tethered cord with suspected intraspinal syrinx (Fig. 5). MRI

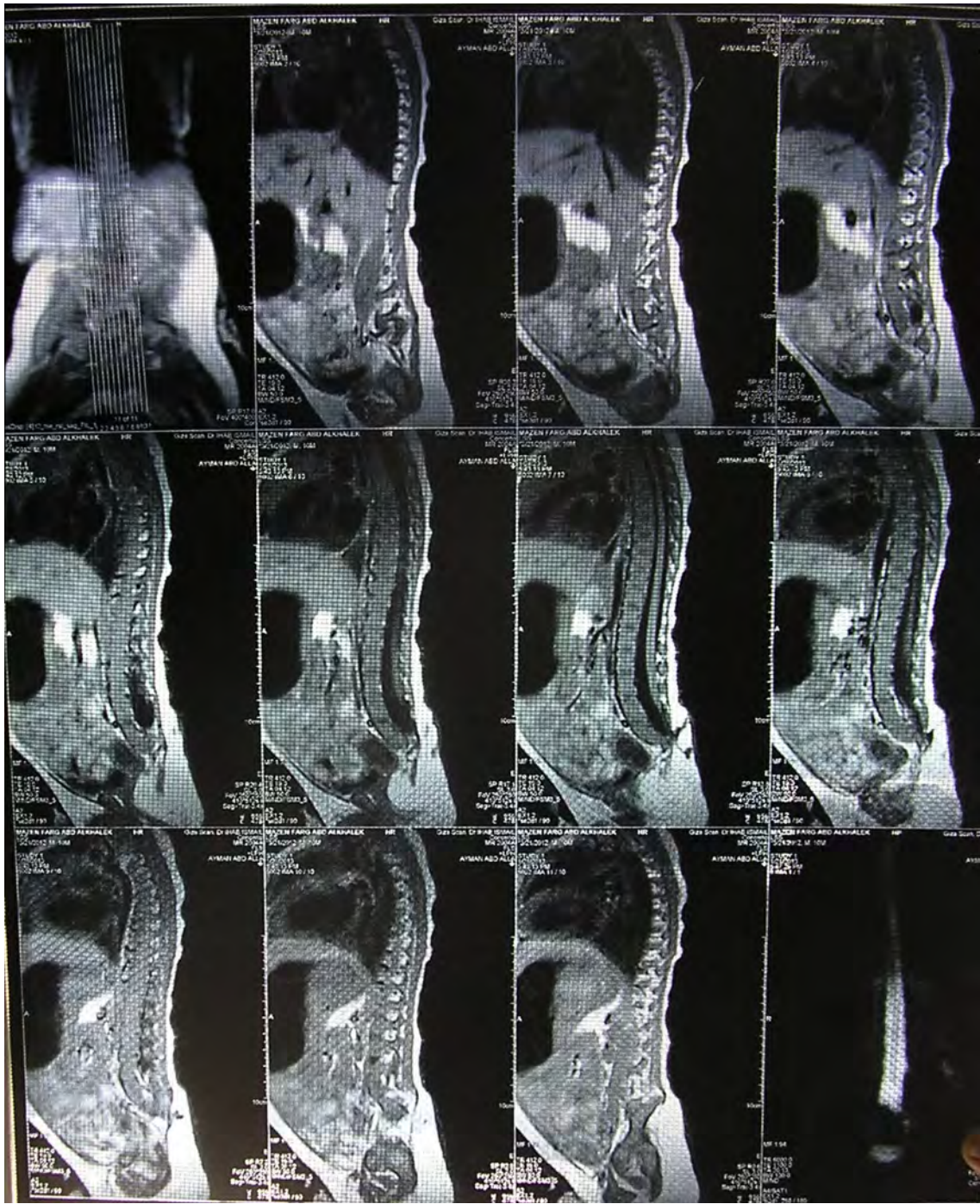


Figure 6 Multislice CT of abdomen and pelvis.

of the lumbosacral spine revealed sacral agenesis, defective posterior neural arches of the lower lumbar spines, wide spinal canal and low inserted (down to the lower sacrum) teethered cord, (Fig. 6).

3. Discussion

Our patient had typical features of Peters Plus syndrome in addition to absent anal canal, sacral agenesis, complex renal anomalies and sensorineural hearing loss. To our knowledge, these features were not reported before.

Previously reported gastrointestinal anomalies in Peters Plus syndrome included anteriorly placed anus [5], anal atresia and vesicocolonic fistula [6] and intestinal malrotation with anal atresia [7].

The second new feature found in this patient is sensorineural hearing loss. Conductive hearing loss was variably reported in patients with PPS. It is usually associated with cleft palate but not otherwise a major feature [8].

Previously, a patient with Peters anomaly, bilateral ear lobe creases and hypospadias was reported in an Egyptian family with microcornea cataract syndrome [9]. Another patient

with Peters Plus syndrome with some unusual features was also reported in Egypt. These features included thick tongue, thick everted lower lip, anteverted nares, broad thumb and big toe, lower back kyphoscoliosis, bilateral rocker bottom heels and splenomegaly [10].

Vertebral anomalies previously reported in Peters Plus syndrome included scoliosis, hemivertebrae, vertebral segmentation defects, square pelvis and flat iliac crests [11], spina bifida and myelomeningocele [12] and sacral dimple and platyblasia [13]. Sacral agenesis was not reported before. These data suggest that the spectrum of Peters plus syndrome should be expanded to include anomalies in nearly all body systems.

The key feature of this syndrome is Peters anomaly which was typically present bilaterally in our patient with no involvement of lens or glaucoma, classified as type I with expected good prognosis [14]. Other reported eye anomalies include mild mesenchymal dysgenesis and iris coloboma [15].

Growth retardation could be variably present in these patients. Although our patient had normal birth weight, his weight and length at the age of 8 months were below the third percentiles. Growth hormone deficiency was suggested as a cause of growth retardation in these children with good response to replacement therapy [16]. The presence of colostomy with expected loss of fluids and malnourishment in our patient could be another causative factor. The patient had also global developmental delay, partially because of his defective vision and hearing loss and also because this is a part of the syndrome reported in 83% of cases [1].

Genitourinary abnormalities were reported in about 10–19% of patients suffering from Peters anomaly. This included hydronephrosis, renal and ureteral duplication, renal hypoplasia and oligomeganephroma, multicystic dysplastic kidney, glomerulocystic kidneys [17] and absence of one kidney [6]. The complex renal anomaly present in our patient was not reported before.

Considering that our patient had a similar affected sib, inheritance in this family is obviously autosomal recessive as concluded by Wenniger-Prick and Hennekam, 2002 in their review of published and unpublished cases [1].

Mutations in the *B3GALTL* gene encoding beta 1,3-glucosyltransferase have been found in virtually all patients with typical Peters Plus syndrome. *B3GALTL* molecular test provides diagnosis confirmation and improves dramatically genetic counseling for the families as the clinical spectrum of this syndrome is extremely heterogenous [18,19].

The mutations responsible for Peters plus syndrome inactivate a beta1,3-glucosyltransferase whose function is to add a glucose moiety to O-linked fucose, forming a rare glucose-beta1,3-fucose disaccharide. This disaccharide modification is specific to thrombospondin type 1 repeats (TSRs), domains found in extracellular proteins that function in cell–cell and cell–matrix interactions and signaling. Some ninety human proteins contain TSRs, but thus far the disaccharide has been demonstrated on only thrombospondin 1, properdin, F-spondin, ADAMTS-13, and ADAMTSL-1. These proteins perform essential functions in embryonic development, tissue remodeling, angiogenesis, neurogenesis, and complement activation. Identification of the beta1,3-glucosyltransferase and its substrate proteins is a key step toward understanding their roles in human development, and to uncover the molecular and cellular mechanisms underlying the clinical manifestations of Peters plus syndrome [20].

Prenatal diagnosis can be done if the molecular defect in the family was identified. Prenatal ultrasound was useful in diagnosis in four fetuses by finding of hydrocephalus with additional cleft lip/palate and/or agenesis of the corpus callosum. Other features were growth retardation, hypertelorism, anomalies of the eyes, in part consistent with Peters anterior chamber anomalies, mild brachymelia, brachydactyly, and also internal anomalies. Suspected PPS was confirmed by detection of *B3GALTL* mutation [21].

References

- [1] Wenniger-Prick LJ, Hennekam RCM. The Peters' Plus syndrome: a review. *Ann Genet* 2002;45:97–103.
- [2] Krause U, Kovisto M, Rantakillio P. A case of Peters' syndrome with spontaneous corneal perforation. *J Pediatr Ophthalmol* 1969;6:145–9.
- [3] Kivlin JD, Fineman RM, Crandall AS, Olson RJ. Peters' anomaly as a consequence of genetic and nongenetic syndromes. *Arch Ophthalmol* 1986;104:61–4.
- [4] Kosaki R, Kamiishi A, Sugiyama R, Kawai M, Hasegawa T, Kosaki K. Congenital hypothyroidism in Peters Plus syndrome. *Ophthalmic Genet* 2006;27:67–9.
- [5] Reis LM, Tyler RC, Abdul-Rahman O, Trapane P, et al. Analysis of *B3GALTL* in Peters Plus syndrome. *Am J Med Genet A* 2008;146:2603–10.
- [6] Tuli N, Kumar S, Sood S. Peters Plus syndrome and absence of kidney: a case report. *Cases J* 2009;2:2.
- [7] Abu-Judeh HH, Merthrata S. Intestinal malrotation associated with Peter's anomaly. *J Pediatr Ophthalmol Strabismus* 2000;37:313–4.
- [8] Aubertin G, Kriek M, Lesnik Oberstein SAJ. Peters-Plus syndrome. In: Pagon RA, Bird TD, Dolan CR, Stephens K, Adam MP, editors. *Gene reviews™* [internet]. Seattle (WA): University of Washington, Seattle; 1993–2007.
- [9] Shawky RM, Sadik DI. Abnormal presentation of Peter's anomaly in a family with microcornea cataract syndrome. *Egypt J Med Hum Genet* 2009;10:111–4.
- [10] Shawky RM, Abdel-Khalek. Peter's Plus syndrome in an Egyptian patients with some unusual features. *Egypt J Med Hum Genet* 2010;11:69–72.
- [11] Frydman M, Weinstock AL, Cohen HA, et al. Autosomal recessive Peters anomaly, typical facial appearance, failure to thrive, hydrocephalus and other anomalies: further delineation of Krause–Kivilin syndrome. *Am J Med Genet* 1991;40:34–40.
- [12] Motoyama O, Arai H, Harada R, et al. A girl with Peters plus syndrome associated with myelomeningocele and chronic renal failure. *Clin Exp Nephrol* 2010;14:381–4.
- [13] Taiyabah N, Geiger EA, Warmock, et al. A 781-Kb deletion of 13q 12.3 in a patient with Peters Plus syndrome. *Am J Med Genet A* 2009;149A:1842–5.
- [14] Zaidman GW, Flanagan JK, Furey CC. Long-term visual prognosis in children after corneal transplant surgery for Peters anomaly type I. *Am J Ophthalmol* 2007;144:104–8.
- [15] Hennekam RC, Van Schooneveld MJ, Ardinger HH, Van Den Boogaard MJ, Friedburg D, Rudnik-Schoneborn S, et al. The Peters'-Plus syndrome: description of 16 patients and review of the literature. *Clin Dysmorphol* 1993;2:283–300.
- [16] Lee KW, Lee PD. Growth hormone deficiency (GHD): a new association in Peters' Plus syndrome (PPS). *Am J Med Genet A* 2004;124A:388–91.
- [17] Boog G, Le Vaillant C, Joubert M. Prenatal sonographic findings in Peters-Plus syndrome. *Ultrasound Obstet Gynecol* 2005;25:602–6.
- [18] Shimizu R, Saito R, Hoshino K, Ogawa K, Negishi T, Nishimura J, et al. Severe Peters Plus syndrome-like phenotype with anterior

- eye staphyloma and hypoplastic left heart syndrome: proposal of a new syndrome. *Congenit Anom (Kyoto)* 2010;50:197–9.
- [19] Aliferis K, Marsal C, Pelletier V, Doray B, Weiss MM, Tops CM, et al. A novel nonsense B3GALTL mutation confirms Peters plus syndrome in a patient with multiple malformations and Peters anomaly. *Ophthalmic Genet* 2010;31:205–8.
- [20] Heinonen TY, Maki M. Peters'-Plus syndrome is a congenital disorder of glycosylation caused by a defect in the beta1, 3-glucosyltransferase that modifies thrombospondin type 1 repeats. *Ann Med* 2009;41:2–10.
- [21] Schoner K, Kohlhase J, Müller AM, Schramm T, Plassmann M, Schmitz R, et al. Hydrocephalus, agenesis of the corpus callosum, and cleft lip/palate represent frequent associations in fetuses with Peters' plus syndrome and B3GALTL mutations. Fetal PPS phenotypes, expanded by Dandy Walker cyst and encephalocele. *Prenat Diagn* 2013;33:75–80.