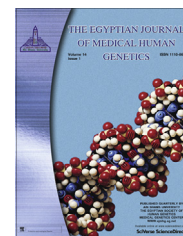




Ain Shams University

The Egyptian Journal of Medical Human Genetics

www.ejmhg.eg.net
www.sciencedirect.com



CASE REPORT

Oral-facial-digital syndrome type II: Transitional type between Mohr and Varadi

Rabah M. Shawky *, Solaf M. Elsayed, Heba S. Abd-Elkhalek, Shimaa Gad

Genetics Unit, Children's Hospital, Ain Shams University, Cairo, Egypt

Received 17 February 2013; accepted 12 March 2013

Available online 16 April 2013

KEYWORDS

Polydactyly;
Cleft lip;
Congenital heart;
Oral-facial-digital syndrome;
Mohr syndrome

Abstract We report a 2 months old boy, the first in order of birth of non-consanguineous parents, with several typical features of oral-facial-digital syndrome type II (OFDS II) including cleft lip, high arched palate, retromicrognathia, preaxial polysyndactyly of hands and feet, duplication of thumb and hallux. Interestingly, the patient also had mesoaxial polydactyly of the left hand with extra metacarpal bones characteristic of OFDS. VI, however mentality and MRI brain were normal. This unusual association may suggest an additional subgroup of OFDSs or a variant of OFDS II due to variable gene expression or a transitional type between OFDS II and OFDS VI.

© 2013 Production and hosting by Elsevier B.V. on behalf of Ain Shams University.

1. Introduction

Oral-facial-digital syndromes (OFDSs) consist of a group of heterogeneous disorders characterized by abnormalities in the oral cavity, face, and digits and associated phenotypic abnormalities that lead to the delineation of 13 OFDS subtypes with different modes of inheritance [1]. However, the features of the various types significantly overlap, and some types are not yet well defined. The classification system for oral-facial-digital syndromes continues to evolve as researchers find more affected individuals and learn more about this disorder [2].

Oral-facial-digital syndrome II (OFDS II) is characterized by frontal bossing, broad nasal bridge, midline cleft upper lip and palate, lobulated tongue, clinodactyly, syndactyly, brachydactyly, pre- and post axial polydactyly, and duplication of the first toe. Other systemic features include conductive deafness and congenital heart defects [3], however the molecular diagnosis is still unknown.

Here we report a case of OFDS showing several features of OFDS II (Mohr syndrome) with some overlapping features of OFDS VI (Varadi syndrome).

2. Case report

A two month old boy, the first in order of birth of non-consanguineous Egyptian parents, the age of the mother was 19 years, and the father was 27 years. The patient was 3.8 kg at birth (at 75th percentile) after normal vaginal delivery. During pregnancy the mother took effervescent tablets for treatment of urinary crystals between the 5th and 6th months of pregnancy, one injection for allergy at the 4th and again at the 8th month of pregnancy as well as vitamin supplementation.

* Corresponding author. Address: Pediatrics and Genetics, Faculty of Medicine, Ain Shams University, Cairo, Egypt. Tel.: +20 22661717; fax: +20 22585577.

E-mail address: shawkyrabah@yahoo.com (R.M. Shawky).

Peer review under responsibility of Ain Shams University.



Production and hosting by Elsevier

The patient was referred to the Genetics Clinics, Children's Hospital, Ain Shams University for his abnormal features, and allergic rash covering the whole body. There was no history of a similarly affected family member. At the age of two months, the patient had an average motor and mental development as he could support his neck, and started to recognize his mother. His weight was 3.4 kg (< 5th percentile), length was 53 cm (at 5th percentile) and skull circumference was 35 cm (< 5th percentile), with open anterior fontanel measuring 4 × 4 cm.

The patient had hairy forehead, transverse slanting palpebral fissures, with wide abnormal left nostril, broad nasal root, and small low set ears. The mouth showed non median left sided cleft lip and scar like tissue on the right side, hyperplastic frenula attaching the upper lip and the gum, with high arched narrow palate. There was retromicrognathia, microglossia, with small nodules on the under surface, and the right lateral side of the tongue, Fig. 1. The right hand showed preaxial thumb like polydactyly (6 fingers), with partial syndactyly of the thumb and the extra finger (duplication of the thumb), Fig. 2. The left hand also showed polydactyly (7 fingers), near complete cutaneous syndactyly between the 5th and 6th fingers, partial syndactyly between the 3rd and 4th, and between the 4th and 5th fingers (mesoaxial polydactyly), and duplication of the terminal phalange and nail of the thumb, Fig. 3.

The feet showed bilateral duplication of the big hallux with wide gap between them (6 toes), abnormal position of the second toe, medial deviations of the other toes, nail dysplasia with partial syndactyly between the 2nd and 3rd toes, Figs. 4 and 5.

Cardiac examination detected a harsh pansystolic murmur propagated all over the heart of grade 2. Chest, abdominal, and genital examinations were normal. Vision and hearing were also normal. Neurological examination showed normal tone and reflexes.

Feeding was normal at birth, and then the patient started to suffer from choking episodes, suggestive of aspiration at the age of 3 months. Therefore orogastric feeding via an infant feeding tube was started with expressed breast milk and artificial milk. The patient had repeated attacks of chest infection,

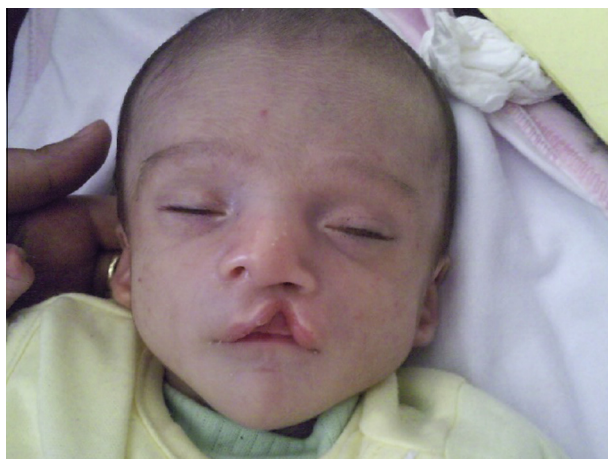


Figure 1 Facial features including hairy forehead, transverse slanting of palpebral fissures, with wide abnormal left nostril, broad nasal root, left lateral cleft lip and scar like tissue on the right side.

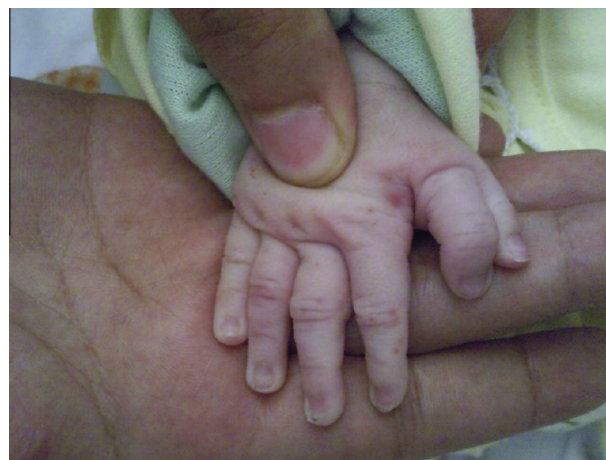

Figure 2 The right hand showed preaxial polydactyly (6 fingers), with partial syndactyly of the thumb and the extra finger.

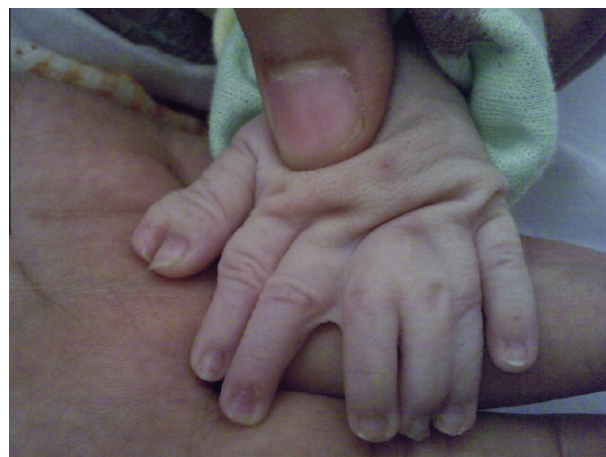

Figure 3 The Left hand showing polydactyly (7 fingers), near complete syndactyly between the 5th and 6th fingers, partial syndactyly between the 3rd and 4th, and the 4th and 5th fingers, as well as duplication of the terminal phalanges of the thumb.

and then he died at the age of 4 months with aspiration pneumonia.

X-ray of the right hand showed radial polydactyly in the form of duplication of the thumb, with its two metacarpal bones fused in their proximal three fourths, Fig. 6. X-ray of the left hand showed mesoaxial polydactyly (6 metacarpal bones), with the proximal phalanx of the middle finger fused with the duplicated one at its head. It also showed radial polydactyly with complete duplication of the thumb (extra metacarpal and phalanges are seen), Fig. 7. X-ray of both feet showed preaxial polydactyly of the first ray, in the form of the presence of extra metatarsal and phalanges of the big toe. The second metatarsal bone is relatively short (Fig. 8).

Echocardiography showed common atrioventricular canal (AVC) with pulmonary hypertension. Laryngoscopy showed epiglottic hypoplasia. Abdominal ultrasonography, and MRI brain showed no abnormalities. Karyotype revealed 46, XY normal male karyotype.

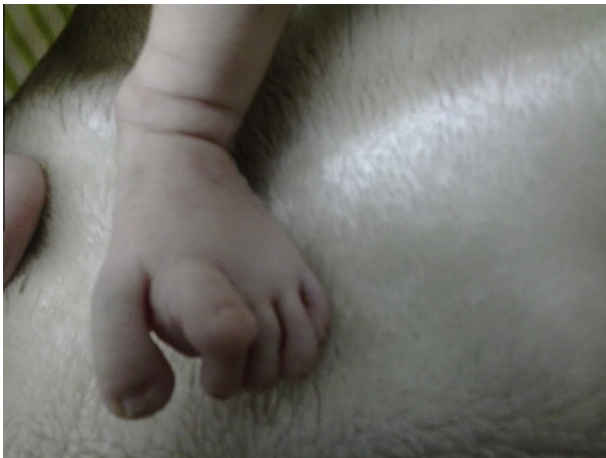

Figure 4 The left foot showing median incurving of the 3rd, 4th, 5th, and 6th toes, wide gap between the 1st and 2nd toes. Low insertion of the 1st toe, duplicated hallux, and nail dysplasia.



Figure 5 The right foot showing median incurving of the 3rd, 4th, 5th, and 6th toes. Wide gap between the 1st and 2nd toes. Low insertion of the 1st toe, duplicated hallux, and nail dysplasia.

3. Discussion

The first oral-facial-digital syndrome was described in 1941 by Mohr, followed by a report by Papillon-Léage and Psaume of another case in 1954. Ironically, these became known as oral-facial-digital syndrome (OFDS) II and I, respectively. Since then, numerous other examples of OFDS have been published [4].

The oral-facial-digital syndromes (OFDSs) result from the pleiotropic effect of a morphogenetic impairment affecting almost invariably the mouth, face and digits. Other organ systems can be involved, defining specific types of OFDS. Thirteen types have been distinguished based on characteristic clinical manifestations [5].

Our patient had several typical and common features of Mohr syndrome (OFDS II) along with some uncommonly reported features. Typical features included small tongue nodule, high arched narrow palate with a thick ridge in its middle, hypertelorism, small low set ears, broad and low nasal root,

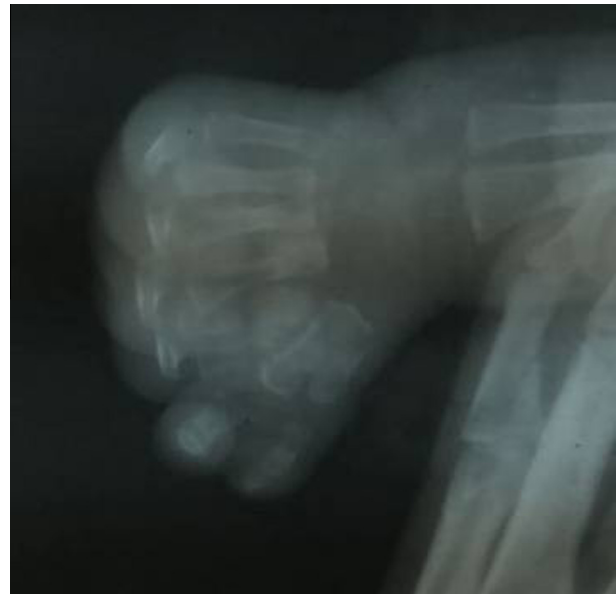


Figure 6 X-ray of the right hand.

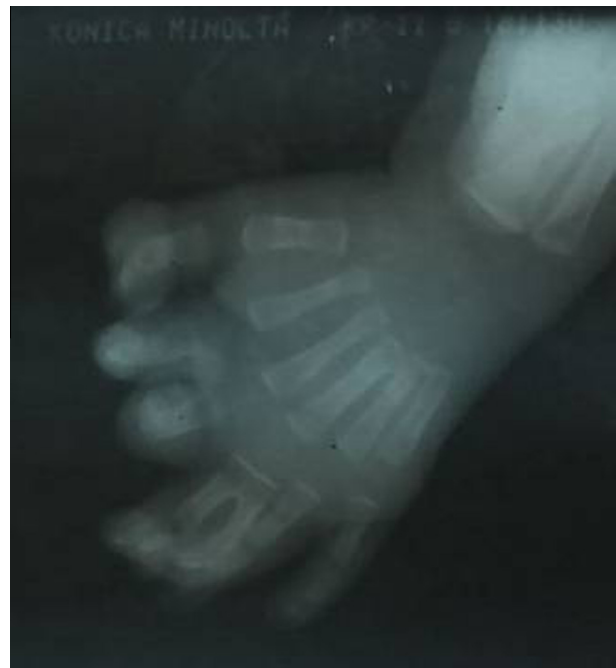

Figure 7 Left hand X-ray.

left sided partial cleft lip, and retromicrognathia. Typically in patients with OFDS II, the hands show postaxial polydactyly, and the feet show preaxial polydactyly [6]. Our patient showed preaxial polysyndactyly in both hands, as well as in both feet, with bilateral duplication of the hallux.

No additional skeletal anomalies were detected in our patient as scoliosis and pectus excavatum reported in some OFDS II [7]. What was striking in our patient was the presence of mesoaxial polydactyly of the left hand (7 fingers with duplicated thumb) with extra metacarpals, and Y shaped metacarpodigital bones of the 4th and 5th fingers, in addition to cutaneous syndactyly which is nearly complete between the

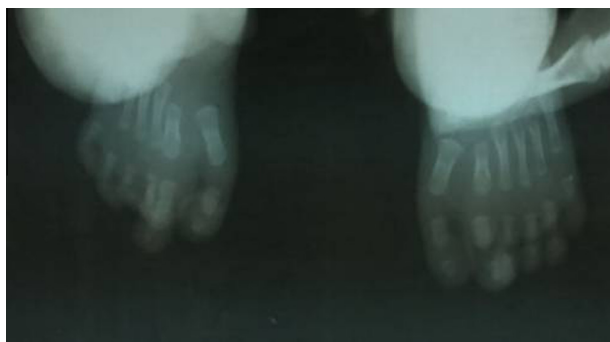

Figure 8 X-ray of the feet.

5th and 6th fingers. There was also a Y shaped metacarpal bone of the duplicated right thumb. Also the duplicated hallux of our patient included two separate toes with a wide gap between them, and low insertion of the first toe. The nails were slightly dysplastic which to our knowledge, was not reported before in OFDS II.

Mesoaxial polydactyly arising from the additional central metacarpal bone or from a bifid or Y shaped third metacarpal bone is the characteristic limb manifestation of OFDS VI which is a rare phenotypic subtype of Joubert syndrome and related disorders. This type is usually diagnosed by the molar tooth sign in MRI brain together with one of the following features: (1) Tongue hamartoma(s), and/or additional frenula and/or upper lip notch. (2) Mesoaxial polydactyly of one or more hands or feet. (3) Hypothalamic hamartoma [8]. However, mentality and MRI brain were normal in our patient which makes the diagnosis of OFDS VI so unlikely.

Our patient also suffered from left sided partial cleft lip with a remnant scar on the right side. Typical OFDS II patients have a midline pseudocleft of the inferior vermilion border of the upper lip giving the upper lip a distinctive feline appearance. However asymmetric true clefts can occur. Also midline complete or submucous clefts in the primary or secondary palate are common in these patients [9].

Our patient had two lingual nodules. Lingual hamartomas exist as one or more nodules in the tongue that histologically are composed of benign muscles, adipose tissues and salivary glands. Some lesions have a more lipomatous than hamartomatous appearance [10]. He also had epiglottic hypoplasia which caused recurrent aspiration pneumonia. Laryngeal anomalies were reported repeatedly in literatures in OFDS II [11]. Vision and hearing were normal in our patient although conductive hearing loss is usually reported in OFDS II [3].

Echo cardiography demonstrated common atrioventricular canal (AVC), with pulmonary hypertension. Congenital heart defects although an uncommon finding in OFDS II, they have been described in few patients with this syndrome [12]. They included AVC, common atrium, and truncus arteriosus [13], ventricular septal defect, and mitral atresia [14], AVC, and aortic coarctation [15], aortic coarctation, and common atrium [16].

Intelligence and MRI brain were normal in our patient as is usually reported in the majority of OFDS II patients [17]. However, intellectual deficit and MRI changes were reported in some patients with OFDS II. They included cerebellar atrophy, cerebellar abnormalities [6], Dandy–Walker malformations, hydrocephalus, and hamartomas in the hypothalamic area [18].

OFDS II is usually inherited in an autosomal recessive manner. In our patient no consanguinity was present among the parents although they belong to the same governorate in Egypt. Also there is no history of a similar condition in the family. So we consider our case as sporadic or inherited in an autosomal recessive manner as he is the first and the only child of his parents.

The early presentation of our patient to hospital was due to an allergic reaction covering the whole body, which was also reported previously in OFDS II [18]. Our patient suffered from recurrent respiratory infections, and this was the cause of death of this infant at 4 months. Susceptibility to respiratory infection was reported in other OFDS II patients [19].

Our patient has almost similar clinical features described by Hsieh and Hou (both preaxial and central polydactyly of the hands with Y shaped fourth metacarpals) characteristics of OFDS VI, plus AVC, and hypoplasia of the epiglottis [20].

Clinical heterogeneity of OFDS II has supported the existence of different subtypes [17,21]. These include variants with central nervous system involvement and associated brain malformations (the Dandy–Walker syndrome) [17]. Other variants presented with laryngeal anomalies and hallucal and post axial polydactyly of feet which are typically observed in Majewski syndrome [22]. Okten, et al. described a patient with manifestations overlapping with OFDS II, IV, and VI [23]. Steichen-Gersdorf et al. also reported a patient with laryngeal anomalies [11].

Due to the high variability in clinical expression even among intrafamilial cases of OFDS some of the abnormalities of OFDS are present in some patients and not in others [24]. Efforts to subtype OFDS into distinct phenotype variants have met with criticism from those who believe that many or perhaps all of the variants of OFDS arise from a single gene mutation [25]. This criticism appears justified based on reported family members with distinctive findings of more than one variant of OFDS. Significant overlap also exists between the types and patients may be classified as having transitional type of OFDS when features of several types exist. In addition the molecular genesis is still unknown for most of OFDS except for type 1 which is related to the CXORF 5 gene (Xp22.2–22.3) coding for OFD1 protein [26]. No major gene has been consistently associated with OFDS VI and the mutation in TMEM216 gene remains occasional [8].

Our patient may represent an additional subgroup of OFDS or as a variant of OFDS II due to variable gene expression or a transitional type between OFDS II and OFDS VI.

To conclude: our patient supports the hypothesis that clinical variability of Mohr syndrome is wider than previously thought. Until now classification is complex making the process of describing new types of OFDS demanding. In order to achieve the correct diagnosis and offer adequate genetic counseling, it is necessary to search for possible abnormalities associated with OFDS spectrum of defects.

References

- [1] Thomas S, Legendre M, Saunier S, Bessières B, Alby C, Bonnière M, et al. TCTN3 mutations cause Mohr-Majewski syndrome. *Am J Hum Genet* 2012;10(91):372–8.
- [2] Oral-facial digital syndrome. Genetics home reference. ghr.nlm.nih.gov/condition/oral-facial-digital-syndrome. Reviewed: February 2010, Published: January 17, 2013.

- [3] Basu K, Chatterjee S, Ghosh JK, Sinha MKR. Mohr–Claussen or oral-facial digital syndrome OFDS type II. *J Pak Med Assoc* 2009;59:486–8.
- [4] Toriello HV. Are the oral-facial-digital syndromes ciliopathies? *Am J Med Genet A* 2009;149A:1089–95.
- [5] Gurrieri F, Franco B, Toriello H, Neri G. Oral-facial-digital syndromes: review and diagnostic guidelines. *Am J Med Genet A* 2007;143A:3314–23.
- [6] Annerén G, Gustavson KH, Józwiak S, Kjartansson S, Strömberg B. Abnormalities of the cerebellum in oro-facio-digital syndrome II (Mohr syndrome). *Clin Genet* 1990;38:69–73.
- [7] Vazquez Marie-Paule. Oral-facial digital syndrome II. 2009 The portal for rare disease and orphan drug. http://www.orpha.net/consor/cgi-bin/OC_Exp.php?lng=en&Expert=2751.
- [8] Poretti A, Vitiello G, Hennekam RC, Arrigoni F, Bertini E, Borgatti R, et al. Delineation and diagnostic criteria of oral-facial-digital syndrome type VI. *Orphanet J Rare Dis* 2012;11, 7-4.
- [9] Siehert J.R, Samat H.B. Oral-facial digital syndromes. Clinical summary (preview) last updated: 2012. www.medlink.com/medlinkcontent.asp.
- [10] Ghossaini SN, Hadi N, Tawil A. Oral-facial digital syndrome type II variant associated with congenital tongue lipoma. *Oral Surg Oral Med Oral Pathol Oral Radiol Endocrinol* 2002;94:324–7.
- [11] Steichen-Gersdorf E, Gassner I, Covi B, Fischer H. Oral-facial-digital syndrome II. Transitional type between Mohr and Majewski syndrome: report of a new case with congenital stenosis of the trachea. *Clin Dysmorphol* 1994;3:245–50.
- [12] Goudar PHK, Joshi R, Hiremath SV, Gai PB. Mohr syndrome: a rare case of oro-facial-digital syndrome type II with congenital heart disease. *Int J Case Rep Images* 2012;3:32–5.
- [13] Cordero JF, Holmes LB. Heart malformations as a feature of the Mohr syndrome. *J Pediatr* 1977;91:683–4.
- [14] Ja Ccarino M, Lonardo F, Giuglionio M, Della Bruuna M. Prenatal diagnosis of Mohr syndrome by ultrasonography. *Prenat Diagn* 1985;5:415–8.
- [15] Orstavik KH, Lindemann R, Solberg LA, Foerster A, Sorland SJ. Congenital heart defects, hamartomas of the tongue and polydactyl in a sister and brother. *Clin Genet* 1992;42:19–21.
- [16] Digilio MC, Marino B, Giannotti A, Dallapiccola B. Orocardio-digital syndrome: an oral-facial-digital type II variant associated with atrioventricular canal. *J Med Genet* 1996;33:416–8.
- [17] Haumont D, Pelc S. The Mohr syndrome: are there two variants? *Clin Genet* 1983;24:41–6.
- [18] Large C, Pintodaa Silva L, Fonseca L, Cruz R. Diagnostic and clinical procedures of a patient with oral-facial digital syndrome type II syndrome: a case report. *J Clin Exp Dent* 2011;3:e261–4.
- [19] Gustavson KH, Kreuger A, Petersson PO. Syndrome characterized by lingual malformation, polydactyly, tachypnea, and psychomotor retardation (Mohr syndrome). *Clin Genet* 1971;2:261–6.
- [20] Hsieh YC, Hou JW. Oral-facial digital syndrome with Y shaped fourth metacarpals and endocardial cushion defect. *Am J Med Genet* 1999;86:278–81, 17.
- [21] Camera G, Marastini M, Pozzolo S, Camera A. Oral-facial digital syndrome: report of a transitional type between the Mohr and Varadi syndrome in a fetus. *Am J Med Genet* 1994;53:196–8.
- [22] Silengo MC, Bell GL, Biagioli M, et al. Oro-facial-digital syndrome II. Transitional type between the Mohr and the Majewski syndromes: report of two new cases. *Clin Genet* 1987;31:331.
- [23] Oktem A, Mungan L, Orphan F, Cakir M. Hypothalamic hamartoma, cerebellar hypoplasia, facial dysmorphism and very atypical combination of polydactyl: is it a new variant of oral-facial digital syndrome? *Genet Couns* 2005;16:101–5.
- [24] Rimoin DL, Edgerton MT. Genetic and clinical heterogeneity in the oral-facial digital syndromes. *J Pediatr* 1967;71:94–102.
- [25] Neri G, Gurrieri F, Genuardi M. Oral-facial-skeletal syndromes. *Am J Med Genet* 1995;59:365–8.
- [26] Ferrante MI, Giorgio G, Feather SA, et al. Identification of the gene for oral-facial digital syndrome type I. *Am J Hum Genet* 2001;68:569–76.