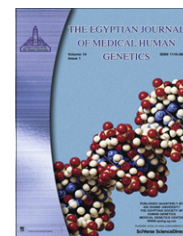




Ain Shams University

The Egyptian Journal of Medical Human Genetics

www.ejmhg.eg.net  
www.sciencedirect.com



## CASE REPORT

# Cornelia-de Lange syndrome in an Egyptian infant with unusual bone deformities

Rabah M. Shawky <sup>a,\*</sup>, Heba Salah Abd-Elkhalek <sup>a</sup>, Shimaa Gad <sup>a</sup>,  
Shaimaa Abdelsattar Mohammad <sup>b</sup>, Neven S. Seifeldin <sup>c</sup>

<sup>a</sup> Pediatric Department, Genetics Unit, Ain Shams University, Egypt

<sup>b</sup> Department of Diagnostic Radiology and Medical Imaging, Ain Shams University, Egypt

<sup>c</sup> Dermatology and Venereology Department, Ain Shams University, Egypt

Received 11 April 2012; accepted 22 April 2012

Available online 18 May 2012

### KEYWORDS

Cornelia-de Lange syndrome;  
Bony deformities;  
Pulmonary artery branch stenosis;  
Rickets;  
Arachnodactyly

**Abstract** We report a 4 month old female infant with the typical features of Cornelia-de Lange syndrome. What was striking in our patient was the presence of skeletal anomalies not reported previously. These included arachnodactyly of both fingers and toes, flexion of thumbs at metacarpophalangeal joints, bilateral short big toes, angulation of the lower part of the bones of right forearm and both legs with multiple skin folds. Also biochemical and X-ray evidence of rickets was detected mostly due to malnutrition and failure to thrive. The patient died at the age of 5 months with bronchopneumonia and gastroenteritis.

© 2012 Ain Shams University. Production and hosting by Elsevier B.V. All rights reserved.

## 1. Introduction

Cornelia-de Lange syndrome (CdLS; OMIM 122,470) or Brachman de Lange syndrome is a dominantly inherited disorder characterized by multisystem involvement, cognitive delay, limb defects, characteristic facial features [1], hirsutism, internal organ anomalies, including diaphragmatic hernia [2], severe growth and developmental delay, abnormalities of the

upper limbs [3], pre- and post-natal growth defects, and small hands [4]. CdLS is a rare syndrome and affects between 1/10,000–1/60,000 neonates [5].

Here, we present a 4 month old patient, with the typical features of CdLS but with different skeletal anomalies after taking consent of the parents.

## 2. Case report

A 4 month old female patient, third in order of birth of healthy first cousin consanguineous parents, mother 28 years, father 33 years, with low birth weight after full term vaginal delivery, and uncomplicated pregnancy, perinatal, and post natal period. The mother received multivitamins, and Daflon for one week because of varicose veins affecting her both lower limbs during pregnancy.

\* Corresponding author.

E-mail address: shawkyrabah@yahoo.com (R.M. Shawky).

Peer review under responsibility of Ain Shams University.



Production and hosting by Elsevier

The patient was referred to the Genetics Clinics, Pediatric Hospital, Ain Shams University complaining of deformities in the right upper limb and both lower limbs dating since birth. There was no family history of a similarly affected family member. Her weight was 3 kg (< 5th percentile), length is 47 cm (< 5th percentile). The skull circumference was 35 cm (< 5th percentile), with brachycephalic shape and open anterior fontanel measuring 2 × 2 cm.

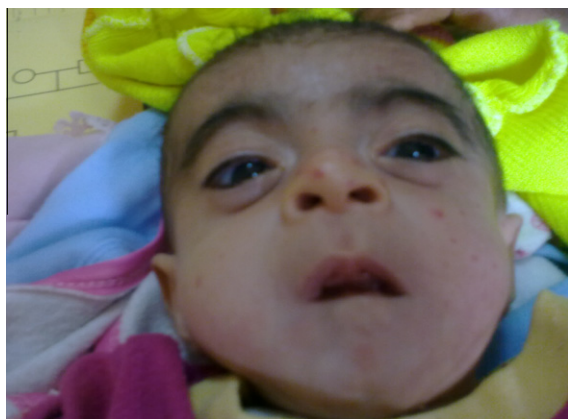On examination the patient had low anterior hair line, hairy forehead, thick eyebrows with partial synophrys, transverse slanting palpebral fissures, no epicanthic folds, small nose with broad root, upturned nares, low set posteriorly rotated ears, and long filtrum. The mouth was small crescent shaped with thin upper lip, gums were hypertrophied, and the palate was narrow and high arched. The patient also had retromicrognathia, low posterior hair line, and short neck with skin folds (Fig. 1).

The upper and lower limbs had multiple incomplete skin folds. There was bilateral partial simian creases in both hands, right medial and anterior angulation of the right forearm, bilateral anterior angulation of lower legs, arachnodactyly of both fingers and toes but the big toe was shorter than other toes. The heels were bilaterally prominent (Figs. 2–4). The back had mongolian spots, hypertrichosis with no sacral dimple.

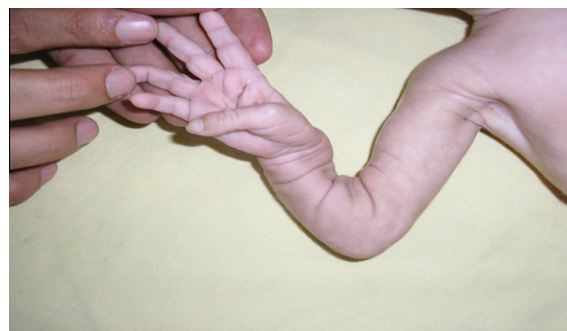Chest examination showed small chest, depressed lower sternum (pectus excavatum) with prominent ribs. Abdominal examination was normal apart from generalized abdominal distention, and right oblique inguinal hernia (Fig. 4). No audible murmur was detected on cardiac examination. Neurological examination detected moderate mental retardation, wasted muscles and normal tone.

ECHO cardiography showed mild left pulmonary artery branch stenosis. Audiometry detected bilateral mild high frequency sensorineural hearing loss. Abdominal ultrasonography was normal.

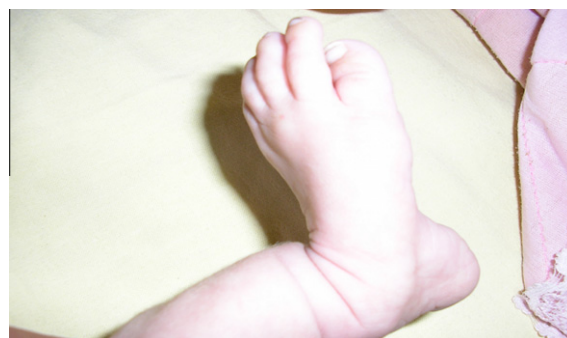Radiographs showed that there was a generalized decrease in bone density, subperiosteal new bone formation. Subperiosteal erosion was noted at the medial aspect of the femur, and there was an increase in metaphyseal cupping, broadening, fraying (evidence of rickets), and metaphyseal lucent bands. There was angulation of the lower part of tibia and fibula bilaterally. The first tarsal and metatarsal bones of the big toe were relatively shortened especially on the left side. The



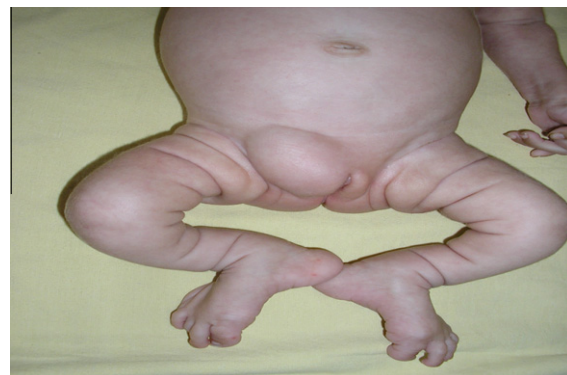
**Figure 1** Facial features with hypertrichosis of forehead, partial synophersous, crescent shaped mouth, short neck, and low set ears.



**Figure 2** Proximal insertion of the thumb, arachnodactyly with flexed thumb, and incomplete skin folds in the forearm.



**Figure 3** Short big toe with long other toes.

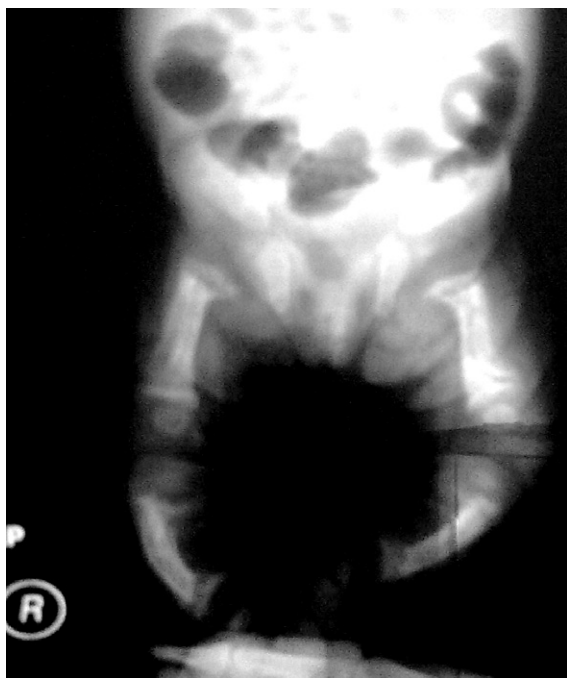

**Figure 4** Deformed lower limbs, long feet, incomplete skin folds, rocker bottom heel, and right inguinal hernia.

distal metaphyseal ends of both right radius and ulna show angulation with lucent line with bubbly appearance. The left forearm is spared. Also the pitch of the ribs was more horizontal than usual in chest X-ray (Figs. 5 and 6).

Fundus picture, karyotype, the screen for aminoacids and thyroid function were normal. MRI brain detected brain atrophy as well as abnormal configuration of the skull (elongated cranio-caudal dimension). Serum calcium was normal 10 mg/dL (normal level, 8.6–10.2 mg/dL), with low phosphate 3.1 mg/dL (normal level, 4.5–5.5 mg/dL), elevated alkaline phosphatase 874  $\mu$ /L (normal level, 35–462  $\mu$ /L), and normal serum albumin levels.

The patient died at the age of 5 months with bronchopneumonia and gastroenteritis.



**Figure 5** Congenital bowed tibia and fibula, and evidence of ricket.



**Figure 6** Short first tarsal and metatarsal bones especially of the left foot.

### 3. Discussion

Our patient had many of the characteristic features of classic CdLS including microbrachycephaly, hypertelorism, well defined eyebrows with long eyelashes and partial synophrys, long filtrum, crescent shaped mouth, low set posteriorly rotated ears, mental retardation, prenatal and postnatal growth retardation, small nose with upturned nares, hypertrichosis more marked on the forehead, and center of the back, and bilateral partial simian creases.

Our patient also had some features which to the best our knowledge were not reported previously. These included slightly hypertrophied gums, skin folds at the nape of the neck, incomplete grooves which forms skin folds in both upper and lower limbs, arachnodactyly, and bony deformities in the right upper and both lower limbs.

In CdLS the most consistent and diagnostic skeletal anomalies affect the upper extremities. These range in severity from gross hemimelia and phocomelia to only mild deformities of

the hands. Hypoplasia, dorsal dislocation of radial heads, hypoplasia of varying degrees of first metacarpal bones and middle phalanx of the shortened incurved fifth finger were also reported. The combination of elbow and hand changes is the most frequent skeletal abnormalities reported in CdLS [6]. However these findings were not reported in our patient. The ribs were also reported to be more straight [6], as detected in our patient. On the other hand our patient had small chest, pectus excavatum, arachnodactyly of both fingers and toes with bilateral flexion of the thumbs at metacarpophalangeal joints, short big toes because of short first metatarsals. Also there was angulation of the lower part of the bones of the right forearm as well as bones of both legs since birth. These findings have not been reported previously. What was striking was the detection of biochemical and X-ray findings of rickets in epiphysis of wrists and ankle joints, most probably due to malnutrition.

Gastro-intestinal problems including pyloric stenosis, gastro-esophageal reflux [7], intestinal malrotation with volvulus [8], and congenital diaphragmatic hernia as well as omphalocele [9] were reported in patients with CdLS. Our patient had only right oblique inguinal hernia as well as failure to thrive.

Congenital heart malformations were diagnosed in 14% of children with CdLS. Most common are ventricular septal defects, pulmonary stenosis, and tetralogy of Fallot [10]. ECHO cardiography detected mild left pulmonary artery branch stenosis in our patient.

Audiometry in our patient showed bilateral mild high frequency sensorineural hearing loss. Hearing deficits from mild to severe may be present in 50–60% of all CdLS patients. In 16.7% of cases the conduction hearing loss was connected with chronic diseases of middle ear which required medical treatment. In the remaining 33.3% of cases it is due to sensorineural hearing loss [10,11].

Ophthalmic findings reported in CdLS including nystagmus, high myopia, optic nerve pallor, poor macular reflex, hypertropia, and nasolacrimal duct fistula [12] were not present in our patient.

Other problems reported in CdLS including urinary tract anomalies, male hypogonadism and cryptorchidism in males, seizures, heat intolerance sensation, and absence of pain sensation were not reported in our patient [13].

MRI of the brain in our patient demonstrated brain atrophy. Some autopsy data have indicated cerebral dysgenesis, with decreased number of neurons, neuronal heterotopias, and focal gyral folding abnormalities as causes of psychomotor delay [13].

In our patient the parents were first cousins and both did not show any features of CdLS, and there is no family history of a similarly affected case, so most probably our patient had autosomal recessive inheritance or sporadic. More than 99% of CdLS cases are sporadic. However it is occasionally transmitted in an autosomal dominant pattern in which a usually mildly affected parent had one or more affected offspring. Although autosomal recessive inheritance has been reported in some families, these instances were likely to be due to germ line mosaicism. The recurrence risk is 0.5–1.5% if parents are unaffected, and 50% if a parent is affected [13].

Heterozygous mutations in NIPBL gene have been identified in approximately 50% of CdLS patients [3,14] Although the exact function of the protein product of NIPBL in humans (delangin) remains unknown, its homologues in other species are known to play roles in developmental regulation and

cohesion of sister chromatids. Mutations in genes coding for two other proteins involved in cohesion of sister chromatids, SMC1A and SMC3 have been reported in 5% and 1% of patients with CdLS respectively [15]. Inheritance is autosomal dominant in families with NIPBL and SMC3 mutations, and is X-linked dominant in families with SMC1A mutations [13]. However, in a considerable proportion of individuals with CdLS phenotype mutations in any of these are not found and other potential loci harbouring additional CdLS causing genes should be considered [3].

The correlation between genotype and phenotype suggested that individuals with an identifiable mutation in NIPBL have a phenotype more severe than the phenotype of those without mutations. Moreover, missense mutations in NIPBL are associated with mild phenotypic features. Patients with mutations in SMC1A and SMC3 consistently have a milder phenotype, with absence of severe limb defects and other structural anomalies [13].

The karyotype was normal in our patient, however numerous chromosomal rearrangements have been reported in individuals with CdLS. These rearrangements may be causative of a CdLS phenotype, result in a phenocopy, or be unrelated to the observed phenotype. In two half siblings with a der(3)t(3;12)(p25.3;p13.3) chromosomal rearrangement, clinical features resembling CdLS, and phenotypic overlap with the del(3)(p25) phenotype was reported [1]. Also 8p23.1 deletion with features of CdLS and congenital diaphragmatic hernia was reported which discuss a potential relationship between 8p23.1 deletions and CdLS and suggest a novel candidate gene for CdLS-Tankyrase 1 [2]. To detect chromosomal rearrangements pointing to novel positional candidate CdLS genes, array-CGH was used to analyze a subgroup of 24 CdLS patients negative for mutations in the NIPBL and SMC1L1 genes. Three carriers of DNA copy number alterations were identified, including a de novo 15q26.2-qter 8-Mb deletion, and two inherited 13q14.2-q14.3 1-Mb deletion and 13q21.32-q21.33 1.5-Mb duplication, not reported among copy number variants. The clinical presentation of all three patients matched the diagnostic criteria for CdLS, and the phenotype of the patient with the 15qter deletion is compared to that of both CdLS and 15qter microdeletion patients [4].

Our patient died at the age of 5 months with bronchopneumonia and gastroenteritis. Respiratory causes including aspiration/reflux and pneumonias were the most common primary causes of death in propositi with CdLS at various ages (31%), followed by gastrointestinal disease, including obstruction/volvulus (19%). Congenital anomalies accounted for 15% of deaths and included congenital diaphragmatic hernia and congenital heart defects. Acquired cardiac disease accounted for 3% of deaths. Neurological causes and accidents each accounted for 8%, sepsis for 4%, cancer for 2%, renal disease for 1.7%, and other causes, 9% of deaths [16].

The diagnosis CdLS can be suspected prenatally in the second trimester by a set of typical dysmorphisms noted by prenatal ultrasound, and can be diagnosed in fetuses after induction or newborns at birth as the typical phenotype is present early [17]. Molecular analysis of NIPBL can also be helpful [17,18].

To conclude CdLS is a rare disorder. Genotype phenotype correlation is still under research as long as new candidate genes are discovered. This case is a contribution to the clinical presentation of the disorder as new findings are reported.

## References

- [1] DeScipio C, Kaur M, Yaeger D, Innis JW, Spinner NB, Jackson LG, Krantz ID. Chromosome rearrangements in cornelia-de Lange syndrome (CdLS): report of a der(3)t(3;12)(p25.3;p13.3) in two half sibs with features of CdLS and review of reported CdLS cases with chromosome rearrangements. *Am J Med Genet A*. 2005;1137A(3):276–82.
- [2] Baynam G, Goldblatt J, Walpole I. Deletion of 8p23.1 with features of Cornelia-de Lange syndrome and congenital diaphragmatic hernia and a review of deletions of 8p23.1 to 8pter? A further locus for Cornelia-de Lange syndrome. *Am J Med Genet A*. 2008 15;146A(12):1565–70.
- [3] Schoumans J, Wincent J, Barbaro M, Djureinovic T, Maguire P, Forsberg L, et al. Comprehensive mutational analysis of a cohort of Swedish Cornelia-de Lange syndrome patients. *Eur J Hum Genet* 2007;15(2):143–9.
- [4] Gervasini C, Pfundt R, Castronovo P, Russo S, Roversi G, Masciadri M, et al. Search for genomic imbalances in a cohort of 24 Cornelia-de Lange patients negative for mutations in the NIPBL and SMC1L1 genes. *Clin Genet* 2008;74(6):531–8.
- [5] Verma L, Passi S, Gauba K. Brachman de Lange syndrome. *Contemp Clin Dent* 2010;1(4):268–70.
- [6] Lee FA, Kenny FM. Skeletal changes in Cornelia-de Lange syndrome. *AJR* 1967;100(1):27–39.
- [7] Rosenbach Y, Zahavi I, Dinari G. Gastro-esophageal dysfunction in Brachmann-de Lange syndrome. *Am J Med Genet* 1992;42(3): 379–380.
- [8] Masumoto K, Izaki T, Arima T. Cornelia-de Lange syndrome associated with cecal volvulus: report of a case. *Acta Paediatr* 2001;90(6):701–3.
- [9] Cunniff C, Curry CJ, Carey JC, et al. Congenital diaphragmatic hernia in the Brachmann-de Lange syndrome. *Am J Med Genet* 1993;47(7):1018–21.
- [10] Jackson L, Kline AD, Barr MA, Koch S. De Lange syndrome: a clinical review of 310 individuals. *Am J Med Genet*. 1993;47(7), 940-940.
- [11] Kozowski J, Wierzbza J, Narozny W, Balcerska A, Stankiewicz C, Kuczowski J. Auditory function in children with Brachmann-de Lange syndrom. *Otolaryngol Pol* 2006;60(4):577–81.
- [12] Levin AV, Seidman DJ, Nelson LB, Jackson LG. Ophthalmic findings in the Cornelia-de Lange syndrome. *J Pediatr Ophthalmol Strabismus* 1990;27(2):94–102.
- [13] Tekin M, Buchler B, et al. Cornelia de Lange syndrome. Medscape, drugs, Disease and Procedures. <http://emedicine.medscape.com/article/942792-overview>. Updated:Dec20,2011.
- [14] Gillis LA, Mc Callum J, Kaur M, et al. NIPBL mutational analysis in 120 individuals with Cornelia-de Lange syndrome and evaluation of genotype–phenotype correlations. *Am J Hum Genet* 2004;75:610–23.
- [15] Deardorff MA, Kaur M, Yaeger D, et al. Mutations in cohesion complex members SMC3 and SMC1A cause a mild variant of Cornelia-de Lange syndrome with predominant mental retardation. *Am J Hum Genet* 2007;80(3):485–94.
- [16] Schrier SA, Sherer I, Deardorff MA, Clark D, Audette L, Gillis L, et al. Causes of death and autopsy findings in a large study cohort of individuals with Cornelia de Lange syndrome and review of the literature. *Am J Med Genet A* 2011;155A(12): 3007–3024.
- [17] Wilmink FA, Papatsonis DN, Grijseels EW, Wessels MW. Cornelia de lange syndrome: a recognizable fetal phenotype. *Fetal Diagn Ther* 2009;26(1):50–3.
- [18] Lalatta F, Russo S, Gentilin B, Spaccini L, Boschetto C, Cavalleri F, et al. Prenatal/neonatal pathology in two cases of Cornelia de Lange syndrome harboring novel mutations of NIPBL. *Genet Med* 2007;9(3):188–94.