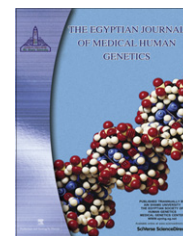




Ain Shams University

The Egyptian Journal of Medical Human Genetics

www.ejmhg.eg.net  
www.sciencedirect.com



## CASE REPORT

# Trigonocephaly and Dandy walker variant in an Egyptian child – Probable mild Opitz trigonocephaly C syndrome

Rabah M. Shawky \*, Heba Salah Abd-Elkhalek

*Pediatric Department, Genetics Unit, Ain Shams University, Egypt*

Received 2 September 2011; accepted 24 October 2011

Available online 11 December 2011

### KEYWORDS

Dandy walker malformation  
– Dandy walker variant;  
Craniosynostosis;  
Trigonocephaly

**Abstract** We report a one year old male patient with slight upward slanting palpebral fissures, hypotelorism, bulbous nose, high arched narrow palate, low set ears, bilateral partial simian creases, short neck with loose skin over it, thick ridge over the metopic suture giving a trigonocephaly, brachycephaly shape to the skull, hypoplastic scrotum and bilateral undescended testes, and mild generalised hypotonia. Although most of the reported cases suffered from severe mental retardation, our patient had mild mental retardation. CT of the brain demonstrated Dandy walker variant and trigonocephaly. To our knowledge this anomaly was reported once before with Opitz trigonocephaly C syndrome (OTCS). We consider our patient as a mild form of OTCS and he needs close follow up because over time there may be a developmental delay, severe mental retardation and seizures.

© 2012 Ain Shams University. Production and hosting by Elsevier B.V. All rights reserved.

## 1. Introduction

Trigonocephaly is a congenital condition of premature in-utero fusion of the metopic sutures of the skull leading to a triangular shaped forehead or a pointed and ridged midline deformity

\* Corresponding author.

E-mail address: [shawkyrabah@yahoo.com](mailto:shawkyrabah@yahoo.com) (R.M. Shawky).

1110-8630 © 2012 Ain Shams University. Production and hosting by Elsevier B.V. All rights reserved.

Peer review under responsibility of Ain Shams University.

doi:10.1016/j.ejmhg.2011.10.003



Production and hosting by Elsevier

[1]. It may occur isolated or syndromic involving other abnormalities. It accounts for approximately 15–18% of simple (single) non-syndromic synostosis [2]. It is also associated with Optiz syndrome, Jacobsen syndrome, Muenke Syndrome, Baller–Gerold Syndrome, and Say-Meyer syndrome [3].

Dandy walker malformation, variant and mega cisterna magna are currently believed to represent a continuum of developmental anomalies on a spectrum that has been termed the Dandy walker complex [4,5]. Dandy walker malformation (DWM) is a rare congenital malformation that involves the cerebellum and fourth ventricle. It is characterized by the triad of complete or partial agenesis of the vermis, cystic dilatation of the fourth ventricle and an enlarged posterior fossa with upward displacement of lateral sinuses, tentorium and torcular herophili. This triad is typically found in association with supratentorial hydrocephalous which should be considered a complication rather than part of the malformation [6]. Dandy

walker variant (DWV) consists of vermian Hypoplasia and cystic dilatation of the fourth ventricle with a normal sized posterior fossa [7].

The association of DWM with intra- and extra-cranial congenital anomalies, developmental delay and hydrocephalous is well established. On the other hand the association of DWV with other congenital anomalies, radiographic abnormalities, incidence of hydrocephalous and developmental outcomes is largely limited to case reports [5].

Opitz trigonocephaly C syndrome (OTCS) (MIM#211750) is characterized by trigonocephaly and associated anomalies [8–10]. Zampino reported a child with OTCS and midline brain anomalies including DWM [11].

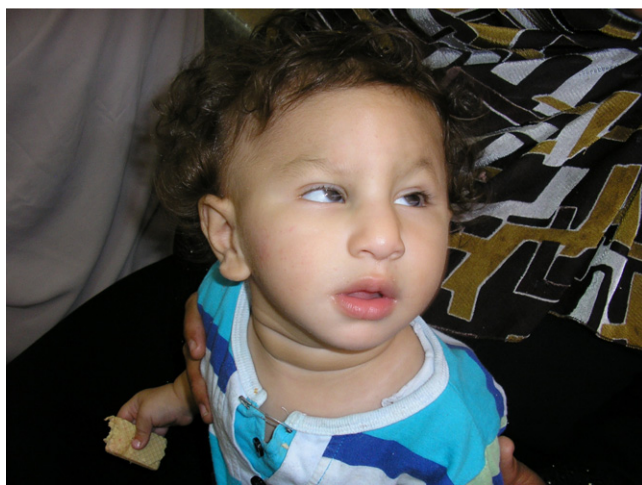We will report a patient having some of the features of OTCS with mild mental retardation as well as DWV.

## 2. Case report

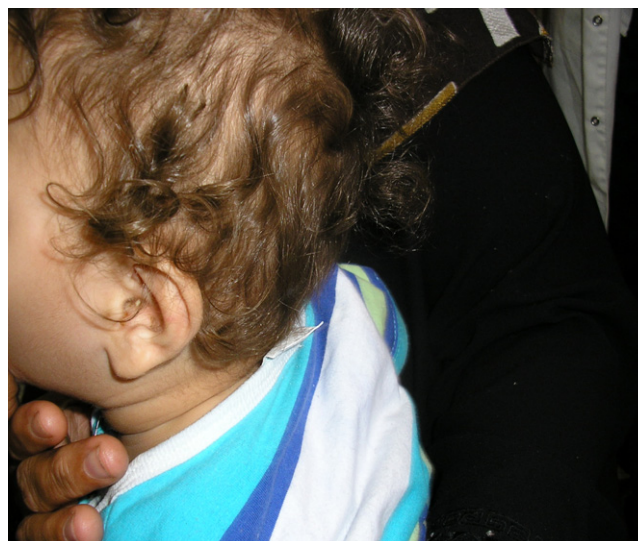A one year old male child, fifth in order of birth of nonconsanguineous parents living in Kaliobia, Egypt, with 3 kg weight at birth after CS delivery for post term and uncomplicated pregnancy, with no history of drug intake by the mother.

The patient was referred to the Genetics Clinics, Pediatric Hospital, Ain Shams University complaining of abnormal shape of the head since birth with no history of convulsions. He was the 5th in birth order of a healthy nonconsanguineous marriage. There was no family history of a similarly affected family member. The patient had an average motor and mental development as he could walk supported, grasp and transfer objects from hand to hand. The patient had mild mental retardation. His weight was 8.1 kg (<5th percentile), length is 71 cm (at 5th percentile). The skull circumference was 42cm, (<5th percentile) with a thick ridge over the metopic suture giving a trigonocephaly shape with open anterior fontanel measuring  $2 \times 2$  cm.

The patient had slight upward slanting of palpebral fissures, with bilateral convergent squint and no epicanthic folds, hypotelorism, bulbous nose with broad root, high arched narrow palate, large low set posteriorly rotated ears, with large ear lobules. Cheeks were full. The mouth and gums were normal



**Figure 1** Demonstrates trigonocephaly, facial features, and loose folded skin over the neck.



**Figure 2** Demonstrates large, low set, posteriorly rotated ear with large ear lobule.

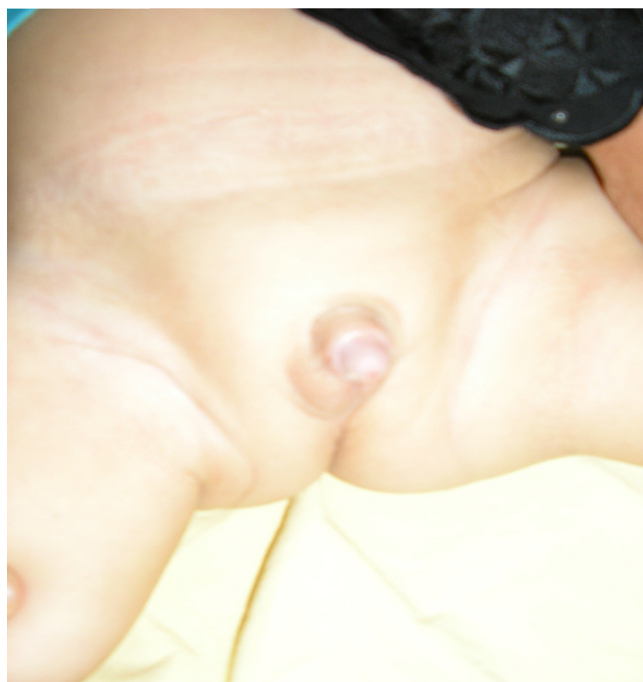with two upper and two lower teeth. There was slight micrognathia. The neck was short and skin over it was loose and folded (Figs. 1 and 2).

The limbs were normal. There was bilateral partial simian creases in both hands. The back was also normal with no sacral dimple. Chest and abdominal examination were normal. Cardiac examination demonstrated atrial septal defect. The scrotum was hypoplastic, with bilateral undescended testes (Fig. 3). Neurological examination detected mild generalised hypotonia with normally elicited reflexes.

ECHO cardiography confirmed atrial septal defect. Abdominal ultrasonography was normal. Ophthalmological examination was normal apart from bilateral convergent squint. Audiometry was also normal. CT brain showed lemon shaped skull with trigonocephaly as a result of premature closure of the metopic suture. Dilatation of the 4th ventricle communicating with retro cerebellar cistern (cisterna magna) yet without hydrocephalous, suggest Dandy walker variant case. Scrotal ultrasound demonstrated that both testes are present at deep inguinal ring with normal size.

## 3. Discussion

We report a one year old male patient with trigonocephaly and some facial features in favour of the diagnosis of OTCS. The facial features included crossed eyes, upslanting palpebral fissures, hypotelorism, bulbous nose, low set ears with large ear lobules, short neck with loose skin. ECHO cardiography detected atrial septal defect (cardiovascular abnormalities are present in 50% of patients). The scrotum was hypoplastic, however the testes could be detected by ultrasound in the deep inguinal ring and were normal in size. The patient also suffers from mild hypotonia, but he could walk supported. However some characteristic features reported in OTCS are missing in our patient like nasal bridge hypoplasia, hypertrophied alveolar ridges, large gingivo – labial frenula, nasal bridge hypoplasia, skeletal defects, other visceral anomalies as well as the striking softness of the ears [11–14].



**Figure 3** Demonstrates hypoplastic scotum with bilateral undescended testes.

Also the mentality was mildly affected in our patient. In OTCS intellectual deficit is usually severe [14], however few patients have also been described with mild or even a normal IQ [15].

The facial features of patients with isolated trigonocephaly may be somewhat disturbid with a triangular shaped forehead and a visible palpable midline ridge with hypotelorism inducing ethmoid hypoplasia [1]. However in other patients isolated trigonocephaly is not generally associated with a particular phenotype. It is commonly observed as a nonspecific, often transient finding of no diagnostic significance [16].

In our patient MRI of the brain demonstrated DWV anomaly. Zampino also reported a child with the typical features of OTCS with severe mental retardation who had DWM, complete callosal agenesis and occipital meningocele [11].

Our patient had isolated DWV which is considered a mild form of DWM complex [7] and may partly explain the mild mental retardation in our patient. Zampino also hypothesized that the basic developmental defect in this syndrome primarily affects the midline field which is supported by the conotruncal heart defects, omphalocele and genital anomalies in his patient [11].

Isolated trigonocephaly may be associated with congenital malformations like broad thumbs [17] and congenital orbital teratoma [18]. However DWM or DWV had not been reported with it.

Extracranial anomalies associated with DWV were reported to be 54% compared with 12–86% reported in patients with DWM. These malformations included cardiovascular, neurological, gastro-intestinal, genitourinary, craniofacial, respiratory system, and orthopedic anomalies. DWV was also associated with syndromes in 12% of cases like Pierre Robin sequence, Smith – Lemli – Opitz syndrome, Senior – Loken

Syndrome, Menkes syndrome, Coffin – Siris Syndrome, Ehlers – Danlos syndrome as well as neurocutaneous melanosis. Chromosomal abnormalities were also reported with DWV in 16.7% and included trisomy 9, 11, 13 and mosaicism 8 [5]. Chromosomal analysis in our patient detected a normal karyotype.

OTCS is a malformation syndrome of unknown cause [10]. Some cases with a phenotype similar to OTCS are associated with chromosomal abnormalities. These abnormalities included trisomy and tetrasomy 13 [19], partial trisomy 13 [20], terminal deletion of 2p and partial duplication 17 [21], trisomy of 3p ter [22], and 9q 34.3 deletion [23]. The TACTILE gene of the CD 96, a member of the immunoglobulin superfamily was found to be mutated in some OTCS patients thus interfering with cell adhesion and growth [10]. In autopsied cases there has been a suggestion of defective central nervous system myelination. About half of the cases died within the first year [14].

Isolated trigonocephaly has been associated with fibroblast growth factor receptor 1 (FGFR1) mutation [24] and in syndromic cases chromosomal aberrations in particular 7p deletion and monosomy 11q ter [25] and microdeletions of 9p22-p24 or 11q23-24 have been identified [26].

In our patient, there was no consanguinity or family history of a similar condition, and no history of drug intake by the mother. This means that our patient is most probably a sporadic case.

Although most of the reported OTCS patients are sporadic, rare cases of familial occurrence have been described. Reports of recurrence in sibs with unaffected parents suggest that familial cases may be caused by germinal mosaicism [12,15,27]. In other reports its mode of inheritance has been suggested to be autosomal recessive [9]. Autosomal dominant inheritance was also suggested as CD 96 aberrations found in two patients were both in the heterozygous state without a copy – number variation in this region, which is consistent with autosomal dominant inheritance [10]. These findings imply that the OTCS is genetically heterogenous and its mode of inheritance is still debate.

To conclude our patient most probably has a mild form of OTCS. This expands the mental affection in OTCS from severe to mild mental retardation. Every patient with trigonocephaly should be fully investigated to identify other congenital anomalies He needs close follow up because over time with trigonocephaly, there may be developmental delays, mental retardation, seizures and other indications of neurological disorder due to cramped space [28]. Even in patients with mild trigonocephaly the intracranial pressure and pulse pressure may be high and decompressive craniotomy is feasible [29]. Our patients also have DWV which needs close follow up to determine the need for CSF diversion [5].

#### 4. Recommendations

We recommend cytogenetic investigations, and mutation analysis of suspected genes in all patients with OTCS for providing accurate genetic counseling and prenatal diagnosis.

#### Conflict of interest

The Author declare that there is no conflict of interest.

## References

- [1] <<http://www.carrot.dreab.com/p-trigonocephaly>> .
- [2] Alderman BW, Fernbach SK, Greene C, Mangione EJ, Ferguson SW. Diagnostic practice and the estimated prevalence of craniosynostosis in Colorado. *Arch Pediatr Adolesc Med* 1997;151(2): 159–64.
- [3] Lajeunie E, Le Merrer M, Marchac D, Renier D. Syndromal and nonsyndromal primary trigonocephaly: analysis of a series of 237 patients. *Am J Med Genet* 1998;75(2):211–5, 13.
- [4] Altman NR, Naidich TP, Braffman BH. Posterior fossa malformations. *AJNR Am J Neuroradiol* 1992;13:691–724.
- [5] Sasaki D-A, Elbabaa KS, Jewells V, Carter RNR, Campbell WJ, Riter MA. The Dandy-Walker variant: a case series of 24 pediatric patients and evaluation of associated anomalies, incidence of hydrocephalus, and developmental outcomes. *J Neurosurg Pediatrics* 2008;2:194–9.
- [6] Hart MN, Malamund N, Ellis. The Dandy Walker syndrome. A clinicopathological study based on 28 cases. *Neurology* 1972;22(8):771–80.
- [7] Incesu L, Smirniotopoulos JG, et al. Imaging in Dandy-Walker Malformation. *Medscap, Drugs, Diseases & Procedures*, Updated May 25, 2011 <<http://emedicine.medscape.com/article/408059-overview>> .
- [8] Opitz JM, Johnson RC, Mc Creadie SR, Smith DW. The C syndrome of multiple congenital anomalies. *Birth Defects* 1969;5:161–6.
- [9] Gorlin RJ, Cohen Jr MM, Hennekam RCM. *Syndromes of the Head and Neck*. 4th ed. New York: Oxford University Press; 2001.
- [10] Kaname T, Yanagi K, Chinen Y, Makito Y, Okamoto N, et al. Mutations in CD 96, a member of the immunoglobulin superfamily cause a form of the C Opitz Trigonocephaly syndrome. *Am J Hum Genet* 2007;81(4):835–41.
- [11] Zampino G, Di Rocco C, Butera G, Balducci F, Colosimo C, Torrioli MG, Mastroiacovo P. Opitz C trigonocephaly syndrome and midline brain anomalies. *Am J Med Genet* 1997;73(4):484–8, 31.
- [12] Sargent C, Burn J, Baraitser M, Pembrey ME. Trigonocephaly and the Opitz C syndrome. *J Med Genet* 1985;22:39–45.
- [13] Addor MC, Stefanutti D, Farron F, Meinecke P, Lacombe D, Sarlangue J, Prescia G, Schorderet DF. “C” trigonocephaly syndrome with diaphragmatic hernia. *Genet Couns* 1995;6(2): 113–20.
- [14] Antley RM, Hwang DS, Theopold W, Gorlin RJ, Steeper T, Pitt D, Danks DM, McPherson E, Bartels H, Wiedemann HR, Opitz JM. Further delineation of the C (trigonocephaly) syndrome. *Am J Med Genet* 1981;9(2):147–63.
- [15] Orphanet: C syndrome Opitz trigonocephaly. Orphaned version 4.6.3- last updated: 2011- 10-16. <[http://www.orpha.net/consor/cgi-bin/Disease\\_Search](http://www.orpha.net/consor/cgi-bin/Disease_Search)> .
- [16] Foley P, McAuliffe F, Mullarkey M, Reardon W. Antenatal diagnosis of deletion chromosome 11(q23-qter) (Jacobsen syndrome). *Clin Dysmorphol* 2007;16:177–9.
- [17] Orphanet. Trigonocephaly – brood thumbs. January, 2007. Orphaned version 4.6.3- last updated: 2011-10-14. <[http://www.orpha.net/consor/cgi-bin/Disease\\_Search](http://www.orpha.net/consor/cgi-bin/Disease_Search)> .
- [18] Sadover AM, Kalsbeck JE, Ellis FD, Eppley, Elluru R. *Plastic Reconstruct Sur* 1991;88(6):1059–63.
- [19] Chu TW, Teebi AS, Gibson L, Breg WR, Yang – Feng TL. FISH diagnosis of partial trisomy 13 and tetrasomy 13 in a patient with severe trigonocephaly (C) phenotype. *Am J Med Genet* 1994;52: 92–6.
- [20] Phadke SR, Patil SJ. Partial Trisomy 13 with Features Similar to ‘C’ Syndrome: *Indian Pediatrics* 2004;41:614–7.
- [21] Czako M, Riegel M, Morava E, Bajnóczky K, Kosztolányi G. Opitz “C” trigonocephaly-like syndrome in a patient with terminal deletion of 2p and partial duplication of 17q. *Am J Med Genet* 2004;Part A, 131A(3):310–2.
- [22] McGaughran J, Aftimos S, Oei P. Trisomy of 3pter in a patient with apparent C (trigonocephaly) syndrome. *Am J Med Genet* 2000;94(4):311–5, 2.
- [23] Yatsenko S, Cheung S, Scott D, Nowaczyk M, Tarnopolsky M, Naidu S, Bibat G, Patel A, Leroy J, Scaglia F, Stankiewicz P, Lupski J. Deletion 9q34.3 syndrome: genotype-phenotype correlations and an extended deletion in a patient with features of Opitz C trigonocephaly. *J Med Genet* 2005;42(4):328–35.
- [24] Kress W, Petersen B, Collman H, Grimm T. An unusual FGFR1 mutation (fibroblast growth factor receptor 1 mutation) in a girl with non-syndromic trigonocephaly”. *Cytogenet Cell Genet* 2000;91:138–40.
- [25] Lajeunie E, Merrer M, Marchae D, Renier R. Syndromial and no syndromal primary trigonocephaly: analysis of a series of 237 patients. *Am J Med Genet* 1998;75:211–5.
- [26] Jehee FS, Johnson D, Alonso LG, Cavalcanti DP, de Sá Moreira E, Alberto FL, Kok F, Kim C, Wall SA, Jabs EW, Boyadjev SA, Wilkie AO, Passos-Bueno MR. Molecular screening for microdeletions at 9p22-p24 and 11q23-q24 in a large cohort of patients with trigonocephaly. *Clin Genet* 2005;67(6):503–10.
- [27] Opitz JM, Putnam AR, Comstock JM, Chin S, Byrne JL, Kennedy A, Frikke MJ, Bernard C, Albrecht S, Der Kaloustian V, Szakacs JG. Mortality and pathological findings in C (Opitz trigonocephaly) syndrome. *Fetal Pediatr Pathol* 2006;25(4): 211–31.
- [28] Melissa, June 30, 2011. Trigonocephaly Birth Defects. Neural tube defects. <<http://neuraltubedefect.com/trigonocephaly/>> .
- [29] Shimoji T, Tomiyama N. Mild trigonocephaly and intracranial pressure: report of 56 cases. *Child Nervous Sys* 2004;20(10): 749–56.