




Ain Shams University
The Egyptian Journal of Medical Human Genetics

www.ejmhg.eg.net
www.sciencedirect.com



ORIGINAL ARTICLE

Low bone density management via capacitively coupled electrical fields and low intensity pulsed ultrasound in hemiparetic cerebral palsy

Khaled A. Olama *

*Department of Physical Therapy for Disturbance of Growth and Development in Children and its Surgery,
Faculty of Physical Therapy, Cairo University, El-Rehab City, Group 95, Building 12, New Heliopolis, Helwan, Egypt*

Received 29 December 2010; accepted 4 April 2011
Available online 1 November 2011

KEYWORDS

Cerebral palsy;
Hemi-paresis;
Osteoporosis;
Capacitively coupled electrical fields;
Low intensity pulsed ultrasound

Abstract Osteoporosis is being increasingly recognized in pediatric practice as a consequence of several factors. These include the increasing complexity of chronic conditions and the associated treatments managed by pediatricians. In addition, the improved care provided to children with chronic illness has led to many of them living long enough to develop osteoporosis. Many children with cerebral palsy have diminished bone mineral density and the application of capacitively coupled electrical fields and low intensity pulsed ultrasound aim to improve the formation of bone cells and so may be helpful in the management of such cases. In this study, capacitively coupled electrical fields and low intensity pulsed ultrasound was conducted to investigate its effect on bone mineral density in spastic diaplegic cerebral palsy. Twenty spastic hemiparetic children were the sample of this work. There were divided randomly into two equal groups. Bone mineral densities were measured before and after six months of the application of the treatment program. Group A (control) received the physiotherapy program, while group B (study) received capacitively coupled electrical fields and low intensity pulsed ultrasound in addition to the same treatment program given to group A. Significant improvement were observed in all measuring variables when comparing the post-treatment results in both groups in favor of group B.

* Corresponding author. Tel.: +20 226710780/1103442838.
E-mail address: K_olama@hotmail.com



Conclusion: Capacitively coupled electrical fields and low intensity pulsed ultrasound therapy may be considered as one of the most helpful methods of physiotherapy in management of low bone density in spastic hemiparetic cerebral palsied children.

© 2011 Ain Shams University. Production and hosting by Elsevier B.V. All rights reserved.

1. Introduction

Cerebral palsy is not a disease but a broad term used to cover many disorders caused by damage to the brain that can take place before, during, or in the early days after birth [1]. Hemiparetic cerebral palsy is being one of the common types of cerebral palsy; it represents about forty percent of all cerebral palsied children. It can be defined as paresis involvement of one side of the body including limbs, trunk and possibly the neck [2]. Osteoporosis is defined by the World Health Organization as a systemic skeletal disorder characterized by low bone mass and micro-architectural deterioration of bone tissue with a consequent increase in bone fragility and susceptibility to fracture [3]. There are many childhood conditions in which low bone mineral density (BMD) has been demonstrated often in studies using dual energy X-ray absorptiometry (DXA). However, in many of these conditions, there is an increased fracture risk and therefore it is appropriate to label them as causing osteoporosis [4]. Low BMD is prevalent in children with moderate to severe cases of cerebral palsy and is associated with significant fracture risk. The underlying pathophysiology is complex, with multiple factors contributing to the problem and significant variation between different regions of the skeleton [5]. Skeletal healing requires the spatial and temporal orchestration of numerous cell types, growth factors and genes working in unison towards restoring bone's structural integrity and function. Much thought has been devoted to accelerating or augmenting these reparative processes. Biophysical stimulation has been investigated experimentally and clinically as an orthopedic intervention for several decades and positive results have been reported for fracture healing, [6,7] delayed unions and non-unions, [8,9] and biomaterial osteointegration [10]. These interventions include pulsed electromagnetic fields (PEMF), [11] low intensity pulsed ultrasound (LIPUS), [6] high frequency, low magnitude mechanical stimuli, [12,13] and direct electric current [8]. The scientific underpinning for these biophysical approaches is that they serve as exogenous surrogates for the regulatory signals normally arising through skeletal loading which are absent because of sustained trauma [14]. The treatment of low bone density with various forms of electricity has been studied with intense interest during the last decade and a half. Constant direct, pulsed direct current and electromagnetic stimulation (inductive coupling) have all been reported to result in improving in the majority of established low BMD, with success rates comparable with those achieved by bone-grafting. The semi invasive method of applying either constant or pulsed direct current to a low BMD employs completely portable equipment and avoids an open operative procedure, but does not allow exhaustion during use on the lower extremity [15]. Low intensity pulsed ultrasound (LIPUS) is a medical technology, generally utilizing 1.5 MHz frequency pulses, with a pulse width of 200 μ s, repeated at 1 kHz, at an intensity of 30 mW/cm², 20 minutes/day [16]. Therefore, the goal of this study was to

examine the potential of daily capacitively coupled electrical fields (CCEF) and low intensity pulsed ultrasound (LIPUS) stimulation on low BMD in hemiparetic cerebral palsied children.

2. Patients, instrumentation and procedures

2.1. Patients

Twenty hemiparetic cerebral palsied children (11 left and 9 right sides) represented the sample of this study. They were chosen from both sexes (12 males and 8 females), from El-Nabawy El-Mohandas Institute of Poliomyelitis and Physical Medicine at the area of Imbaba, Giza, Egypt. Their ages ranged from 4 to 6 years ($X:4.75 \pm 1.25$ Yr.). They were able to understand any command given to them, with an IQ level within normal range. Children participated in the study were free from any associated disorders other than spasticity. The degree of spasticity was determined according to the modified Ashworth's scale [17] to be within the range of 1⁺ and 2 grades. They were free from any structural changes in the joints of the lower limbs; however there were few degrees of soft tissue tightness. They were able to walk independently with an abnormal gait pattern. The study sample was divided randomly into two groups of equal number (A and B). Double blind evaluation was conducted for each child individually before and after six months of treatment. Group A (control) received a designed exercise therapy program while group B (study) received daily capacitively coupled electrical fields (CCEF) and low intensity pulsed ultrasound (LIPUS) on the region of femoral head of the paralytic side, in addition to the exercise therapy program given to group A.

2.2. Instrumentation

2.2.1. For evaluation

Dual Energy X-ray Absorptiometry (DXA) for bone density assessment which includes large machine (central devices) that consists of padded platform and a mechanical arm like devise (scanner) that emit low dose X-ray on the area of measurement. The equipment combined with computer in which its software is able to determine bone mineral density. Dual Energy X-ray Absorptiometry (DXA) is the standard of measuring bone mineral content using very low dose of radiation while producing bone mineral density using bone mineral content (gm) by the area of bone measured (cm²) [18].

2.2.2. For treatment

- A. Tumble forms (mat, wedges, rollers and balls) from Preston, for the application of the exercise program.
- B. The OSTEOTRON II is a non-invasive bone growth stimulator of capacitively coupled electric field (CCEF).

The principle behind the CCEF method was developed by many researchers in 1981. The 60 kHz alternating current, which is minimally influenced by impedance and has no harmful side effects, stimulates the bone formation [19].

- C. The OSTEOTRON III is a Very Low Intensity Pulsed Ultra Sound (LIPUS); non-invasive (LIPUS); two channels; can be used in a digital display of cumulative hours of treatment; a single probe capable of both 1 MHz or 3 MHz output is used according to treatment objectives and areas: 1 MHz for a deep area and 3 MHz for superficial area. The probe BNR (beam non-uniformity ratio), a key factor in the efficacy and safety of ultrasound therapy, is 3.1–3.5 (IEC) [20].

2.3. Procedures

2.3.1. For evaluation

Dual Energy X-ray Absorptiometry (DXA) technique was used to measure bone mineral density of the femoral neck point using bone mineral content in gram (gm) by measured area (cm²). During this test, each child of the two groups was allowed to lie on a padded platform for a few minutes while an imager (a mechanical arm-like device) passes over the child without touching him/her, it emit radiation through the exposed part of the child body (the proximal femur). The equipment converted the information received by the detector in the mechanical arm like device into an image of the hip. The results were reported as a total amount of bone per unit of the skeleton area [21].

2.3.2. For treatment

Group A (control) received a designed exercise program which was conducted daily for six successive months, including: Neurodevelopmental technique, proprioceptive training, facilitation of righting and equilibrium reactions, faradic stimulation on the antispastic muscles of the hemiparetic side, stretching exercise for the muscles liable to be tight, strengthening exercises for the antispastic muscles, and gait training in closed and open environment. Special attention was also given to the unaffected side and to the trunk. In addition to the designed physical therapy program given to the control group, the group B (study) received the application of capacitively coupled electric field (CCEF) and very low intensity pulsed ultra sound (LIPUS) each for one hour per day while the child on standing frame. The surface adhesive electrodes of the two channels of CCEF and also the head of LIPUS were placed on the area of the femoral head of the affected side.

3. Results

The raw data of bone mineral density (BMD) at the femoral neck point of the affected lower limb in spastic hemiplegic cerebral palsied children were statistically treated to determine the mean and standard deviation of the measuring variable, for the two groups before and after six months of treatment. Student *t*-test was then applied to examine the significance of treatment procedures conducted in each group. The obtained results in this study revealed no significant differences when

comparing the pre-treatment mean values of the two groups. Significant improvement was observed in the measuring variable of the two groups (A and B), when comparing their pre and post-treatment mean values. However, high significant improvement was observed in group B, when comparing its post-treatment mean values with the post-treatment mean values of group A.

As revealed from Table 1 and Fig. 1, significant improvement was observed in the mean value of BMD in the control group (A) at the end of treatment as compared with the corresponding mean value before treatment (*P* < 0.01), with a percentage of improvement of 14.15%.

Also, Table 1 and Fig. 1, showed a significant improvement in the mean value of BMD in the study group (B) at the end of treatment as compared with the corresponding mean value before treatment (*P* < 0.001), the percentage of improvement was 26.24%.

Significant improvement was also observed when comparing the post-treatment mean values of BMD of the two groups in favor of group B (*p* < 0.05).

4. Discussion

The present study was conducted on twenty spastic hemiparetic cerebral palsy children to evaluate the effect of capacitively coupled electric field (CCEF) and very low intensity pulsed ultra sound (LIPUS) on the improvement of BMD at the femoral head region of the affected part. Dual Energy X-ray Absorptiometry (DXA) before and after six months of treatment which gives indication about the bone mineral content (gm) per the area (cm²) of the examined bone. Dual Energy X-ray Absorptiometry (DXA) is characterized by fast scan time, low radiation dose and excellent precision and accuracy.

Table 1 Pre and post-treatment mean values of BMD (g/cm²) for groups A and B.

	Group A (control)		Group B (study)	
	Pre	Post	Pre	Post
X [*]	0.2996	0.3343	0.2967	0.3901
± SD	± 0.0422	± 0.039	± 0.0375	± 0.0262
<i>t</i> -test	4.05		10.34	
<i>P</i> -value	0 < 0.01		< 0.001	
Sig.	Significant		Highly significant	

X^{*}: mean; SD: standard deviation; *P*-value: level of significance; Sig.: significance.

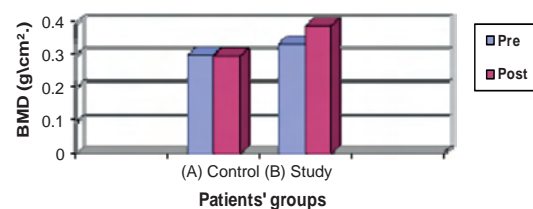


Figure 1 Illustrating the pre and post-treatment mean values of BMD (g/cm²) for groups A (control) and B (study).

Thus, DXA was the method for measuring BMD in this work. Dual Energy X-ray Absorptiometry is becoming more widely available as a mean of accurately measuring BMD. It has high precision and accuracy of the measurements, less expensive, painless, produces less radiation, and very sensitive to minimal changes of BMD [22]. Children with cerebral palsy develop over the course of their life's clinically significant osteopenia, unlike elderly and adults; this is not primarily from true losses in bone minerals that is diminished relative to healthy children [23]. Long bones are the most common sites developing low BMD and the proximal femur showed lower BMD compared to the spine [24]. Capacitively coupled electric field (CCEF) and very low intensity pulsed ultra sound (LIPUS) provide an effective alternative for the treatment of different musculo-skeletal disorders as osteonecrosis, osteoporosis, delayed unions and nonunion fractures [25]. The pre-treatment mean values of the BMD at femoral neck of the affected side in both control and study groups showed non-significant statistically difference in the measured value. This finding clearly demonstrates the homogeneity between the two groups before starting the study reflecting the validity of the sample collection and random classification of children between the two groups. The improvement in the BMD in control group can be attributed to the effect of the designed physical therapy program on bone. The improvement can be regarded as a result of mechanical loading, which can reduce bone demineralization which occurs with disuse. The results among the study group revealed that the mean values of the BMD at the femoral neck of the affected side before and after application of the suggested treatment program (CCEF and LIPUS) were statistically improved. The effect of CCEF and LIPUS on improving osteoporosis is attributed to enhancement to bone tissue formation [26].

5. Conclusion

On the bases of the present data, it is possible to conclude that the combined application of the capacitively coupled electric field (CCEF) and very low intensity pulsed ultra sound (LIPUS) is an effective therapeutic modality for improving BMD at the femoral head region of the affected part in hemiparetic cerebral palsy.

References

- [1] Bernstein S. Equines deformity in cerebral palsy. *J Bone Joint Surg. Br.* 2006;104:221–9.
- [2] Bedford A, McKinlary S. Disorders of the central nervous system. In: Eckersley PM, editor. *Element of pediatric physiotherapy*. Churchill living stone; London; 2007; pp: 115–153.
- [3] Assessment of fracture risk and its application to screening for postmenopausal osteoporosis: report of a WHO study group. WHO Technical Report Series 843, WHO, Geneva 1994.
- [4] Goulding A, Cannan R, Williams SM, Gold EJ, Taylor RW, Lewis-Barned NJ. Bone mineral density in girls with forearm fractures. *J Bone Mineral Res* 1998;13:143–8.
- [5] Henderson R, Gilbrt S, Clement M. Altered skeletal maturation in moderate to severe cerebral palsy. *Dev Med Child Neurol* 2002;47:229–36.
- [6] Heckman JD, Ryaby JP, Mc Cabe J, Frey JJ, Kilcoyne RF. Acceleration of tibial fracture-healing by non-invasive, low-intensity pulsed ultrasound. *J Bone Joint Surg Am* 1994;76(1):26–34.
- [7] Leung KS, Lee WS, Tsui HF, Liu PP, Cheung WH. Complex tibial fracture outcomes following treatment with low-intensity pulsed ultrasound. *Ultrasound Med Biol* 2004;30(3):389–95.
- [8] Friedenbergs ZB, Harlow MC, Brighton CT. Healing of nonunion of the medial malleolus by means of direct current: a case report. *J Trauma* 1971;11(10):883–5.
- [9] Frykman GK, Taleisnik J, Peters G, Kaufman R, Helal B, Wood VE, Unsell RS. Treatment of nonunited scaphoid fractures by pulsed electromagnetic field and cast. *J Hand Surg Am* 1986;11(3):344–9.
- [10] Fini M, Giavaresi G, Setti S, Martini L, Torricelli P, Giardino R. Current trends in the enhancement of biomaterial osteointegration: biophysical stimulation. *Int J Artif Organs* 2004;27(8):681–90.
- [11] Anglen J. The clinical use of bone stimulators. *J South Orthop Assoc* 2003;12(2):46–54.
- [12] Rubin C, Pope M, Fritton JC, Magnusson M, Hansson T, McLeod K. Department of Biomedical Engineering SUN-YBSB NYUSA: Transmissibility of 15-hertz to 35-hertz vibrations to the human hip and lumbar spine: determining the physiologic feasibility of delivering low-level anabolic mechanical stimuli to skeletal regions at greatest risk of fracture because of osteoporosis. *Spine* 2003;28(23):2621–7.
- [13] Azuma Y, Ito M, Harada Y, Takagi H, Ohta T, Jingushi S. Low-intensity pulsed ultrasound accelerates rat femoral fracture healing by acting on the various cellular reactions in the fracture callus. *J Bone Miner Res* 2001;16(4):671–80.
- [14] Hantes ME, Mavrodontidis AN, Zalavras CG, Karantanas AH, Karachalios T, Malizos KN. Low-intensity transosseous ultrasound accelerates osteotomy healing in a sheep fracture model. *J Bone Joint Surg Am* 2004;86-A(10):2275–82.
- [15] Wheeler DL, Enneking WF. Allograft bone decreases in strength in vivo over time. *Clin Orthop* 2005;435:36–42.
- [16] Raman Mundi, Stephen Petis, Roopinder Kaloty, Vijay Shetty, Mohit Bhandari. Low-intensity pulsed ultrasound in fracture healing. *Indian J Orthopedic* 2009;43(2):132–40.
- [17] Bohannon RW, Smith MB. Inter-Reliability of modified Ashworth scale of muscle spasticity 1987; 67(2): 206–208.
- [18] Rauch F. Bone accrual in children adding substance to surfaces. *Pediatrics* 2007;119:S137–40.
- [19] Binkley T, Johnson J, Vogel L, Keckemethy H, Henderson R, Specker B. Bone measurements by peripheral quantitative computed tomography (pQCT) in children with cerebral palsy. *J Pediatr* 2005;147:791–6.
- [20] Stevenson RD, Conaway M, Barrington JW, Cuthill SL, Worley G, Henderson RC. Fracture rate in children with cerebral palsy. *Pediatr Rehabil* 2006;9:396–403.
- [21] Larson CM, Henderson RC. Bone mineral density and fractures in boys with Duchenne muscular dystrophy. *J Pediatric Orthoped* 2000.
- [22] Barachrach K. Measuring bone mass in children: can we really do it? *Home Res* 2006;69(2):11–6.
- [23] Henderson R, Kairolla J, Abbas A. Predicting low bone density in children and young adults with quadriplegic cerebral palsy. *Dev Med Child Neurol* 2004;46(6):416–9.
- [24] Larson C, Henderson R. Bone mineral density and fractures in boys with Duchene muscular dystrophy. *J Ped Orthop* 2002;71–4.
- [25] Fitzsimmons R, Baylink J. Growth factors and Electromagnetic field in bones. *Clinic. Plast Surg Calcif Tissue Int* 2005;21(3):401–6.
- [26] Tokoyama K, Nomura H, Tanaka J. Effect of PEMFs on metabolically derived osteoporosis in rats. *Asaio Trans* Jul 2000;36(3):426–8.