

## Corpus callosum defect with dilated lateral ventricles and an occipital cyst in an Egyptian child with Diamond-Blackfan anemia

Rabah M. Shawky<sup>1</sup> and Nermine S. El-Sayed<sup>2</sup>

<sup>1</sup>Pediatric Department, <sup>2</sup>Medical Genetics Center, Ain Shams University

### ABSTRACT

Diamond-Blackfan anemia (DBA), an inherited bone marrow failure syndrome characterized by anemia that usually presents before the first birthday or in early childhood, is associated with birth defects and an increased risk of cancer. Although anemia is the most prominent feature of DBA, the disease is also characterized by growth retardation and congenital malformations, in particular craniofacial, upper limb, heart, and urinary system defects that are present in approximately 30%-50% of patients. Herein, we present a patient with Diamond-Blackfan anemia associated craniofacial anomalies, pyramidal manifestations and corpus callosum defect and dilated lateral ventricles opening with each other and opening with a posterior occipital cyst, an association that to date has not been reported.

#### Key Words:

Diamond-Blackfan anemia, corpus callosum, dilated ventricles, occipital cyst.

#### Corresponding Author:

Prof. Rabah M. Shawky

E-mail: shawkyrabah@yahoo.com

### INTRODUCTION

Diamond-Blackfan anaemia (DBA, OMIM #205900) was first reported by Josephs, 1936<sup>1</sup> and refined as a distinct clinical entity by Diamond and Blackfan, 1938<sup>2</sup>. It is now accepted that the disorder results from a cellular defect in which erythroid progenitors and precursors are highly sensitive to death by apoptosis, leading to erythropoietic failure. DBA is a member of a rare group of genetic disorders characterized by proapoptotic hematopoiesis leading to bone marrow failure, congenital anomalies and predisposition to cancer, known as the inherited bone marrow failure syndromes (IBMFS)<sup>3</sup>.

The first DBA gene, mutated in approximately 25% of patients, has been cloned and was identified as RPS19, which codes for a ribosomal protein located at chromosome 19q13.2. This protein plays a role in ribosome biogenesis. In patients with an RPS19 mutation, it has been proposed that the disease results from rps19 protein haploinsufficiency, i.e. where the protein produced by a single copy of a normal gene is not sufficient to produce normal function. Recently de novo mutations have been identified in ribosomal proteins rps24, encoded by RPS24 at chromosome 10q22-q23 and in rps 17, encoded by RPS17 at chromo-

some 15q25.2. Furthermore mutations in large ribosomal subunit-associated proteins rpl5, rpl11 and rpl35a have been described<sup>4-6</sup>.

The majority of cases are sporadic, with an equal sex ratio, but at least 10% have a positive family history for the disorder. Both autosomal dominant and autosomal recessive inheritance have been reported. In addition, studies of several families indicate dominant inheritance with reduced penetrance<sup>7</sup>.

A subset of patients has associated phenotypic abnormalities including thumb malformations, urogenital abnormalities, atrial or ventricular septal defects, short stature, learning difficulties, strabismus and cataract<sup>6</sup>.

## CASE REPORT

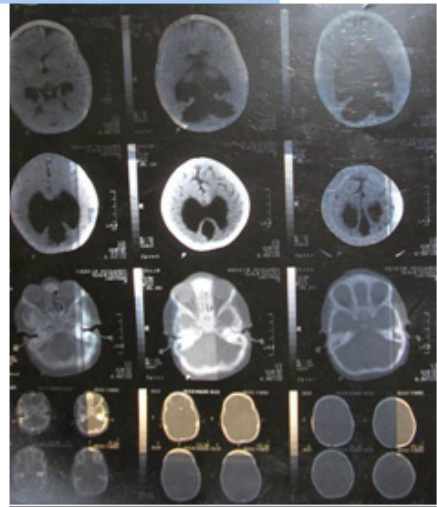
A 3.5 years old female patient was born at term after an uneventful pregnancy to unrelated parents. The parents and the older brother were all healthy; however, the paternal aunt and the paternal aunt of the mother had leukemia and died at the age of 25y and 32y respectively. At the age of 2 months, the proband developed pallor and fever (39°C) and she received her first blood transfusion, later she became transfusion dependent every 15 days.

On examination, she had anemia, with no palpable liver and spleen. Her length was 84cm, weight was 10kg and head circumference was 47cm (all below the third percentile). Craniofacial examination revealed prominent forehead, upward slant of lateral palpebral fissures, low set ear, prominent upper jaw, high arched palate and thick everted lower lip. Skeletal examination revealed limited extension of elbows and knees and

dorsiflexion of big toes. Neurologic examination showed mental impairment, hypertonia and exaggerated deep reflexes and +ve babiniski sign. Other systems were normal.

Laboratory investigations revealed a hemoglobin concentration of 4g/dl. reticulocytopenia, leukocyte and thrombocyte counts were normal. A bone marrow aspirate showed a selective decrease in erythroid precursors and reduced erythropoiesis confirming the diagnosis of congenital pure red cell aplasia.

CT brain detected associated malformations in the form of corpus callosum defect with dilated lateral ventricles opening with each other and opening with a posterior occipital cyst as well (Fig. 1). Electroencephalography, echocardiography and abdominal U/S and chromosomal analysis (G-banding) were normal.



**Fig. 1:** CT brain shows a corpus callosum defect with dilated lateral ventricles opening with each other and opening with a posterior occipital cyst as well.

**DISCUSSION**

---

Diamond Blackfan anemia was first described as a disorder of impaired red cell production in children. The presentation in adults, the risk of other cytopenias, the predisposition to cancer and the high incidence of birth defects are now being quantified<sup>8</sup>.

The diagnostic criteria for DBA, presented in 1976<sup>9</sup>, have remained the accepted standard. These include anemia, presenting prior to the first birthday, with near normal, variable, neutrophil and/or platelet counts, reticulocytopenia, macrocytosis and normal marrow cellularity with a paucity of red cell precursors. Our patient manifestations were compatible with the diagnosis of DBA.

Certainly these diagnostic criteria define "classic" DBA. It is apparent from the study of multiplex families that affected individuals may present in "non-classical" ways. For example, individuals may present at an age greater than one year, only with congenital anomalies, without anemia or with a mild hematological phenotype (macrocytosis only). These cases of "non-classical" DBA need to be more carefully identified, particularly when reproductive choices and transplant donor decisions are being made<sup>5</sup>.

Until recently, information with regard to the cancer risk in patients with DBA has been limited primarily to case reports: 29 cases were reported among more than 700 patients in the literature<sup>10, 11</sup>. The reported proportion of 4% is higher than the expected <1% for a cohort less than 30 years of age. The median age for cancer in these reports was 15 years, much younger than the median of 68 years in the general population. While the published data are insufficient to define the risk of cancer in DBA, the types of malignancy reported are informative. The literature includes 11 cases of acute leukemia (10 acute myeloid leukemia [AML] and one acute lymphoblastic leukemia), three cases of myelodysplastic syndrome that did not develop AML, six cases of sarcoma (five osteogenic, one soft tissue), three Hodgkin lymphoma, two breast cancer, two hepatocellular carcinoma and one each of melanoma, fibrohistiocytoma, non-Hodgkin lymphoma, gastric cancer and colon cancer<sup>5, 10-12</sup>.

Congenital anomalies observed in DBA may involve the head, upper limbs, heart and genitourinary system (Table 1). More than one anomaly is found in up to 25% of individuals. There is a wide range of severity of congenital anomalies in DBA, with variability even within the same kindred.

**Table 1:** Range of congenital anomalies observed in Diamond Blackfan anemia (DBA)\*.

<b>Craniofacial</b>	<b>Hypertelorism, broad, flat nasal bridge, cleft palate, high arched palate, microcephaly, micrognathia, microtia, low set ears, low hair line, epicanthus, ptosis.</b>
<b>Ophthalmological</b>	Congenital glaucoma, strabismus
<b>Neck</b>	Short neck, webbed neck, Sprengel deformity, Klippel-Feil deformity.
<b>Thumbs</b>	Triphalangeal, duplex or bifid, hypoplastic, flat thenar eminence, absent radial artery.
<b>Urogenital</b>	Absent kidney, horseshoe kidney, hypospadias
<b>Cardiac</b>	Ventricular septal defect, atrial septal defect, coarctation of the aorta, complex cardiac anomalies
<b>Other musculoskeletal</b>	Growth retardation, syndactyly
<b>Neuromotor</b>	Learning difficulties

\* The list includes the anomalies that are most characteristic of DBA, but is not exhaustive<sup>5</sup>.

Craniofacial anomalies are the most common, representing 50% of congenital anomalies reported to the North American DBA Registry, with hypertelorism and broad flat nasal bridge contributing to the classic DBA facies described by Cathie<sup>13</sup>. In our patient the most prominent craniofacial abnormalities included prominent forehead, upward slant of lateral palpebral fissure, high arched palate, low set ear, thick everted lower lip and prominent upper jaw. Thumb anomalies have been described in 9-19% of patients. The severity of abnormalities ranges from hypoplasia of the thenar eminence to absence of the radius or forearm, duplicated bifid or the classic triphalangeal thumb<sup>14</sup>. In our case limited extension of elbows and knees and dorsiflexion of big toes were the only upper limb abnormalities detected. Renal and cardiac anomalies have each been described in up to 7% of patients in the UK, France and Italy. However, in the North American Diamond Blackfan Anemia Registry (DBAR), where the majority of

patients undergo formal genitourinary and cardiac imaging, the prevalence is higher at 19% and 15%, respectively<sup>5</sup>. In our case no cardiac or abdominal abnormalities were detected.

Growth retardation (height below 3<sup>rd</sup> centile for age) is described in approximately 30% of children as well in our case. It must be noted that stature is difficult to evaluate in the context of severe anemia, iron overload and chronic corticosteroids use. Growth retardation is commonly associated with physical abnormalities and can thus be considered part of the spectrum of congenital anomalies<sup>15</sup>. In a study of 22 Egyptian patients with Diamond Blackfan anemia, there were associated congenital anomalies in 5 patients (22.7%) as polycystic kidney and cavernoma of the portal vein in 1 patient, hypospadias in another patient, short stature in 1 patient and microcephaly in 2 patients<sup>16</sup>. However, the link between these malformations and defective erythropoiesis is unclear and a defect in molecule acting on

both early embryonic development and hematopoiesis has been proposed<sup>17</sup>.

In our patient, associated malformations were craniofacial anomalies, pyramidal manifestations and corpus callosum defect with dilated lateral ventricles opening with each other and opening with posterior occipital cyst as well. There were no previous reports of such association. One report<sup>18</sup> described a patient who had concomitant pure red cell aplasia, thymoma, myasthenia gravis and a normal pressure hydrocephalus. However, he was 63 years old and had pure red cell aplasia most probably of immunological origin. Indeed, this case illustrates the need for heightened awareness about the existence of CNS malformations in patients with DBA and lengthens the list of associated congenital anomalies. Furthermore as the analysis of the family pedigree revealed two leukemic family members died at the age of 25y and 32y respectively and as the risk of malignancy and other complications of DBA are better defined, the proband and all immediate family members should be evaluated thorough relevant history (anemia, cancer, birth defects), physical examination with blood count monitoring, brain imaging, renal imaging and echocardiogram. Other specialist referrals should also be made as indicated.

## REFERENCES

1. Josephs HW. Anemia of infancy and early childhood. *Medicine* 1936;15:307.
2. Diamond LK and Blackfan KD. Hypoplastic anemia. *Am.J.Dis.Child.* 1938;56:464-7.
3. Young NS, Alter BP. Inherited bone marrow failure syndromes: Introduction. In: Young NS, Alter BP, editors. *Aplastic anemia acquired and inherited Philadelphia: WB Saunders Company; 1994. p. 271-4.*
4. Gregory LA, Aguisa-Touré AH, Pinaud N, Legrand P, Gleizes PE and Fribourg S. Molecular basis of Diamond-Blackfan anemia: Structure and function analysis of RPS19. *Nucleic Acids Res.* 2007;35(17):5913-21.
5. Vlachos A, Ball S, Dahl N, Alter BP, Sheth S, Ramenghi U, et al. Diagnosing and treating Diamond Blackfan anaemia: Results of an international clinical consensus conference. *Br.J.Haematol.* 2008;142(6):859-76.
6. Crétien A, Proust A, Delaunay J, Rincé P, Leblanc T, Ducrocq R, et al. Genetic variants in the noncoding region of RPS19 gene in Diamond-Blackfan anemia: Potential implications for phenotypic heterogeneity. *Am.J.Hematol.* 2010;85(2):111-6.
7. Madanat F, Arnaout M, Hasan A, Tarawneh M, Shomaf M and Khalayleh F. Red cell aplasia resembling Diamond-Blackfan anemia in seven children in a family. *Am.J.Pediatr.Hematol.Oncol.* 1994;16(3):260-5.
8. Orfali KA, Ohene-Abuakwa Y and Ball SE. Diamond Blackfan anaemia in the UK: Clinical and genetic heterogeneity. *Br.J.Haematol.* 2004;125(2):243-52.
9. Diamond LK, Wang WC and Alter BP. Congenital hypoplastic anemia. *Adv. Pediatr.* 1976;22(349):378.
10. Alter BP. Inherited bone marrow failure syndromes. In: Nathan DG, Orkin

- SH, Look AT, Ginsburg D, editors. Nathan and Oski's hematology of infancy and childhood. 6<sup>th</sup> ed. Philadelphia, PA: WB Saunders; 2003. p. 280-365.
11. Yaris N, Erduran E and Cobanoglu U. Hodgkin lymphoma in a child with Diamond Blackfan anemia. *J.Pediatr. Hematol.Oncol.* 2006;28(4):234-6.
  12. Ries LAG, Eisner MP, Kosary CL, Hankey BF, Miller BA, Clegg L, et al. SEER Cancer Statistics Review, 1973-1998. Bethesda, MD: National Cancer Institute; 2001.
  13. Cathie IA. Erythrogenesis imperfecta. *Arch.dis.child.* 1950;25(124):313-24.
  14. Lipton JM and Ellis SR. Diamond-Blackfan anemia: Diagnosis, treatment and molecular pathogenesis. *Hematol. Oncol.Clin.North Am.* 2009;23(2):261-82.
  15. Chen S, Warszawski J, Bader-Meunier B, Tchernia G, Da Costa L, Marie I, et al. Diamond-blackfan anemia and growth status: The French registry. *J.Pediatr.* 2005;147(5):669-73.
  16. El-Beshlawy A, Ibrahim IY, Rizk S and Eid K. Study of 22 Egyptian patients with Diamond-Blackfan anemia, corticosteroids and cyclosporin therapy results. *Pediatrics* 2002;110(4):e44.
  17. Manglani M, Lokeshwar MR and Sharma R. Diamond-Blackfan anemia: Report of 6 cases. *Indian Pediatr.* 2003;40(4):355-8.
  18. Akimoto Y, Ishiyama T, Ueno H, Hino K, Tomoyasu S, Tsuruoka N, et al. Pure red cell aplasia with thymoma, myasthenia gravis and normal pressure hydrocephalus. [*Rinsho ketsueki*] *Jap.j.clin.hematol.* 1994;35(8):780-5..