

## Farber disease overlapping with stiff skin syndrome: Expanding the spectrum

Ghada Y. El-Kamah<sup>1</sup>, Mohamad A. El-darouti<sup>2</sup>, Ahmad IS. Kotoury<sup>1</sup> and Mostafa I. Mostafa<sup>3</sup>

<sup>1</sup>Clinical Genetics Department, Human Genetics & Genome Research Division, National Research Centre, <sup>2</sup>Dermatology Department, Faculty of Medicine, Cairo University, <sup>3</sup>Orodonal Genetics Department, Human Genetics & Genome Research Division, National Research Centre, Cairo, Egypt.

### ABSTRACT

**Background:** Farber Disease (MIM 228000)<sup>1</sup> is a rare AR disorder first described by Sidney Farber in 1952<sup>2</sup>. Farber disease is usually recognized by the presence of three symptoms: Painful and progressively deformed joints, nodules under the skin and progressive hoarseness. Other organ systems may also be involved. As with most lysosomal storage diseases, the course of Farber's Disease is progressive and death typically occurs in infancy. Stiff skin syndrome (SSS) (MIM %184900)<sup>1</sup> was first described by Esterly and McKusick as a disorder characterized by thickened and indurated skin of the entire body and limitation of joint mobility with flexion contractures.

**Aim of the Study:** Diagnosis and clarification of overlapping in the clinical presentation of the studied case.

**Patients and Methods:** Clinical report of an atypically presenting Farber case and analyzing the overlapping manifestations between the two syndromes.

**Results:** Histopathological study was the conclusive diagnostic key in our case.

**Conclusion:** Recognition of atypical or abortive cases is of practical importance as it may affect counseling or therapeutic decision making. Orodonal manifestations were not previously considered but they may be of future diagnostic help.

#### Key Words:

Farber, stiff skin, lipogranulomatosis.

#### Corresponding Author:

Ghada El-Kamah

**E-mail:** ghadaelkamah@hotmail.com

### INTRODUCTON

**Farber disease** (FD) (also known as Disseminated Lipogranulomatosis, Ceramidase Deficiency or Farber-Uzman Syndrome)<sup>2,3</sup> describes a group of rare autosomal recessive disorders that cause an accumulation of lipids in the joints, tis-

sues and central nervous system. The disorder affects both males and females. Disease onset is typically in early infancy but may occur later in life. Massive body demineralization and articular erosion may occur and the carpus may have an appearance similar to that in juvenile rheumatoid arthritis.<sup>3,4</sup>

Progressive hoarseness and painful progressively deformed joints, are due to laryngeal involvement and subcutaneous nodules particularly over the joints. The tissues in afflicted individuals contain granulomatous and lipid-laden macrophages. The liver, spleen, lungs and heart are particularly affected with central nervous system involvement resulting in the progressive degeneration in psychomotor development. Farber lipogranulomatosis is a rapidly progressing disease often leading to death before 2 years of age. Respiratory insufficiency caused by granuloma formation in the respiratory tract and interstitial pneumonitis lead to death in the third or fourth decade of life in patients without severe manifestations.<sup>4</sup>

As a major symptom FD patients exhibit chronic destructive joint inflammation resembling rheumatoid arthritis. Indeed, increased CD95 receptor/ligand interaction has been implicated in the pathogenesis of inflammatory arthritis. It may therefore be speculated that increased CD95 signalling mediated by elevated ceramide levels is involved in the inflammatory arthritis of FD.<sup>5,6</sup>

The true incidence of Farber disease is not known. There may be several variants, ranging from mild to severe forms<sup>7</sup>. The several clinical phenotypes associated with acid ceramidase deficiencies give rise to seven subtypes of Farber lipogranulomatosis.

**Type 1** is the classic Farber disease with painful swelling of the joints, especially the ankle, wrist, elbow and knee and a hoarse cry. These symptoms are evident as early as 2 weeks of age. Evaluation of neurological involvement is difficult as movement causes extreme pain in

afflicted infants. In many cases these patients have “cherry-red spot” on the fundus of the eye.<sup>8-10</sup>

**Type 2** is the “intermediate” form and **Type 3** is the “mild” form of the disease. These patients have longer survival times than do type 1 infants. In addition the neurologic involvement is much more mild than in type 1.<sup>8-10</sup>

**Type 4** is referred to as the “neonatal-visceral” form of the disease. Infants are extremely ill in the neonatal period. These patients will present with severe hepatosplenomegaly. In the severest cases, type 4 neonates will present as hydrops fetalis and die within days of birth. Unlike type 1 patients, infants with type 4 Farber lipogranulomatosis do not present with the characteristic features of deformed painful joints, thus, requiring biochemical assay for definitive diagnosis.<sup>11</sup>

**Type 5** is referred to as “neurologic progressive”. As the name implies, the most striking clinical feature of type 5 disease is a progressive neurological deterioration accompanied by seizures. Joint involvement is evident but to a lesser degree than in type 1 disease. Type 5 patients also exhibit the “cherry-red spot” seen in many type 1 patients.<sup>12</sup>

**Type 6** is characterized by patients exhibiting both Farber lipogranulomatosis as well as Sandhoff disease.<sup>13</sup>

**Type 7** disease results from a deficiency in prosaposin which is a precursor encoding the sphingolipid activator proteins called saposins.<sup>14</sup>

Farber lipogranulomatosis results

from defects in the gene encoding the lysosomal hydrolase: Acid ceramidase ASAH located on chromosome 8p22-p21.3 and spans 30 kb encompassing 14 exons and encoding a 395 amino acid precursor protein.<sup>15</sup>

Diagnosis of FD is done by enzyme assay and/or histopathological studies demonstrating many large foam cells in the dermis by light microscopy and numerous large cells with round cytoplasmic lamellar and microtubular bodies by electron microscopy.<sup>16</sup>

There is no specific treatment for Farber's disease. Corticosteroids may be prescribed to relieve pain. Bone marrow transplants may improve granulomas on patients with little or no lung or nervous system complications.<sup>4</sup>

This study aims at diagnosis and clarification of overlapping clinical presentation in the studied case.

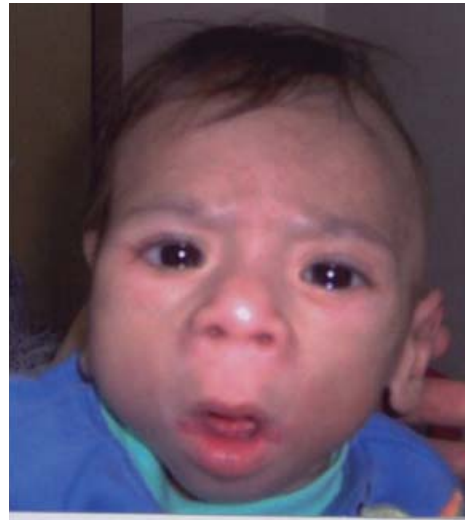### Clinical presentation

One year old male presented at the clinical Genetics Clinic, National research Centre, Cairo, with delayed milestones and flexion contractures of all his joints. He was born to first cousins 25 and 28 years old mother and father, who in turn are both a product of first degree consanguineous parents. He was born at term by caesarian section as the first child. His birth weight was 2750 grams he had contracture deformity in both knees and ankles. He was incubated for lung hypoplasia, abdominal distention and bad general condition for 17 days.

The condition started since birth by progressive joint contractures and thick indurated skin. He did not acquire any motor milestones and he suffered recur-

rent attacks of diarrhea and hypoproteinemia since birth. There is a history of a similarly affected deceased uncle of his mother.

On clinical examination he was found to be dysmorphic (Figure. 1A) with some senile facies, plageocephaly, malar hypoplasia, sloping forehead, sparse hair, eyelashes and eyebrows, epicanthic folds, concomitant squint, depressed nasal bridge, long ears with starting ulceration on the external ear.

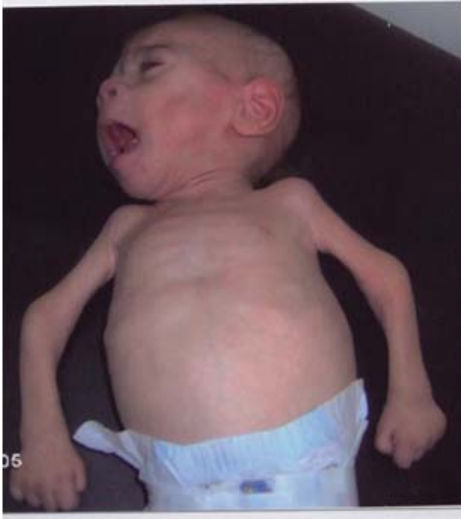

**Fig. 1A:** Dysmorphic features.

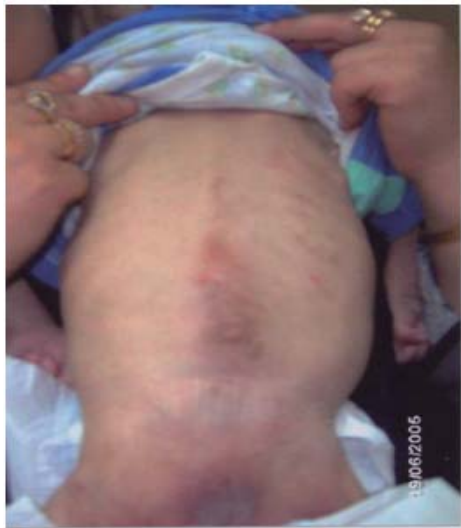Oro dental examination revealed microstomia, long philtrum, thick lips, everted lower lip, thick alveolar ridges, spooning of the tongue, high arched palate, gingival enlargement and delayed teeth eruption.

His neck was stiff, his elbows were prominent with contracture deformity and he had camptodactyly. Examination of the lower limbs also showed contracture deformity in all joints and overwriting second and fourth toes bilaterally.

The skin is tough indurated over the entire body with limitation of joint mobility and scleroderma like areas (Figures. 1-B,C). He had pectus excavatum, widespaced nipples, normal heart and chest by auscultation, rectal prolapse and normal male external genitalia. Neurological examination could not be conducted because of the tough skin and contracted joints.



**Fig. 1B:** Tough indurated skin with limitation of joint mobility.

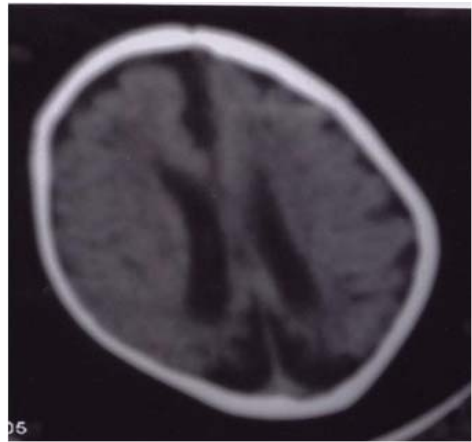


**Fig. 1C:** Scleroderma like areas.

**Laboratory investigations:** Mild hypochromic anemia with anisocytosis, leucocytosis and marked thrombocytopenia. Bleeding and clotting times were within normal. ESR and CRP were both elevated. Normal liver and kidney function tests. Normal blood ammonia level. Low serum albumin (2.8 gm/dl) and total proteins (4.7 gm/dl). Normal blood and urinary aminograms.

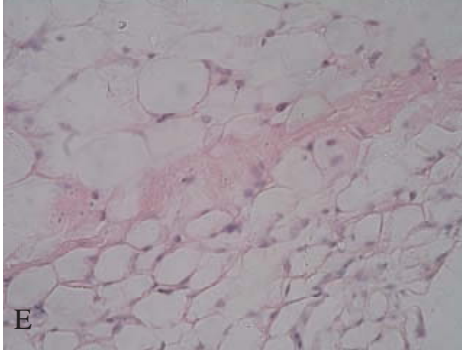
**Radiological and neurophysiological investigations:** Skeletal surveys and chest X-rays did not reveal any abnormalities or bony erosions. Abdomino pelvic ultrasonography and CT studies of the pelvis and hip and shoulder joints were all within normal.

Computed tomography brain scan (Figure. 1D) revealed bilateral posterior encephalomalacia with atrophic changes and EEG sleep record showed left fronto-central epileptiform discharges. Echocardiography revealed small patent foramen ovale hemodynamically insignificant in addition to a tiny patent ductus arteriosus. Trivial tricuspid regurge with pulmonary artery pressure 18mmHg was discovered by Doppler study.



**Fig. 1D:** CT brain showing bilateral posterior encephalomalacia with atrophic changes.

**Histopathological study of skin biopsy** by light microscopy demonstrated many large foamy histiocytes occurring within the fat lobules of the subcutaneous tissue (Figure. 1E) settling the diagnosis.



**Fig. 1E:** 400X light microscopy histopathology showing many large foam cells in the dermis.

## DISCUSSION

The presenting clinical picture in our case pointed to the diagnosis of stiff skin syndrome. The absence of clinical signs in the parents and the presence of inbreeding within the family is suggestive of autosomal recessive inheritance.

Stiff skin syndrome is a disease similar to scleroderma with unknown etiology. Stone-hard areas of skin are observed from birth or in early childhood. The stone-hard indurations of the skin and subcutaneous tissue, is predominantly on the buttocks and thighs, with slightly or not progressive course and no visceral involvement or immunologic abnormalities<sup>17-19</sup>. The progressive course of our case with some indications of inflammatory process as persistently high ESR and CRP with the generalization of stiffness was against the usual presentation of SSS.

The possibility of scleroderma as another stiff skin disorder, with thickened and indurated skin of the entire body and limitation of joint mobility with flexion contractures, was discarded because of the different distribution of the hardened spots mainly affecting wrist and ankles in case of scleroderma that, with the absence of vascular and constitutional manifestations.<sup>20</sup>

Another differential diagnosis is restrictive dermopathy, a lethal autosomal recessive congenital disorder of the skin. The rigidity of the skin impairs fetal movements in utero and causes arthrogryposis, as well as highly characteristic facial features and pulmonary hypoplasia<sup>21</sup>. Our case was delivered with stiffness, joint contractures, lung hypoplasia and severe respiratory distress. However, he did not have generalized stiffness at birth and survived till the age of a year and half.

Stevenson et al.<sup>22</sup>, described a kindred with many members with stiff skin beginning in adulthood. However, stiff skin presented in our studied case since birth.

In the few reported cases of Farber disease in the first few weeks of life manifestations consisted of irritability, hoarse cry and nodular, erythematous swellings of the wrists and other sites, particularly those subject to trauma. Severe motor and mental retardation is evident. Death occurs by 2 years of age.<sup>1</sup>

In some cases of Farber disease, neurological symptoms develop within the first few weeks of life. These symptoms may include moderately impaired mental ability and problems with swallowing.

The liver, heart and kidneys may also be affected. Other symptoms may include vomiting, swollen lymph nodes, swollen joints, joint contractures. Patients with breathing difficulty may require insertion of a breathing tube.<sup>20</sup>

Our case had severe respiratory distress requiring intubation at the time of birth, joint contractures, no acquired motor milestones, epileptiform pattern EEG, CT with atrophic brain changes and some scleroderma like skin lesions. All previously reported manifestations of Farber disease were present however, there was neither painful joint swelling nor severe hoarseness of voice, two important diagnostic criteria of Farber disease.<sup>7</sup>

Histopathological studies of skin biopsy as previously reported was our diagnostic clue in the case settling the diagnosis of Farber disease.

The orodental findings up to our knowledge in both Farber disease and stiff skin syndrome were not previously reported. Thick alveolar ridge, gingival enlargement and spooned tongue are the main unusual orodental findings recorded in the studied case. Thick alveolar ridge, thick lips and gingival enlargement were previously reported among features of storage disorders while spooned tongue was previously reported with syndromes with contracture deformities. Therefore we conclude that those findings can be matched more with Farber disease rather than stiff skin syndrome.<sup>23,24</sup>

Reporting of rare disorders, differential diagnosis and clarification of overlapping phenotypes is an important modifier in counseling and management decision making. Recognition of atypical

or abortive cases is of practical importance. Sometimes as in congenital facial dystrophy (variant of heterogeneous SSS involving exclusively fascia) no therapy is required, intensive rehabilitation should start in early infancy and continue throughout life. On the other hand bone marrow transplantation is recommended in cases of Farber disease without visceral affection. Otherwise corticosteroids as symptomatic management is prescribed. Also more orodental studies on reported cases may expand the spectrum of disease manifestations.

## REFERENCES

---

1. McKusick VA. Online Mendelian Inheritance in Man (OMIM). Available at: <http://www.ncbi.nlm.nih.gov/sites/entrez?db=omim>. Accessed, 2009.
2. Farber S. A lipid metabolic disorder—disseminated lipogranulomatosis. A syndrome with similarity to and important difference from, Niemann-Pick and Hand-Schüller-Christian disease. *Am. J. Diss.Child.* 1952; 84:499-500.
3. Farber S, Cohen J, Uzman LL. Lipogranulomatosis. A new lipoglycoprotein “storage” disease. *J. Mt. Sinai Hosp.* 1957; 24:816-37.
4. Ehlert K, Frosch M, Fehse N, Zander A, Roth J, Vormoor J. Farber disease: Clinical presentation, pathogenesis and a new approach to treatment. *Pediatr. Rheumatol.Online J.* 2007;5:15.
5. Hoang TR, Hammermuller A, Mix E, Kreutzer HJ, Goerlich R, Kohler H, et al. A proinflammatory role for Fas in joints of mice with collagen-induced arthritis. *Arthritis Res.Ther.* 2004;6(5):R404-14.

6. Ma Y, Liu H, Tu Rapp H, Thiesen HJ, Ibrahim SM, Cole SM, et al. Fas ligation on macrophages enhances IL-1-R1-Toll-like receptor 4 signaling and promotes chronic inflammation. *Nat. Immunol.* 2004; 5(4):380-7.
7. Ahmad A, Mazhar AU, Anwar M. Farber disease: A rare neurodegenerative disorder. *Journal of the College of Physicians and Surgeons Pakistan* 2009;19(1):67-8.
8. Zarbin MA, Green WR, Moser HW, Morton SJ. Farber's disease. Light and electron microscopic study of the eye. *Arch.Ophthalmol.* 1985; 103(1):73-80.
9. Moser HW, Moser AB, Chen WW, Schram AW. Ceramidase deficiency: Farber lipogranulomatosis. In: Scriver CR, Beaudet AL, Sly WS, Valle E, editors. *The metabolic basis of inherited disease.* 6<sup>th</sup> ed. New York: McGraw-Hill Book Co.; 1989. p. 1645-54.
10. Moser HW, Linke T, Fensom AH, Levade T, Sandhoff K. Acid ceramidase deficiency: Farber lipogranulomatosis. In: Scriver CR, Beaudet AL, Sly WS, Valle D, Childs B, Kinzler KW, et al, editors. *The metabolic and molecular bases of inherited disease.* 8<sup>th</sup> ed. New York: McGraw-Hill; 2001. p. 3573-85.
11. Antonarakis SE, Valle D, Moser HW, Moser A, Qualman SJ, Zinkham WH. Phenotypic variability in siblings with Farber disease. *J. Pediatr.* 1984; 104(3): 406-9.
12. Eviatar L, Sklower SL, Wisniewski K, Feldman RS, Gochoco A. Farber lipogranulomatosis: An unusual presentation in a black child. *Pediatr. Neurol.* 1986; 2(6):371-4.
13. Fusch C, Huenges R, Moser HW, Sewell AC, Roggendorf W, Kuster-mann Kuhn B, et al. A case of combined Farber and Sandhoff disease. *Eur.J.Pediatr.* 1989;148(6):558-62.
14. Schnabel D, Schroder M, Furst W, Klein A, Hurwitz R, Zenk T, et al. Simultaneous deficiency of sphingolipid activator proteins 1 and 2 is caused by a mutation in the initiation codon of their common gene. *J. Biol. Chem.* 1992; 267(5):3312-5.
15. Devi AR, Gopikrishna M, Ratheesh R, Savithri G, Swarnalata G, Bashyam M. Farber lipogranulomatosis: Clinical and molecular genetic analysis reveals a novel mutation in an Indian family. *J.Hum.Genet.* 2006;51(9):811-4.
16. Chanoki M, Ishii M, Fukai K, Kobayashi H, Hamada T, Murakami K, et al. Farber's lipogranulomatosis in siblings: Light and electron microscopic studies. *Br. J. Dermatol.* 1989; 121(6):779-85.
17. Jablonska S, Blaszczyk M. Scleroderma-like indurations involving fascias: An abortive form of congenital fascial dystrophy (Stiff skin syndrome). *Pediatr.Dermatol.* 2000; 17(2):105-10.
18. Mat C, Kalayciyan A, Arzuhal N, Demirkesen C, Karacorlu M, Tuzun Y. Stiff skin syndrome: A case report. *Pediatr.Dermatol.* 2003; 20(4):339-41.
19. Liu T, McCalmont TH, Frieden IJ, Williams ML, Connolly MK, Gilliam AE. The stiff skin syndrome: Case series, differential diagnosis of the stiff skin phenotype and review of the literature. *Arch. Dermatol.* 2008; 144(10):1351-9.

20. Clements PJ, Furst DE. Systemic sclerosis. 2<sup>nd</sup> ed. Baltimore, Md: Lippincott Williams & Wilkins; 2003.
21. Hoffmann R, Lohner M, Boehm N, Leititis J, Helwig H. Restrictive dermopathy: A lethal congenital skin disorder. *Eur.J.Pediatr.* 1993; 152(2):95-8.
22. Stevenson RE, Lucas TL Jr and Martin JB. Symmetrical lipomatosis associated with stiff skin and systemic manifestations in four generations. *Proc. Greenwood Genet. Center*; 1984; 3: 56-64.
23. Gorlin RJ, Cohen MM Jr, Hennekam RCM. Syndromes of the head and neck. 4<sup>th</sup> ed. New York: Oxford University Press; 2001.
24. Temtamy SA, Nemat AM, Ramzy MI, Fateen EM, Abdel Meguid N, Aboul-Ezz EHA. Ultrastructure of gingival biopsy in lysosomal storage disorders. *Cairo Dent. J.* 2000; 16 (4):287-95.