CASE REPORT Egypt. J. Med. Hum. Genet. Vol. 9, No. 2, Nov. 2008

Holoprosencephaly: A report of 2 cases with different presentations

Rabah M. Shawky[1] and Doaa I. Sadik[2]

[1]Pediatric Department, [2]Medical Genetics Center, Ain Shams University

ABSTRACT

Holoprosencephaly is a common developmental defect of the forebrain and midface in humans. Clinical expression is variable, extending in unbroken sequence from a small brain with a single cerebral ventricle and cyclopia to clinically unaffected carriers in familial holoprosencephaly.
Here, we describe two unrelated affected cases, with alobar, and semilobar holoprosencephaly with different presentations and clarified the associated phenotypic changes in form of microcephaly, hypotelorism, flat nose, a single nostril, a midline cleft lip and palate in the first case and solitary median maxillary central incisor, associated with prominent midline palatal ridge in the second case.

Key words:
Holoprosencephaly,ocularhypotelorism, central incisor, microcephaly, cleft lip.

Corresponding Author:
Dr: Rabah M. Shawky
Email: shawkyrabah @yahoo.com

INTRODUCTION

Holoprosencephaly (HPE, MIM 236100) is a complex human brain malformation resulting from incomplete cleavage of the prosencephalon into right and left hemispheres, occurring between the 18th and the 28th day of gestation. Three levels of increasing severity are described[1]: lobar HPE, where the right and left ventricles are separated, but with some continuity across the frontal cortex; semilobar HPE with a partial separation, and the most severe form, alobar HPE, with a single brain ventricle and no interhemispheric fissure[2,3]. Holoprosencephaly is the most common forebrain developmental anomaly in humans with prevalence of 1/16,000 in live borns[4], an incidence as high as 1:250 in conceptuses[5], and a worldwide distribution[6]. The etiology of HPE is very heterogeneous. First, this pathology can be caused by environmental or metabolic factors. The only formally recognized environmental factors are insulin-dependent diabetes mellitus (1% risk of HPE) [7] and maternal alcoholism with a risk that cumulates with smoking[8]. HPE in humans has also been noted in association with prenatal exposure to drugs (retinoic acid, cholesterol biosynthesis inhibitors)[9] or to infections (cytomegalovirus[10], toxoplasma[11], rubella)[12]. The OMIM classification shows that HPE can also be associated in about 25% of the cases with several

Copyright: All rights reserved for The Egyptian Journal of Medical Human Genetics

defined multiple malformation syndromes with a normal karyotype, like Smith-Lemli-Opitz[13], Pallister Hall[14] or velo-cardio-facial syndrome[15]. HPE can be due to chromosomal abnormalities, with a higher prevalence observed in trisomy13 (70%), trisomy 18 and triploidy. Finally, HPE may be a solitary manifestation (neither chromosomal nor syndromic) and several genes are implicated in this isolated form of HPE. To date, seven genes have been positively implicated in HPE: Sonic hedgehog (SHH)[16], ZIC2[17], SIX3[18], TGIF[19], PTCH[20], GLI2[21], and TDGF1[22]. A molecular diagnosis can be performed by gene sequencing and allele quantification for the four main genes SHH, ZIC2, SIX3 and TGIF[23]. In most of the cases of HPE, facial anomalies are observed, like cyclopia, proboscis, median or bilateral cleft lip/palate in severe forms, ocular hypotelorism or solitary median maxillary central incisor in minor forms. Children with HPE have many medical problems; developmental delay and feeding difficulties[6] epilepsy, instability of temperature, heart rate and respiration. Endocrine disorders like diabetes insipidus, adrenal hypoplasia, hypogonadism, thyroid hypoplasia and growth hormone deficiency are frequent.[24]

Case report (1):

An infant girl 3 months old, 4th offspring of a consanguineous marriage between healthy parents. She was born at full term. The mother was not diabetic and she had history of rash, during the 3rd trimester, most probably drug rash. The birth weight was 3000 gms, and she was incubated for 6 days because of feeding problems. Pedigree analysis revealed one female sibling 1st offspring with talipes equinovarus, died at one day old, and another female sibling 3rd offspring with microcephaly died at age of 4 months without knowing the cause of death. There was also a maternal history of spontaneous abortion at 16 weeks gestation. Also there was history of a maternal cousin who had a gestation terminated at 6th month because of ancephaly. The examination revealed an infant with a microcephaly (below the 3rd centile), hypotelorism, blue sclera, macrocornea (Figure 1), flat nose, a single nostril (Figure 2), a midline cleft lip and small cleft palate and large ears (Figure 3). There were no clinical features suggestive of trisomy 13 or trisomy 18. With a clinical diagnosis of holoprosencephaly (HPE), a CT scan was done, which showed, alobar HPE, marked hydrocephalic changes involving the ventricular system with atrophy of bilateral frontal and temproparietal regions (Figure 4). Echocardiography showed no cardiac lesion. Pelviabdominal ultrasound was normal. The result of chromosomal analysis of peripheral blood lymphocytes from this child was normal.

Fig. 1: Microcephaly, hypotelorism, midface hypoplasia, premaxillary agenesis, midline cleft lip, and small cleft palate.

Fig. 2: Cebocephaly (hypotelorism and a single nostril).

Fig. 3: Large ears.

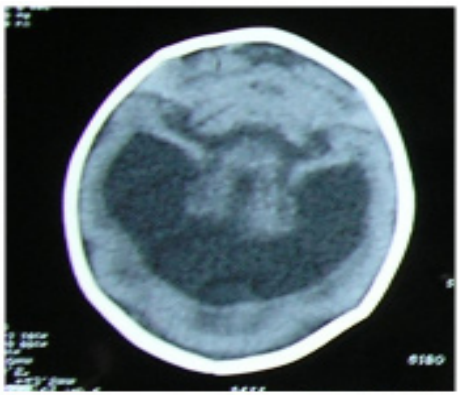

Fig. 4: CT scan showing alobar HPE. Note fusion of the frontal lobes, thinned out cortex. and marked hydrocephalic changes involving the ventricular system with atrophy of bilateral frontal and temproparietal regions.

Case report 2:

A one year old boy, the second in order of birth of a non consanguineous marriage. He presented to us with delayed mental and motor milestones of development and history of convulsions. There was no history suggestive of a teratogenic insult. The first pregnancy for the 24-year old mother, produced a female stillbirth (at 9 m. gestation). Pedigree analysis revealed a maternal cousin 2.5y old boy with sickle thalassemia and convulsions.

On examination, the weight was 7 kg (below the 5th centile) and length was 73.5cm (at the 25th centile). His skull circumference was 39.5 cm (below the 3rd centile). He had nystagmus. The most striking anomaly in his face was a solitary median maxillary central incisor (Figure 5), and prominent midline palatal ridge (Figure 6). The external ears were large. No cleft lip or cleft palate, but there was micrognathia. The anterior abdominal wall examination revealed paraumbilical hernia. Neurological examination revealed spasticity and hyperreflexia.

MRI examination of the brain was undertaken. Semilobar holoprosencephaly is shown by absent anerior falx cerebri, no differentiation of the anterior horns of the lateral ventricles with bifrontal fusion showing gray and white matter continuity. Partial thalamic fusion is noted. Hypoplastic corpus callosum.

Fig. 5: A solitary median maxillary central incisor

Fig. 6: Prominent midline palatal ridge.

DISCUSSION

HPE is a complex brain malformation resulting from incomplete cleavage of the prosencephalon, affecting the forebrain. Therefore, clinical manifestations involve the central nervous system with possible facial dysmorphism and various complications[25]. A spectrum of craniofacial anomalies accompanies HPE in approximately 80% of affected individuals. In the majority of individuals with HPE, a correlation exists between the facial anomalies and the subtype of HPE; however, many examples exist in which this correlation cannot be made, particularly in individuals with milder forms of HPE[26, 27]. The first case reported here was, a girl with holoprosencephaly and cleft lip and palate, who had a female sibling with microcephaly and a maternal cousin who had a history of a stillbirth with an ancephaly. Heussler et al.[28], reported that microcephaly is microforms of HPE that can be observed in relatives of probands with HPE. The craniofacial anomalies of our 2 cases was extremely variable; severe in the first case with alobar HPE, and mild in the second case with semilobar HPE. DeMyer et al.[29], suggested that the type of brain malformation can be predicted by the facial development; the closer it approaches to the normal, so does the brain. However, several other studies have implied that this is not necessarily so. Miller[30] reported a case with severe degree of facial anomaly, while the brain revealed absence of olfactory bulbs as the only abnormality, contrary to the expected HPE. This suggests that other modulatory factors are involved in the stages of morphogenesis of embryonally related structures. As regards eye changes, the eyes of the first case, showed severe hypotelorism, blue sclera, and macrocornea, and in the second case the eyes were normal. Arathi et al.[31], reported that the eye changes in HPE may vary from gross to subtle. As regards palatal anomalies in the first case there was cleft palate and in the second case there was midline palatal ridge. Kjaer et al.[32], reported that in HPE the palatal anomalies include various midline and lateral clefts, midline palatal ridge, bifid uvula, and absence of the superior labial frenulum. In the second case there was a single central incisor. Although a single central incisor is a nonspecific finding, it is a distinctive microform in autosomal dominant HPE[33] There was paraumbilical hernia in the second case[34]. Jellingen et al. reported that systemic examination of the HPE cases may reveal varying degrees and

patterns of extracerebral abnormalities. They found associated anomalies in other organs in 53.5% cases, the commonest being in the gastrointestinal system. The authors stated that there is considerable heterogeneity of associated malformations in the CNS and even greater outside the CNS, due to widespread varied developmental disturbances. The etiology of HPE midline defects in man is not known. Association of the disorder with various recessively inherited syndromes suggests a genetic basis. In general, HPE with few or no extracerebral systemic anomalies have normal karyotype. Those who have extracephalic anomalies along with HPE are usually found to have trisomy13 or 18 and triploidy[6-11]. However, exceptions to these observations exist.[31]

In our 2 cases there were neurological signs in the first case with hydrocephalus , which is of importance in neurosurgical practice, and in second case there was developmental delay, convulsions, and spasticity. Jellinger et al.[34] reported associated hydrocephalus in 52% HPE cases. Interestingly, in a review of 100 cases of HPE it was noted that hydrocephalus was not prevalent in patients with apparent facial dysmorphias but common in cases without facial stigmata[35]. Similarly, hydrocephalus is uncommon in alobar HPE, but common in the semilobar and lobar types.[31]

As regards developmental delay. Dubourg et al.[24] reprted that it is present in all live born HPE patients, and seems in agreement with the severity of the brain malformation. Approximately half of the patients with HPE develop epilepsy. Many other signs like mental retardation, hypotonia, weakness, spasticity, dystonia and abnormal movements are described.

In the second case the MRI showed the continuity of the grey and white matter, partial thalamic fusion and hypoplastic corpus callusom. Abnormal separation of the deep gray nuclei has been found to be correlated with neurodevelopmental dysfunction, particularly in the areas of gross motor ability, upper extremity function, and language development.[36]

Given the cognitive role of the caudate nuclei[37] and the importance of the sensory pathways provided by the thalamic nuclei to the cerebral cortex[38], it is posited that there might be a clinically relevant association between abnormalities in deep gray structures and cognitive outcomes in children with holoprosencephaly. The caudate nuclei, in particular, receive all input to the basal ganglia and are intricately involved in the dorsolateral prefrontal circuit. This circuit has been implicated as a way-station for the processing of sensory and cognitive information during tasks such as organizing behavioral responses and verbal problem solving[39], as a consequence, malformation of the caudate nuclei would affect performance on those cognitive tasks. Likewise, the lentiform nuclei are important for their motoric role and the thalamic nuclei for their involvement in the relay of sensory information to the cerebral cortex; hence, these deep gray structures would also be likely to impact cognitive performance[40]. In the present 2 cases, karyotype study was carried out, and it was normal. It is important to emphasize that the prognosis in holoprosencephaly is much poorer for those with cytogenetic abnormalities, with only 2% surviving beyond 1 year, compared with 30–54% for those without cytogenetic anomalies.[4]

REFERENCES

1. Demyer W, Zeman W. Alobar holoprosencephaly (arhinencephaly) with median cleft lip and palate: Clinical, electroencephalographic and nosologic considerations. Confinia Neurol 1963; 23 (1): 1-36.

2. Barkovich AJ, Quint DJ. Middle interhemispheric fusion: An unusual variant of holoprosencephaly. AJNR Am.J.Neuroradiol. 1993 ;14 (2): 431-40.

3. Simon EM, Hevner RF, Pinter JD, Clegg NJ, Delgado M, Kinsman SL, et al. The middle interhemispheric variant of holoprosencephaly. AJNR Am.J.Neuroradiol. 2002; 23 (1): 151-6.

4. Croen LA, Shaw GM, Lammer EJ. Holoprosencephaly: Epidemiologic and clinical characteristics of a California population. Am.J.Med.Genet. 1996 23; 64 (3): 465-72.

5. Matsunaga E, Shiota K. Holoprosencephaly in human embryos: Epidemiologic studies of 150 cases. Teratology 1977; 16 (3): 261-72.

6. Hahn JS, Plawner LL. Evaluation and management of children with holoprosencephaly.Pediatr.Neurol. 2004; 31 (2): 79-88.

7. Barr M,Jr, Hanson JW, Currey K, Sharp S, Toriello H, Schmickel RD, et al. Holoprosencephaly in infants of diabetic mothers. J.Pediatr. 1983; 102 (4): 565-8.

8. Croen LA, Shaw GM, Lammer EJ. Risk factors for cytogenetically normal holoprosencephaly in California: A population-based case-control study. Am.J.Med.Genet. 2000 14; 90 (4): 320-5.

9. Repetto M, Maziere JC, Citadelle D, Dupuis R, Meier M, Biade S, et al. Teratogenic effect of the cholesterol synthesis inhibitor AY 9944 on rat embryos in vitro. Teratology 1990; 42 (6): 611-8.

10. Frenkel LD, Gaur S, Tsolia M, Scudder R, Howell R, Kesarwala H. Cytomegalovirus infection in children with AIDS. Rev.Infect. Dis. 1990; 12 Suppl 7: S820-6.

11. Castel Y, Riviere D, Toudic L, Nouaille Y, L'Henoret J, Duparcmeur H, et al. Deux cas de cyclopie. [Two cases of cyclopia]. Ann.Pediatr. (Paris) 1976 2; 23(10): 647-51.

12. Probst C. Pathologische, diagnostische und therapeutische probleme beim hirnodem aus neurochirurgischer Sicht [Cerebral edema: Neurosurgical aspects of pathological, diagnostic and therapeutic problems (author's transl)].Schweiz.rundsch.Med]. Prax. 1976 3; 65 (31): 948-56.

13. Kelley RL, Roessler E, Hennekam RC, Feldman GL, Kosaki K, Jones MC, et al. Holoprosencephaly in RSH/Smith-Lemli-Opitz syndrome: Does abnormal cholesterol metabolism affect the function of Sonic Hedgehog? Am.J.Med. Genet. 1996 30; 66 (4): 478-84.

14. Hall JG, Pallister PD, Clarren SK, Beckwith JB, Wiglesworth FW, Fraser FC, et al. Congenital hypothalamic hamartoblastoma, hypopituitarism, imperforate anus and postaxial polydactyly--a new syndrome? Part I: Clinical, causal and pathogenetic considerations.

Am.J.Med.Genet. 1980; 7 (1): 47-74.

15. Roessler E, Muenke M. Holoprosencephaly: A paradigm for the complex genetics of brain development. J.Inherit.Metab. Dis. 1998; 21 (5): 481-97.

16. Belloni E, Muenke M, Roessler E, Traverso G, Siegel Bartelt J, Frumkin A, et al. Identification of Sonic hedgehog as a candidate gene responsible for holoprosencephaly. Nat. Genet. 1996; 14 (3): 353-6.

17. Brown LY, Hodge SE, Johnson WG, Guy SG, Nye JS, Brown S. Possible association of NTDs with a polyhistidine tract polymorphism in the ZIC2 gene. Am.J.Med. Genet. 2002 1; 108 (2): 128-31.

18. Wallis DE, Muenke M. Molecular mechanisms of holoprosencephaly. Mol.Genet. Metab. 1999; 68 (2): 126-38.

19. Gripp KW, Wotton D, Edwards MC, Roessler E, Ades L, Meinecke P, et al. Mutations in TGIF cause holoprosencephaly and link NODAL signalling to human neural axis determination. Nat. Genet. 2000; 25 (2): 205-8.

20. Ming JE, Kaupas ME, Roessler E, Brunner HG, Golabi M, Tekin M, et al. Mutations in PATCHED-1, the receptor for SONIC HEDGEHOG, are associated with holoprosencephaly. Hum. Genet. 2002; 110 (4): 297-301.

21. Roessler E, Du YZ, Mullor JL, Casas E, Allen WP, Gillessen Kaesbach G, et al. Loss-of-function mutations in the human GLI2 gene are associated with pituitary anomalies and holoprosencephaly-like features. Proc.Natl. Acad.Sci.U.S.A. 2003 11; 100 (23): 13424-9.

22. De la Cruz JM, Bamford RN, Burdine RD, Roessler E, Barkovich AJ, Donnai D, et al. A loss-of-function mutation in the CFC domain of TDGF1 is associated with human forebrain defects. Hum.Genet. 2002; 110 (5): 422-8.

23. Traiffort E, Dubourg C, Faure H, Rognan D, Odent S, Durou MR, et al. Functional characterization of sonic hedgehog mutations associated with holoprosencephaly. J.Biol.Chem. 2004 8; 279 (41): 42889-97.

24. Dubourg C, Bendavid C, Pasquier L, Henry C, Odent S, David V. Holoprosencephaly. Orphanet J.Rare Dis. 2007; 2:8.

25. Picone O, Hirt R, Suarez B, Coulomb A, Tachdjian G, Frydman R, et al. Prenatal diagnosis of a possible new middle interhemispheric variant of holoprosencephaly using sonographic and magnetic resonance imaging. Ultrasound Obstet.Gynecol. 2006; 28 (2): 229-31.

26. Brown LY, Odent S, David V, Blayau M, Dubourg C, Apacik C, et al. Holoprosencephaly due to mutations in ZIC2: Alanine tract expansion mutations may be caused by parental somatic recombination. Hum.Mol. Genet. 2001 1; 10 (8): 791-6.

27. Brown SA, Warburton D, Brown LY, Yu CY, Roeder ER, Stengel Rutkowski S, et al. Holoprosencephaly due to mutations in ZIC2, a homologue of Drosophila odd -paired. Nat. Genet. 1998; 20 (2): 180-3.

28. Heussler HS, Suri M, Young ID, Muenke M. Extreme variability of expression of a Sonic Hedgehog mutation: Attention difficulties and holoprosencephaly. Arch.Dis.Child. 2002; 86 (4): 293-6.

29. Demyer W, Zeman W, Palmer CG. The Face Predicts the Brain: Diagnostic significance of median facial anomalies for holoprosencephaly (Arhinencephaly). Pediatrics 1964; 34: 256-63.

30. Miller JQ, Picard EH, Alkan MK, Warner S, Gerald PS. A specific congenital brain defect (arhinencephaly) in 13-15 trisomy. New Engl. J. Med. 1963; 268 (3): 120-3.

31. Arathi N, Mahadevan A, Santosh V, Yasha TC, Shankar SK. Holoprosencephaly with cyclopia--report of a pathological study. Neurol. India 2003; 51 (2): 279-82.

32. Kjaer I, Keeling J, Russell B, Daugaard Jensen J, Fischer Hansen B. Palate structure in human holoprosencephaly correlates with the facial malformation and demonstrates a new palatal developmental field. Am.J.Med. Genet. 1997 31; 73 (4): 387-92.

33. Berry SA, Pierpont ME, Gorlin RJ. Single central incisor in familial holoprosencephaly. J. Pediatr. 1984; 104 (6): 877-80.

34. Jellinger K, Gross H, Kaltenback E, Grisold W. Holoprosencephaly and agenesis of the corpus callosum: Frequency of associated malformations. Acta Neuropathol. 1981; 55 (1): 1-10.

35. Osaka K, Matsumoto S. Holoprosencephaly in neurosurgical practice. J.Neurosurg. 1978; 48 (5): 787-803.

36. Plawner LL, Delgado MR, Miller VS, Levey EB, Kinsman SL, Barkovich AJ, et al. Neuroanatomy of holoprosencephaly as predictor of function: Beyond the face predicting the brain. Neurology 2002 8; 59 (7): 1058-66.

37. Bhatia KP, Marsden CD. The behavioural and motor consequences of focal lesions of the basal ganglia in man. Brain 1994; 117 (Pt 4): 859-76.

38. Best PJ, Weldon DA, Stokes KA. Lesions of mediodorsal thalamic nucleus cause deficits in attention to changes in environmental cues without causing sensory deficits. Ann.N.Y.Acad.Sci. 1990 ; 608: 705-14;discussion:714-6.

39. Kandel ER, Schwartz JH, Jessell TM. The functional organization of perception and movement: Principles of neuroscience. New York: McGraw-Hill; 2000.

40. Roesler CP, Paterson SJ, Flax J, Hahn JS, Kovar C, Stashinko EE, et al. Links between abnormal brain structure and cognition in holoprosencephaly. Pediatr.Neurol. 2006; 35 (6): 387-94.