

Developmental abnormalities of mid and hindbrain: A study of 23 Egyptian patients

Laila A. Selim¹, Maha S. Zaki², Hassan A. Hussein³, Sahar N. Saleem⁴, Ahmed S. Kotoury² and Mahmoud Y. Issa².

¹Pediatric Neurology Department, Cairo University, ²Clinical Genetics Department, Human Genetics and Genome Research Division, National Research Centre, ³Human Cytogenetics Department, Human Genetics and Genome Research Division, National Research Centre, ⁴Radiodiagnosis Department, Cairo University.

ABSTRACT

Introduction: With the advent of neuroimaging modalities specifically, magnetic resonance imaging (MRI), recognition of developmental defects of posterior fossa has greatly improved.

The Aim: Is to delineate the clinical, cytogenetics and radiological features of patients with mid-hindbrain anomalies.

Patient and Methods: Twenty-three patients with mid-hind brain malformations were included in this study. Complete clinical evaluation, cytogenetic analysis and neuroradiological study were done for each patient. Patients' sex ratio was (M: F/ 0.9:1) and the mean age was 2.17 years. Parental consanguinity was 86.9 % and positive family history was recorded in 7 families. Based on clinico-radiological findings, patients were categorized as Joubert syndrome and related cerebellar disorders (34.8%), pontocerebellar hypoplasia (26.1%), lissencephaly cerebellar hypoplasia (13%), isolated cobblestone lissencephaly with normal muscle and eye (8.7%), isolated vermian hypoplasia (13%) and retrocerebellar cyst (4.4%).

Results: Cytogenetic analysis revealed abnormalities in 3 patients (13%); pericentric inversion of chromosome 8 in a patient with lissencephaly cerebellar hypoplasia, del 5p14.3-pter delineating Cri du chat syndrome and associated with vermian hypoplasia and del 18q21.1-qter in a patient with retrocerebellar cyst due to paternal balanced translocation t (4;18). FISH for specific locus and whole chromosomal painting were used to document the assigned aberrations. Although most of the cerebellar malformations are of Mendelian inheritance, this study emphasizes the importance of chromosomal analysis for patients with posterior fossa anomalies. With more researches describing clinico-radiological characterization of hind brain dysgenesis will allow better understanding of these disorders, further delineation of relevant syndromes and new genes identification.

Key Words:

Cerebellar, hindbrain, joubert syndrome, cobblestone lissencephaly-pontocerebellar hypoplasia, cri du chat syndrome- del 18q21.1-qter.

Corresponding Author:

Dr: Maha S Zaki

E-mail: mszaki60@internetegypt.com

INTRODUCTION

Mid-hindbrain regions comprise the posterior fossa structures that include the brainstem (midbrain, pons, and medulla), the cerebellum and related cerebrospinal fluid spaces including the aqueduct of Sylvius, 4th ventricle and its outflow tracts; the foramina of Luschka and Magendie¹. Malformations of the posterior fossa have been recognized much more frequently during the past decades, based upon rapid advances in imaging technologies. However, with this improvement perplexing problems of categorization and syndrome delineation have arisen, as more subtle structural anomalies can now be identified². Several different classification schemes of malformations of posterior fossa structures have been proposed based on mere anatomical or radiological basis^{3,4}. Nevertheless, the most recent classification delineated by Parisi and Dobyns² was based on the embryological derivation of the involved structures. They categorized these anomalies into 6 major groups; 1- Malformations of both midbrain and hindbrain: Brain stem-cerebellar hypoplasia, complete cerebellar agenesis, Chiari II malformation, cobblestone lissencephaly with mid-hindbrain malformation, molar tooth sign associated anomalies [including Joubert syndrome and related disorders (JSRD)] and rhombencephalosynapsis {which is absence cerebellar vermis and fusion of both hemispheres with variable fusion of brain stem}; 2-Malformations affecting the midbrain which was only mentioned by authors for theoretical purpose and no reported literature of isolated mesencephalon malformation; 3- Malformations affecting predominantly the cerebellum: Focal cerebellum hypoplasia, paleocer-

bellar hypoplasia {as cerebellar vermian hypoplasia and Dandy-Walker malformation and neocerebellar hypoplasia {including hemispheres and vermis}^{5,6}; 4- Malformations affecting predominantly the lower hindbrain: Chiari I malformation and cranial nerve and nuclear aplasias {as in Mobius syndrome and Duane retraction syndrome}; 5- Abnormal fluid collections: Posterior fossa arachnoid cyst, Blake's pouch cyst and mega-cisterna magna; 6- Malformations associated of prenatal onset degeneration: Ponto-cerebellar hypoplasia {type 1-5 or in association with some other metabolic disorders as neuroaxonal dystrophy, mitochondrial defects, PEHO (progressive encephalopathy with edema hypsarrhythmia, and optic atrophy) and Congenital disorders of glycosylation}³⁻¹¹.

Chromosomal aberrations have been reported with cerebellar malformations especially Dandy-Walker and Chiari malformations, cerebellar vermian hypoplasia and posterior fossa cyst mostly involved chromosome 1, 3, 5, 9, 13, 18 and 22.¹²⁻¹⁵

In this study, we present 23 patients with mid-hind brain anomalies. The aim of this work is proper delineation of clinico-radiological features of patients with mid-hindbrain anomalies and detection of chromosomal aberrations among these patients.

PATIENTS AND METHODS

Twenty-three patients with mid-hind brain anomalies are included in this study. Patient selection was based on detection of abnormalities in mid-hind

brain by neuroimaging. All patients were subjected to complete family history, pedigree construction, prenatal, natal and early postnatal histories. Neonatal and infancy histories were taken with special emphasis on apneic spells, abnormal breathing pattern, feeding problems and abnormal eye movements. Developmental history, complete clinical examination, detection of specific facies, and neurological evaluation, stressing on seizures (the onset, type and severity) were done for all cases. Also, basic anthropometric measurements (weight, height and head circumference) were assessed.

Magnetic resonance imaging (MRI):

Was performed for all patients as it was our clue for patient's selection. All patients needed sedation during neuroimaging examinations. Sedation by chloral hydrate was given for infants while I.V. Diazepam for older children.

MRI was performed on 1.0 Tesla unit (Signa, GE, Milwaukee) using a head coil. Some MR examinations were performed on 1.0 Tesla (Gyrosan NT 10; Philips Medical systems). MR examinations, using head coil, included: Axial and coronal T2 FSE using 2000 – 5000/98-120 TR msec/TE msec, one to four signals acquired, 16-22 cm FOV with or without a rectangular field, 192-256 x 256 matrix, 3-5 mm thick sections with 0.3-0.5 mm intersection gap. Axial T1 weighted images were obtained using 400-650/20-30 TR msec/TE msec, 2-4 signals acquired, 128-192 x 256 matrix, 16-22 cm FOV, 3-5 mm thick contiguous sections. Sagittal T1 WSE MR imaging (400-700/11-20, 1-2 signals acquired, 128 -192 x 256 matrix, 20-24 cm FOV, 5 mm thick sections with 0-2.5 mm intersection gap. Ad-

ditional coronal T1 WSE was obtained using the same parameters used for axial T1. Axial T2 FLAIR (Fluid attenuated inversion recovery) images were done using 10,000/140/2, 200 TR msec/ echo time msec/ inversion time msec, one signal acquired, 20-22 cm FOV, 192 x 256 matrix, 4-5 mm thick sections with 1.0 – 2.5 mm intersection gap.

Accurate description of cerebellar and brain stem malformation was assigned. Moreover, the appearance of cerebral cortex, white matter, lateral ventricles, corpus callosum, basal ganglia, hippocampal and extra axial spaces were also recorded.

Cytogenetic studies: Chromosome studies of human blood lymphocytes was carried out **for all patients** using both G-banding and high resolution techniques.¹⁶⁻¹⁸

Fluorescent in situ hybridization (FISH) was performed for a single case (19) using specific probe for the chromosome 5 LSI D5S23, D5S721 probe (spectrum green) detects deletion of 5p15.2 which associated with Cri-du-chat syndrome, LSI EGR1 (5q31) (spectrum orange) as control. Moreover, whole chromosomal painting (WCP) was done for the father of patient 23 with deletion 18q21.1-qter to document 4; 18 translocation.

Other investigations: Including complete eye evaluation, echocardiography, abdominal ultrasound, laboratory tests (liver and kidney function tests, serum creatine phosphokinase and congenital infections screening), neurophysiological studies {electroencephalogram (EEG), electromyography (EMG), nerve conduction velocity (NCV), electroretinogram (ERG), visual evoked

potential (VEP) and brain stem auditory evoked potential (BAEP)} and X-rays in any associated skeletal changes were done when indicated.

RESULTS

Our studied 23 patients were derived from 16 families. They were 11 males and 12 females (ratio: 0.9:1), with mild sex skewing toward female. Their age ranged from 3 months to 8 years with mean age (2.17 years). Parental consanguinity was present in 20 cases (86.9%) and consanguinity in familial cases reached 100%.

Based on clinico-radiological findings,

we categorized our studied patients into: Eight patients with Joubert syndrome and related cerebellar disorders (JSRD) (case 1-8) (Figure 1), six patients with pontocerebellar hypoplasia (case 9- 14) (Figure 2), three patients with variable types of lissencephaly cerebellar hypoplasia (case 15-17) (Figure 3,4), two patients with isolated cobblestone lissencephaly with normal muscle and eye (case 18-19) (Figure 5), two patients with vermian hypoplasia (possibly the X-linked form), (case 20-21) (Figure 6), a patient with Cri du chat syndrome associated with vermian hypoplasia (case 22) (Figure 7) and a single patient (case 23) had del 18q21.1-qter and retrocerebellar cyst (Figure 8) (Table 1).

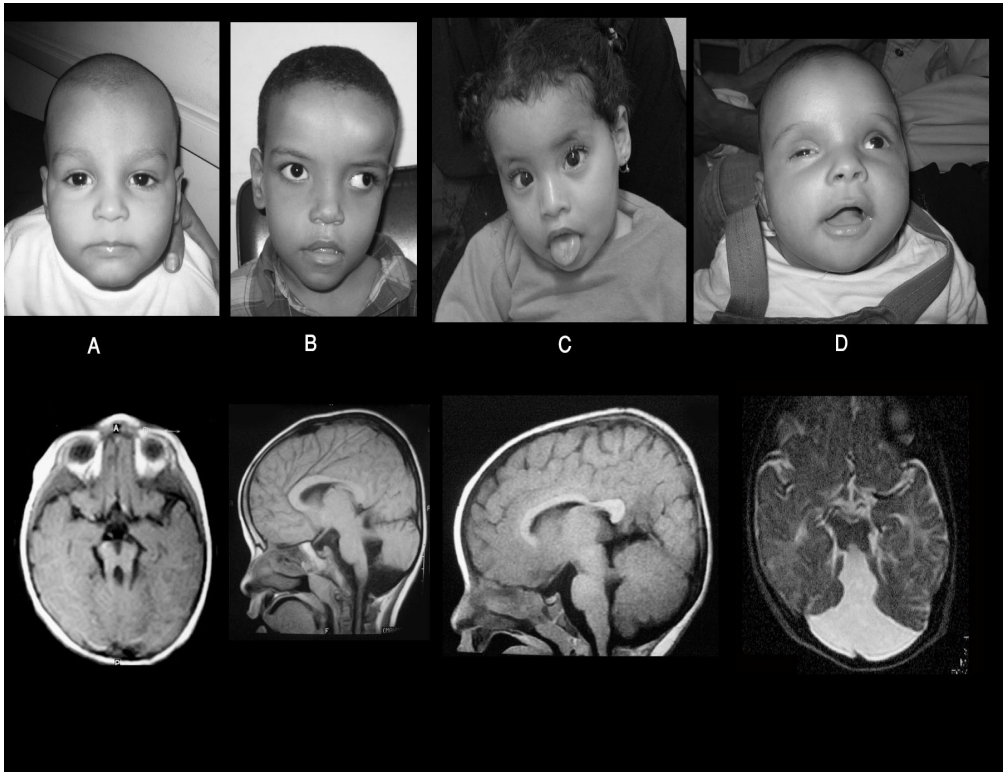


Fig. 1: Joubert syndrome and related cerebellar disorders. Note; specific facies as frontal bossing, microphthalmia, ptosis, open mouth, protruded tongue. Brain MRI showed molar tooth sign in axial cuts and elongated superior cerebellar peduncle with mild vermian hypoplasia in sagittal cuts. Note Dandy-Walker malformation in patient (D).

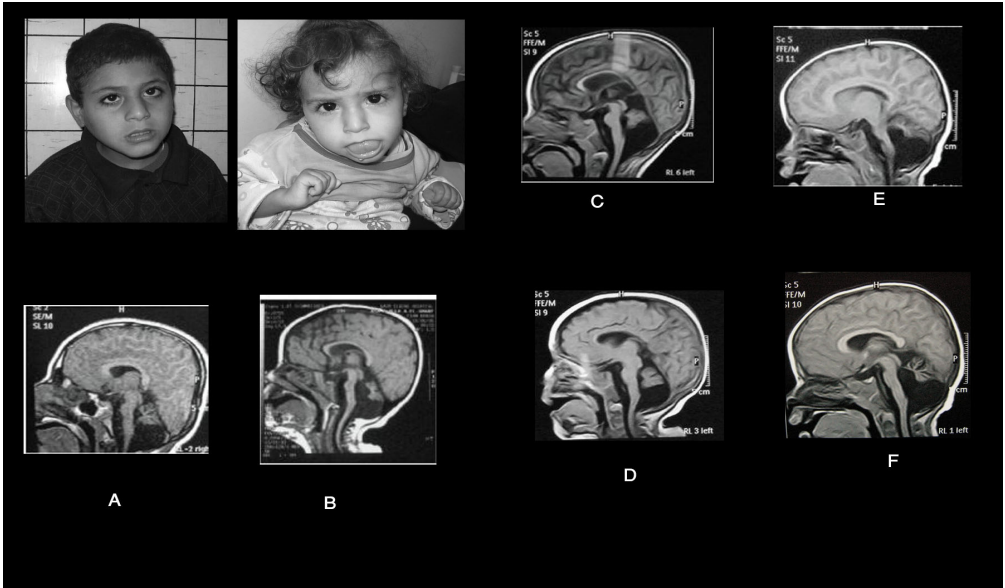


Fig. 2: Pontocerebellar hypoplasia: Case13 & 14; male and female sibs: (A & B) note similar facies and sagittal T1 brain MRI showing cerebellar hypoplasia/atrophy with brain stem hypoplasia and thin corpus callosum. C & D: MRI of 2 male sibs (Case 9 & 10), Sagittal T1 showing cerebellar and brain stem hypoplasia and thin corpus callosum. E & F: male and female sibs (case 11 & 12): sagittal T1 showing cerebellar hypoplasia / atrophy, brain stem hypoplasia and normal corpus callosum.

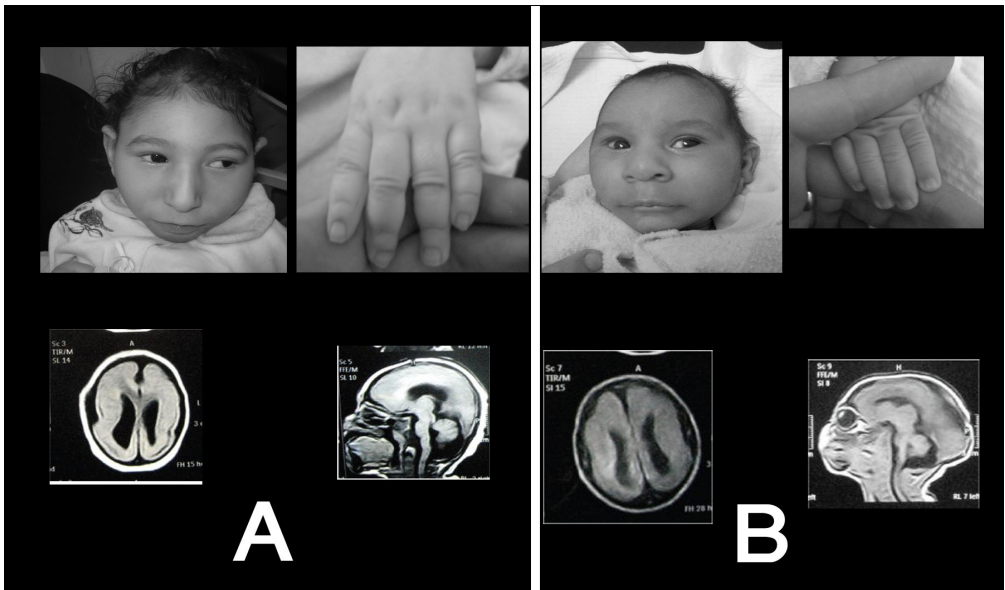


Fig. 3: Case 15 & 16 with lissencephaly cerebellar hypoplasia (LCH). Note close similarity between the 2 sibs (A & B) hypertelorism, upward slanting palpebral fissures, prominent nose, large ears, and arachnodactyly. Axial and sagittal T1 showed agyria, a cell sparse zone, cerebellar hypoplasia, agenesis of corpus callosum and mild hypoplasia of brain stem.

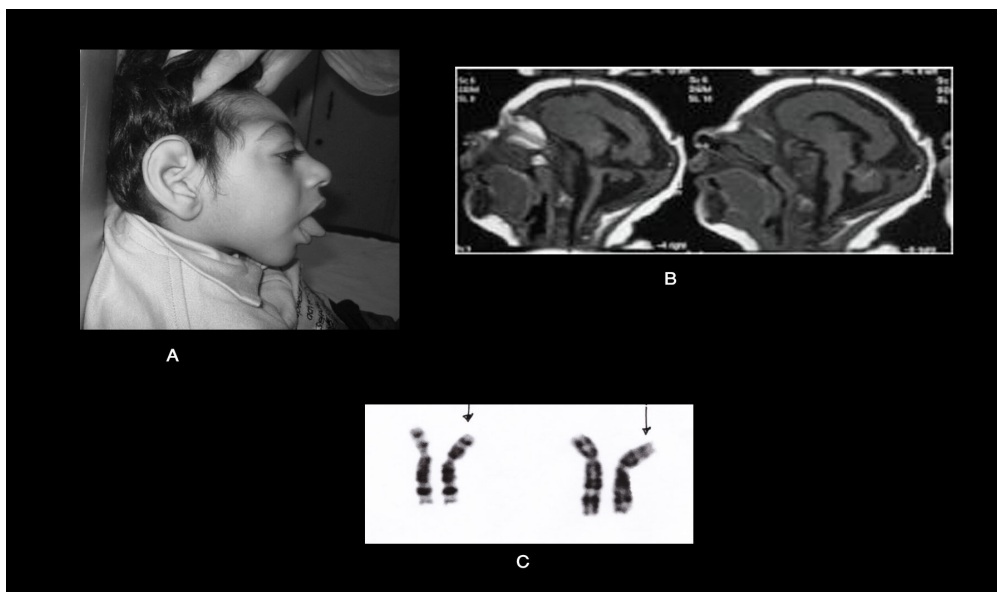


Fig. 4: Case 17 with lissencephaly cerebellar hypoplasia (LCH). Note (A) severe microcephaly, large ears and protruded tongue, (B) Sagittal T1 showing smooth brain with cerebellum and brain stem hypoplasia. (C) Partial karyotyping showing pericentric inversion of chromosome 8.



Fig. 4C: Partial karyotype showing pericentric inversion of chromosome 8.

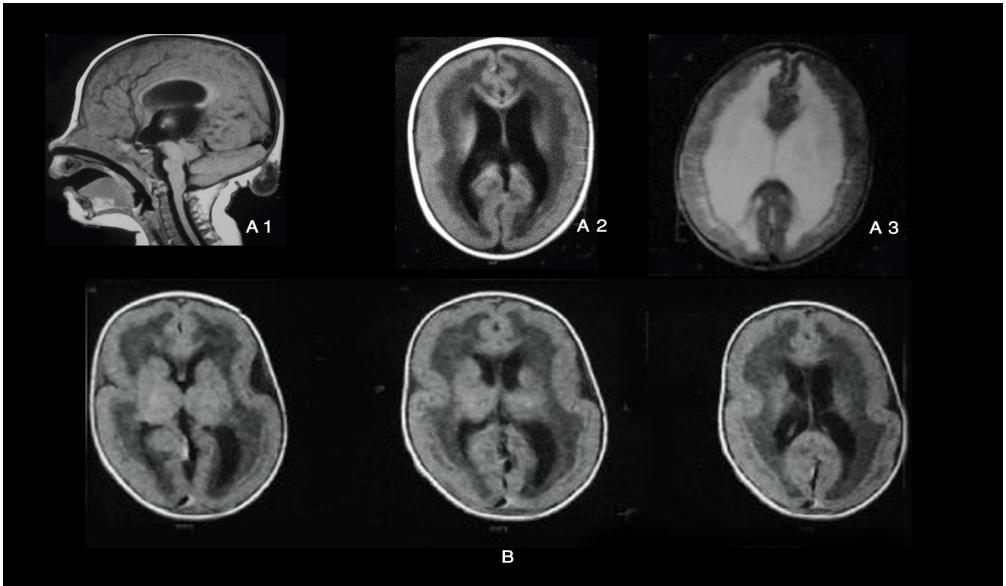


Fig. 5: Cobblestone lissencephaly. A: Case 18; Axial and Sagittal T1 and Axial T2 showing cephalocele (early in life operated upon), agyria , narrow subarachnoid space, abnormal signal of white matter (low on T1 and high on T2), occipital band heterotopia. B: Case 19; Axial T1 showing agyria, low signal of periventricular white matter and occipital band heterotopia.

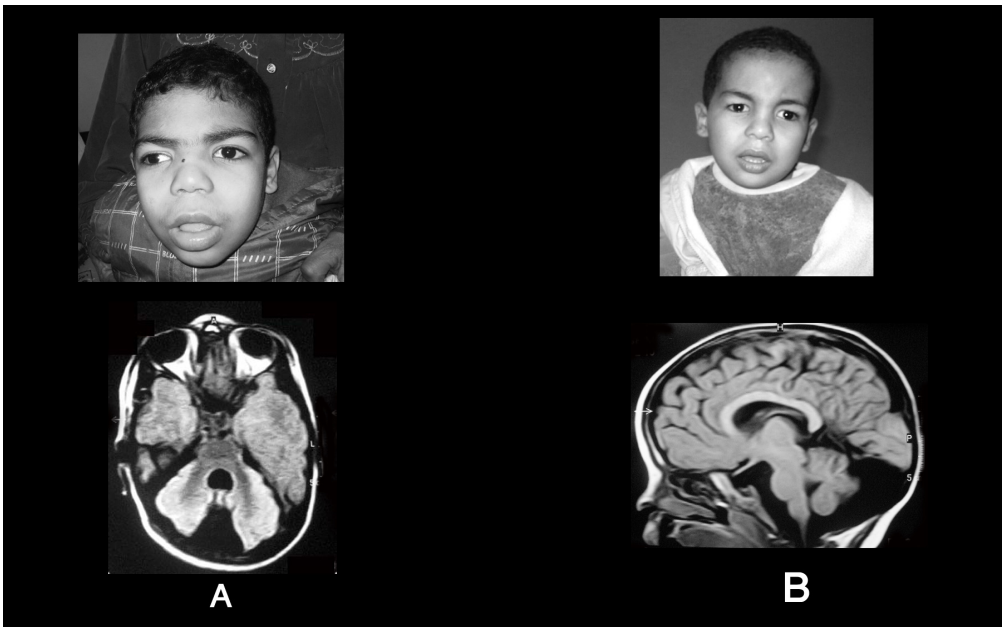


Fig. 6: Two sibs with isolated vermian hypoplasia (case 20 (A) & 21 (B)). Note coarse facies and axial and sagittal T1 showing vermian hypoplasia.

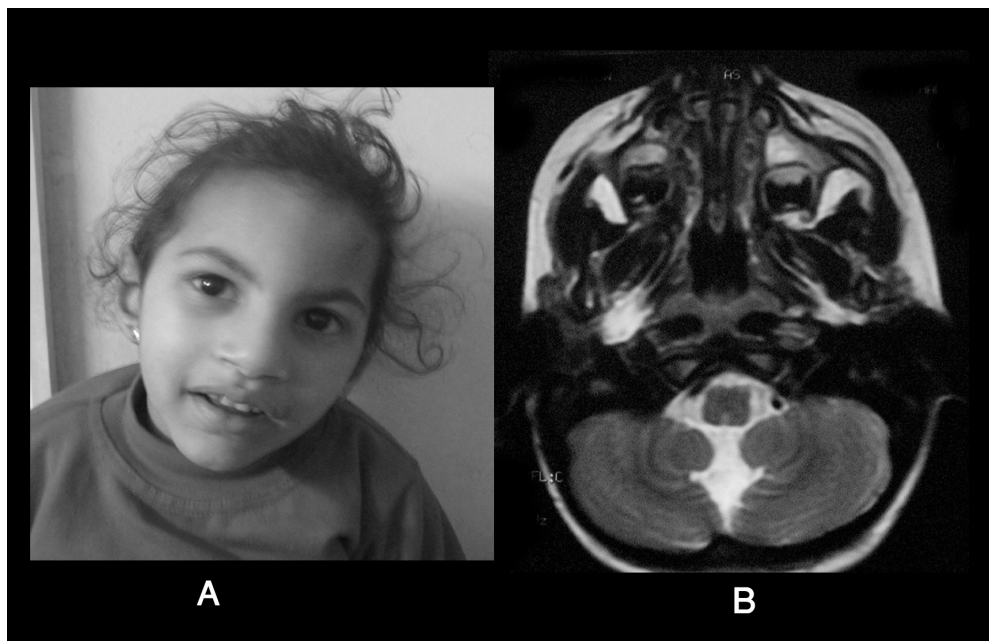


Fig. 7: Case 22 with cri du chat syndrome. A: note specific facies, long face, prominent nasal root, broad nose short philtrum, full lower lip down turned corner of month, large posterior rotated ears B: Axial T1 brain MRI showing cerebellar hypoplasia.




Fig. 7C: Metaphase spread and a karyotype showing del 5p 14.3 – pter.

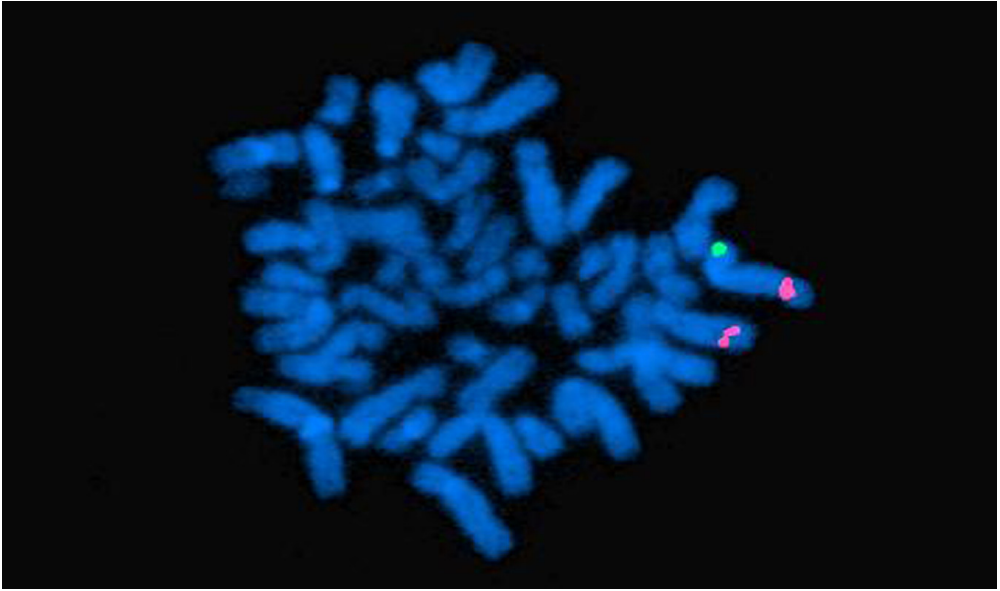


Fig. 7D: FISH analysis using specific probe critical locus of cri du chat syndrome; LSI ERGI (5q31) (spectrum green). Note only one green signal.

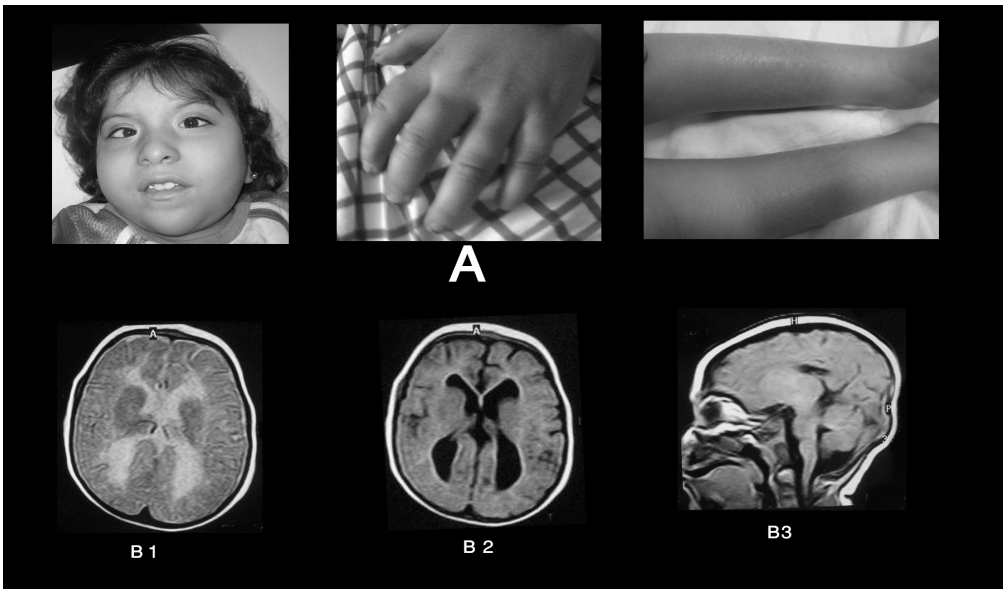


Fig. 8: Case 23 with del 18q21.1 – qter. A: Note the specific facies; fusiform fingers & skin eczema. B: axial T1 and T2 and sagittal T1 brain MRI showing delayed myelination of white matter, poor gray and white matter differentiation and small retro cerebellar cyst (Blak’s pouch).

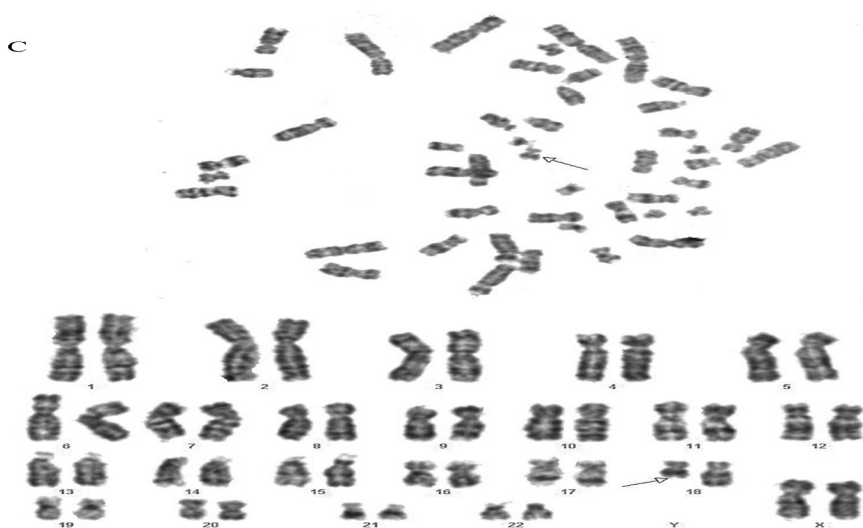


Fig. 8 C: Metaphase spread and kayotype of case 23 showing del 18 q21.1 qter.

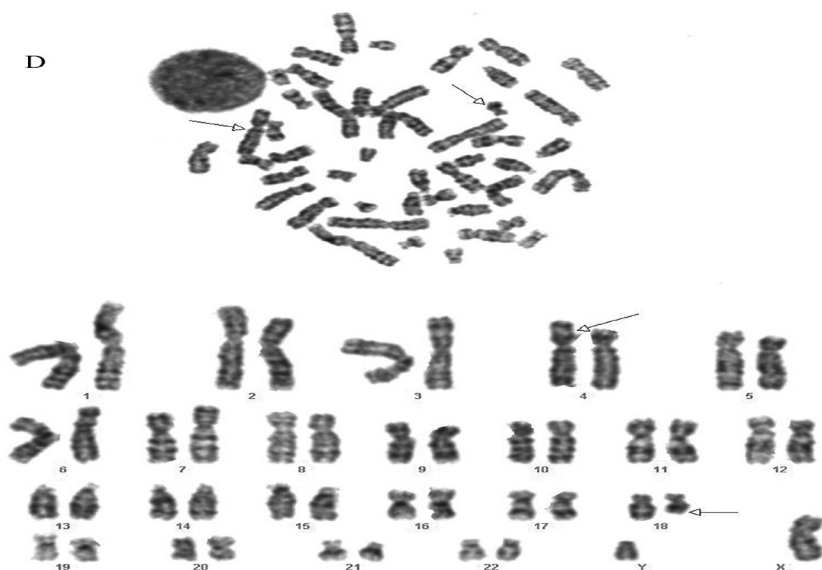


Fig. 8D: Metaphase spread and kayotyping of the father of case 23 with del 18q21.1- qter showing translocation 4;18.

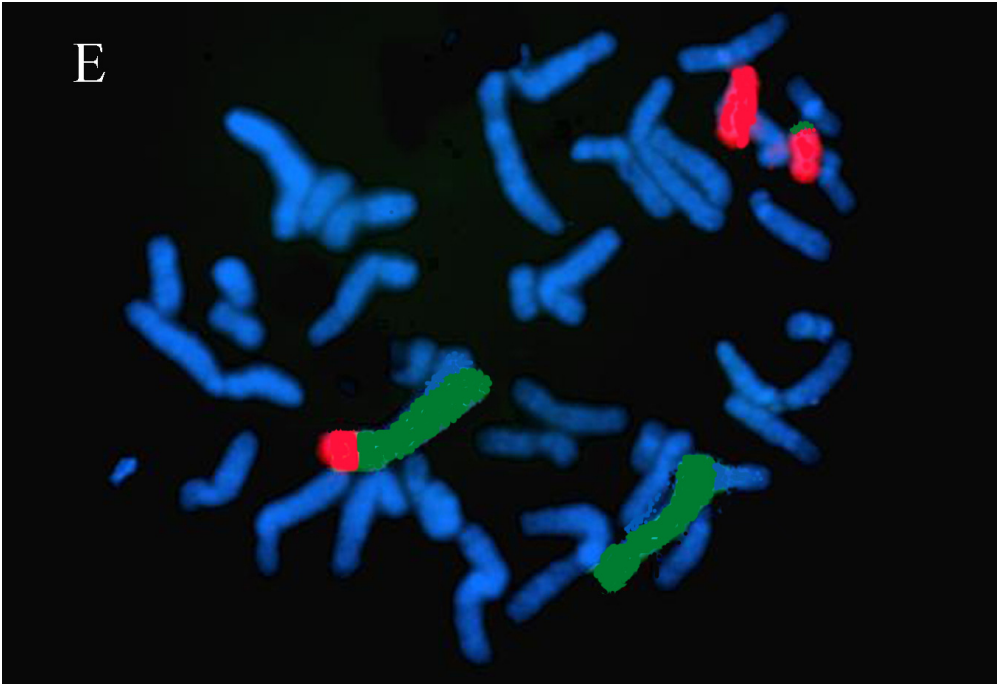


Fig. 8E: FISH for the father of case 23 using whole chromosome painting (WCP) probes for chromosome 4 (spectrum green) and 18 (spectrum red) documenting the translocation (4;18).

Table 1: The clinico-radiological categorization of the studied 23 patients.

Patients	Sex	Consanguinity	Inheritance	Diagnosis
1-8	6 F/ 2M	8/8	AR	JS/ JSRD.
9-14	2F/ 4M	6/6	AR	PCH
15-17	1F/ 2M	2/3	AR/chromosomal	LCH
18-19	1F/1M	2/2	AR	Cobblestone LIS
20-22	1F/ 2M	2/3	XR or AR &chromosomal	CVH
23	F	-	Chromosomal	Retrocerebellar cyst (Blake's pouch)

AR: Autosomal recessive, CVH: Cerebellar vermian hypoplasia F: Female, JS: Joubert syndrome, JSRD: Joubert syndrome related disorders, LCH: Lissencephaly cerebellar hypoplasia, LIS: Lissencephaly, M: Male, PCH: Pontocerebellar hypoplasia, XR: X-linked recessive.

The frequency and percentage of clinical manifestations among studied patients are shown in (Table 2).

Developmental abnormalities of mid and hindbrain

Table 2: The frequency and percentage of clinical manifestations among different categories.

Manifestations	No	%	JSRD 8/23	PCH 6/23	LCH 3/23	Cob LIS 2/23	CVH 2/23	Cri du Chat 1/23	del 18q21.1- qter 1/23
Breathing abnormalities	3	13	3	-	1	-	-	-	-
Feeding problems	8	34.8	-	5	2	-	-	1	-
Autistic behavior	3	13	3	-	-	-	-	-	-
Abnormal tongue movements	6	26.1	5	-	1	-	-	-	-
Microcephaly	11	47.8	-	6	3	-	-	1	1
Encephalocele	1	4.3	-	-	-	1	-	-	-
Dysmorphic/specific facies	16	69.5	5	4	3	-	2	1	1
Postaxial polydactyly	1	4.3	1	-	-	-	-	-	-
Arachnodactyly	2	8.7	-	-	2	-	-	-	-
Foot deformities	1	4.3	-	-	-	-	-	-	Talipes
Fusiform fingers	1	4.3	-	-	-	-	-	-	1
Hypoplasitic nails	1	4.3	-	-	-	-	-	-	1
Abnormal dermatoglyphics	8	34.8	1	2	3	-	-	1	1
Skin changes	2	8.7	1/hemangioma	-	-	-	-	-	Eczema
Accessory nipple	1	4.3	-	-	1	-	-	-	-
Squint	11	47.8	3	3	1	-	2	1	1
Nystagmus	12	52.2	3	2	3	2	2	-	-
Ptosis	3	13	3	-	-	-	-	-	-
Microphthalmia	1	4.3	1	-	-	-	-	-	-
Occulomotor apraxia	7	30.4	7	-	-	-	-	-	-
Optic nerve hypoplasia/ atrophy	6	26.1	1	2	2	-	-	-	1
Coloboma	2	8.7	2	-	-	-	-	-	-
Abnormal VEP/ERG	12	52.2	5	2	2	-	2	-	1
CHD	2	8.7	-	-	1/ASD	-	-	-	1/PDA
Renal anomalies	1	4.3	1/Absent kidney	-	-	-	-	-	-
Seizures	5	21.7	1	1	2	1	-	-	1
Hypotonia	14	60.8	8	-	-	2	2	1	1
Hypertonia/ spasticity	9	39.1	-	6	3	-	-	-	-
Abnormal movements	5	21.7	-	4	1	-	-	-	-

CVH: Cerebellar vermian hypoplasia Cob: cobblestone, JS: Joubert syndrome, JSRD: Joubert syndrome related disorders, LCH: Lissencephaly cerebellar hypoplasia, LIS: Lissencephaly, PCH: Pontocerebellar hypoplasia.

Neuroimaging findings revealed molar tooth sign in 8 patients (34.8%) which is a hallmark of Joubert syndrome and related cerebellar disorders (JSRD),

cerebellar hypoplasia was in 9 patients (39.1%) vermian hypoplasia was in 10 patients (43.8%), cerebellar dysplasia in 2 patients (8.7%), retrocer-

ebellar cyst was in 7 patients (30.4%), Dandy-Walker malformation was in one patient (4.3%) and Neuroimaging findings revealed molar tooth sign in 8 patients (34.8%) which is a hallmark of Joubert syndrome and related cerebellar disorders (JSRD), cerebellar hypoplasia was in 9 patients (39.1%) vermian hypoplasia was in 10 patients (43.8%), cerebellar dysplasia in 2 patients (8.7%), retrocerebellar cyst was in 7 patients (30.4%), Dandy-Walker malformation was in one patient (4.3%) and brain

stem hypoplasia was 9 patients (39.1%). Cerebrum involvement was in the form of cortical malformations in 5 patients (21.7%) and agenesis / hypogenesis of corpus callosum in 10 patients (43.5%). The commonest assigned cortical malformation was lissencephaly (5 patients: 21.7%). One of these patients (4.3%) had in association polymicrogyria and band heterotopia. Comparison of radiological findings among the 6 assigned groups was described in (Table 3).

Table 3: Details radiological findings among the studied 23 patients.

Radiological findings	Diagnosis					
	JS (8 cases)	PCH (6 cases)	CLis (2 cases)	LCH (3 cases)	CVH (3 cases)	Retro cerebellar cyst (1 case)
Abnormal gyral pattern	1	-	2	3	-	-
Corpus callosum affection	1	4	-	3	1	1
Dilated ventricles	1	1	-	1	-	-
Cerebellar hypoplasia or dysplasia	1	6	-	-	-	Mild vermian
Brain stem hypoplasia	1	6	1	3	-	-
Cerebellar vermian hypoplasia	8	6	2	3	3	-
Molar tooth sign	8	-	-	-	-	-
Abnormal superior cerebellar peduncles	8	-	-	-	-	-
High signal white matter	-	-	2	-	-	1

JSRD: Joubert syndrome related disorder; PCH: Pontocerebellar hypoplasia; CLIS: Cobblestone lissencephaly; LCH: lissencephaly cerebellar hypoplasia; CVH: cerebellar vermian hypoplasia
Table 3: Details radiological findings among the studied 23 patients.

Three out of 23 studied patients had chromosomal abnormalities (13 %). Pericentric inversion of chromosome 8 (Figure 4) was found in a patient with severe microcephaly, lissencephaly and cerebellar hypoplasia, deletion of 5p14.3-pter, the critical locus of Cri du chat syndrome was detected in case 22 with vermian hypoplasia (Figure 7C &

D) and deletion of 18q21.1-qter was present in a case 23 (Figure 8 C) with retrocerebellar cyst. Parental karyotyping for these patients were normal except the one with del 18q21.1-qter was due to paternal balanced translocation 4; 18 that was documented by WCP (Figure 8 D & E).

DISCUSSION

Malformations of the posterior fossa constitute a small but important class of brain dysgeneses¹⁹. With the progressive improvement of visualizing posterior fossa structures using MR imaging, cerebellar anomalies are recognized with increasing frequency and it became clear that the cerebellum is important in both cognitive and motor functions.⁴

Here in, we study 23 patients with cerebellar malformations diagnosed by neuroimaging modalities. Based on clinico-radiological features, we classified our patients into: Joubert syndrome and related disorders (JSRD) which were the most common (8 patients: 34.8%), ponto-cerebellar hypoplasia (6 patients: 26.1%), lissencephaly cerebellar hypoplasia (3 patients: 13%), isolated cobblestone lissencephaly (2 patients: 8.7%) isolated vermian hypoplasia (2 patients: 8.7%), Cri du chat syndrome associated with vermian hypoplasia (1 patient: 4.4%) and del 18q21.1-qter associated with retrocerebellar cyst (1 patient: 4.4%). Positive consanguinity was in 86.9% of patients and positive family history was in 56.3% that clarified the putative role of single gene inheritance specifically, autosomal recessive as the most common mode of inheritance among the studied cases. Psychomotor retardation was detected in all patients supporting the important role of cerebellum in controlling the higher cortical function.⁴

Joubert syndrome (JS) and related disorders (JSRD) were diagnosed in 8 patients (34.8% of cases) on the basis of detection of molar tooth sign (MTS), the hallmark of the syndrome. Positive consanguinity was found in 7 out of 8

patients (87.5%) and positive family history of similar affected sib was found in 4 out of 8 patients (50%) supporting the autosomal recessive inheritance of these disorders. None of the described patients with this syndrome had microcephaly. Patients with JS show a characteristic facial appearance; prominent forehead, epicanthal folds, ptosis, strabismus, nystagmus, upturned nose with evident nostrils, open rhomboid mouth, tongue protrusion with rhythmic motions and low-set and tilted ears²¹. Our patients showed most of the characteristic facial appearance of JS. Nystagmus was present in 3 patients (37.5%), ptosis was detected in 3 patients (37.5%) and oculomotor apraxia was observed in 7 cases (87.5%). Abnormal rhythmic tongue movements or protruded tongue was found in 5 patients (62.5 %).

Most children with this disorder have abnormal breathing pattern in the form of hyperpnea intermixed with central apnea especially early in life²¹. Abnormal breathing or history of altered pattern was recorded in 3 cases (37.5%).

The observation of autistic behavior in JS/JSRD was common²², autistic behavior was present in 3 cases (37.5%)²². reported among his studies series with JS, a single case experienced seizures. They mentioned that this finding was not typical for patients with JS however; the presence of associated polymicrogyria could be the possible explanation. Here we found one case suffering from seizures which were controlled with anti-epileptics, although he had no detectable abnormal gyral pattern.

Recently, Zaki et al.²³ classified JSRD into 4 major groups according to different systems involvement: classic

Joubert syndrome (OMIM 213300), COACH (OMIM 216360) (Cerebellar vermis hypoplasia, Oligophrenia, congenital Ataxia, ocular Coloboma and Hepatic fibrosis), CORS (OMIM 608091) (Cerebello-Oculo-Renal Syndrome) and Varadi Papp or OFD VI (OMIM 277170) (Oro-Facio-Digital VI syndrome).

None of our patients have oral manifestations suggestive of oro-facio-digital (OFD) syndrome, although, absent uvula was present in one patient (case 5) and postaxial polydactyly in case 2. Moreover, unspecified congenital heart diseases were reported only in OFD syndrome and not in any other JSRD^{23,24}, Patent foramen ovale with tiny left to right flow jet was assigned in a single patient that wasn't clinically fitted with OFD syndrome.

Retinopathy/ maculopathy was reported in 2 patients (25%), coloboma was in 2 patients (25%), unilateral microphthalmia was present in one patients; ocular findings described with JSRD²⁵. Abnormal VEP and /or ERG were present in 5 patients (62.5%). None of our cases developed abnormal kidneys or liver functions; however, regular monitoring of these functions is recommended until the long term risk of developing renal impairment or hepatic fibrosis can be elucidated especially in patients with eye involvement²². Interestingly, unilateral absent kidney was present in one patient, a finding not previously described with Joubert syndrome or related disorders. Moreover, hemangioma was not a feature of this syndrome, but was observed in as single patient.

Based on Zaki et al.²³ classification, we proposed that the 2 patients with

colobomo (25%) fitted with COACH syndrome as hepatic fibrosis might appear late. The rest of patients were diagnosed as classic Joubert syndrome. None of our patients displayed the criteria of OFD VI or CORS.

Joubert syndrome can be associated with other central nervous system (CNS) malformations such as corpus callosum abnormalities, polymicrogyria, cephalocele, Dandy-Walker malformation and hydrocephalus^{26, 27}. In our series, MTS with Dandy-Walker Malformation was described in one patient (case 5) and a single patient (case 8) had abnormal shallow small gyri especially more obvious in left cerebral hemisphere. Joubert syndrome with polymicrogyria and other brain anomalies including corpus callosal thinning have been reported in patients with AHI1 mutations²⁸. In this study, we also observed clinical heterogeneity among our studied patients that required further molecular analysis to support previous reports of^{24,22} who stated that not only clinical but also genetic heterogeneity explaining the extended spectrum of JSRD.

In this work, we describe 6 patients with pontocerebellar hypoplasia (PCH) (case 9-14) (26.1% of the studied cases). PCH is a heterogeneous group of autosomal recessive disorders characterized by an abnormally small cerebellum and brainstem⁹. All of these patients were derived from consanguineous parents and had positive family history of similar condition supporting the autosomal recessive pattern of inheritance.

There were 5 described subtypes of pontocerebellar hypoplasia (PCH) (type 1-5)^{10, 29}. None of our patients had anterior horn cells affection exclud-

ing PCH1 in them. Microcephaly was present in all cases varied from -3.9 to -5.5SD.

Patient 9 and 10 were male sibs. Both of them had progressive microcephaly (-5.5 and -5.1 S.D, respectively), nystagmus, hypertonia, brisk reflexes and partial seizures. Abnormal movements were not detected among them. Fundus examination showed optic atrophy. Neuroimaging revealed in addition to cerebellar and brain stem affections; dilated lateral ventricles and thin dysplastic corpus callosum. These findings are closely matched with PCH-3. PCH-3 is closely similar to PCH-2 with the added finding of optic atrophy and without extrapyramidal movement disorders.^{30, 31}

Patients 11 and 12 were more likely fitting with PCH-2. They were male and female sibs. The presence of history of feeding difficulties, abnormal movements, and spasticity in association with normal fundus, cerebrum and corpus callosum are characteristic of PCH2.¹⁰

Patients 13 and 14 were male and female sibs, microcephalic (-3.9SD and -4.6SD, respectively) had abnormal movements and hypertonia. Case (13) had a history of recurrent vomiting and feeding difficulties that required gastroscopy. MRI of both cases were closely similar and showed severe hypoplastic cerebellum (both hemispheres and vermis) especially its lower part, hypoplastic brain stem mainly the pons, thin corpus callosum, normal cerebrum. These 2 patients could be categorized as PCH-2, however type 4 could not be excluded as the severity of microcephaly is milder than reported cases with PCH-2.

Furthermore, both patients had hypertrichosis a finding described with PCH-4. Nevertheless, the involvement of the vermis and the absence of hypotonia may rule out type 4.^{2,9} Hopefully in the future, molecular analysis and more gene identifications can be helpful in categorizing and differentiating between various types of PCH.

We also present three patients with lissencephaly and cerebellar hypoplasia, case 15-17. Cases 15 and 16 are female and male sibs derived from consanguineous parents. Both are closely similar in clinical and radiological features. They had severe microcephaly (-7.8 S.D, -5.4 SD, respectively) and specific features in the form of upward slanting narrow palpebral fissures, prominent nasal root, beaked/broad nose, long philtrum, protruded ears, arachnodactyly and prominent heels. The female patient had in addition left accessory nipple, wide spaced nipples, and atrial septal defect detected by echocardiography. Patients had spasticity and intractable seizures. Neuroimaging for these 2 sibs was peculiar and showed agyria grade 1a, subcortical cell sparse zone mainly occipital, dilated lateral ventricles, increased extraxial CSF, hypoplastic both cerebellar hemispheres and vermis, mild brain stem hypoplasia and hypogenesis of corpus callosum. These findings may coincide with LCHf (Lissencephaly cerebellar hypoplasia type f) described by Ross et al.⁶ Authors classified LCH into 5 groups (a-f) based on microcephaly, lissencephaly (grade and gradient), cerebellar, brain stem, corpus callosum and hippocampal involvements. However, the severity of microcephaly and specific features among the 2 sibs can delineate a new autosomal recessive inherited LCH.

Patient 17 was a male, derived from first cousin parents, had severe microcephaly (-12 SD), intractable seizures and agyria with few undulation posterior (gradient b), thin corpus callosum and brain stem hypoplasia. The clinical and radiological features of this patient were unlike the fore mentioned 2 sibs and he didn't fit with any of the category delineated by Ross et al.⁶. Interestingly, chromosomal abnormality in the form of pericentric inversion of chromosome 8 (p11.2q13) was present in this patient. This may point out to a specific locus responsible for this form of LCH which requires more advanced molecular cytogenetics and molecular analysis to be proved.

Isolated cobblestone lissencephaly was assigned in female and male patients (cases 18 and 19). Both patients were derived from consanguineous parents. They had similar clinico-radiological findings. Both had agyria grade Ia, 2a, respectively, narrow subarachnoid space giving picture of cobblestone lissencephaly, occipital band heterotopia, dysplastic cerebellum, mild brain stem hypoplasia and abnormal signal of white matter. In addition patient 18 had history of occipital cephalocele (operated upon) and parieto-occipital polymicrogyria on MRI. Clinically, both were not dysmorphic, except for insignificantly presence of bilateral preauricular tag in patient 19. They had nystagmus, hypotonia, preserved reflexes and generalized tonic seizures. Investigations revealed normal fundus examination, slit lamp, CPK and EMG.

Cobblestone lissencephaly is the second form of lissencephaly, which was originally referred to as type II lissencephaly but is now called cobblestone cortex. It

results when neurons or neuronal precursors migrate out of the developing brain through breaches in the superficial neural basal lamina. In cobblestone lissencephaly the surface of the brain is not necessarily smooth, instead it frequently shows a broad smooth paving, like cobblestones³². Cobblestone lissencephaly is a feature of three distinct disorders; Muscle-eye-brain disease, Fukuyama-type muscular dystrophy and Walker-Warburg syndrome. They are autosomal recessive disorders that encompass congenital muscular dystrophy, ocular malformations and cobblestone lissencephaly^{33,34} reported 3 patients from 2 consanguineous families with cobblestone lissencephaly but without abnormalities in the eye and muscle. They suggested a separate disorder as autosomal recessive isolated cobblestone lissencephaly with normal eye and muscle. The present patients had normal eye and muscle closely resembled those described by Dobyns et al.³⁴ and supported his observation of being a distinctive entity.

Three patients with vermian hypoplasia were assigned in this work (case 20-22). Two affected male sibs (cases 20 and 21) had isolated cerebellar vermian hypoplasia. The two sibs are derived from consanguineous parents. Both had coarse facies that was less manifested in the younger sib (case 21). MRI showed vermian hypoplasia and both cerebellar hemispheres appeared to be within normal size. Cerebellar vermian hypoplasia is either X-linked, autosomal recessive or of uncertain inheritance². We propose X-linked cerebellar hypoplasia as possible diagnoses for these two male sibs because of the close clinical similarity to this category, however; autosomal recessive CVH cannot be ex-

cluded because of positive consanguinity in this family³⁵ identified *oligophrenin 1* (OPHN1) gene mutations on Xq12 in 12% of his series of males with X-linked mental retardation (XL-MR), in association with cerebellar vermian hypoplasia and variable dysmorphic features. Affected individuals with *OPHN1* gene mutations exhibit moderate to severe cognitive impairment with major language and behavioral problems, nystagmus and coarse facies³⁶. Both patients exhibited nystagmus, coarse facies and severe cognitive and language impairment. Furthermore, congenital disorders of glycosylation (CDG) cannot also be ruled out, as vermian hypoplasia and dysmorphic facies were reported with CDG. Accurate categorization of these sibs required advanced genetic studies as screening of isoelectric transferrin to exclude CDG and further molecular analysis of OPHN1 if negative screening is documented.

Patient 22 had del 5p14.3-pter detected by regular cytogenetics studies and confirmed by fluorescent in situ hybridization (FISH). Our patient had specific features of Cri du chat syndrome³⁷. She had history of low birth weight, microcephalic at birth, failure to thrive, abnormal crying and hypotonia. Patient had microcephaly, long face, prominent supraorbital ridges, prominent nasal root, broad nose, short philtrum, full lower lip, down turned corner of mouth, large posterior rotated ears and abnormal dermatoglyphics. Neurologically, patient was hyperactive, has abnormal gait, hypotonia and brisk reflexes. Mild vermian hypoplasia and thin corpus callosum were detected on neuroimaging simulating the neuroradiological findings reported by Tamraz et al.³⁷ and Vialard et al.¹¹. Parental karyotyping

was normal which documented de novo deletion, the most frequent type with negligible recurrent risk. However, the possibility of gonadal mosaicism in one of the parents cannot be excluded, even if no recurrence has been reported.³⁸

Patient 23 had del 18q21.1-qter due to paternal balanced translocation 4;18 documented by WCP. This patient had most of the typical features of 18q-syndrome as mental retardation, short stature (-4SD), microcephaly (-4.2SD), midface hypoplasia, hypertelorism, strabismus, seizures, hypotonia, skin eczema and mild talipes equinovarus³⁹ delineated genotype-phenotype mapping of chromosome 18q deletion. They studied a large series of patients by high resolution array CGH to define the critical region of specific manifestation. Mental retardation was located in 18q21.33 leading to postulation that more distal deletion was not consistently to have mental retardation; interestingly, microcephaly was also located in same critical region (18q21.33). Short stature showed 3 overlapping regions; 18q12.1-q12.3, 18q21.32-q21.33 and 18q22.3-q23. Congenital aural atresia with wide variability of this anomaly was on 18q22.3-qter while cleft palate with or without cleft lip had a proximal critical region located in 18q12.1-q12.3 and a distal region located in 18q22.3-q23. Mid and forefoot deformities was located in 18q22.3-q23. Immunoglobulin A (IgA) deficiency was suspected to be on 18q21.32 however, high number of patients with overlapping deletion showed normal IgA. Other common features as obesity, hyper laxity, strabismus, seizures, behavioral abnormalities and eczema didn't show clear phenotype-genotype correlation. Although the deleted region in our patients overlapped most

of the critical region of the described phenotype; cleft palate, congenital aural atresia and IgA deficiency were not features in the present case. Moreover, our patient had in addition fusiform fingers and hypoplastic nails of 4th and 5th toes. MRI findings in 18q- syndrome were surprisingly uniform in all described patients and showed delayed myelination and poor differentiation of gray and white matter⁴⁰. Diffuse, bilateral symmetrical deep white matter hyperintensity more pronounced in the posterior ventricular regions have been detected in MRI with recently suggested critical region located in 18q22.3-q23⁴¹. Furthermore, poor differentiation of cerebellar gray and white matter, mild atrophic findings, Chiari I malformation, hypoplasia of the pituitary, thinning of corpus callosum and porencephalic cyst have been also reported³⁹. Case 23 had clear delayed myelination of white matter, nevertheless, agenesis of corpus callosum and small retrocerebellar cyst simulating Blake's pouch were assigned in this patient.

The present work emphasizes the importance of MRI brain as an essential etiologic/diagnostic tool and genetic studies in evaluating patients with hind brain anomalies for accurate diagnosis, prognosis and genetic counseling. Advanced molecular techniques as wide genomic scanning and linkage analysis have shed light on the genetic basis of some malformations of the cerebellum. In the future, knowing the causative genes in each brain malformation will allow a molecular biologic classification and provide more concrete information about the risk of recurrence and thus may be helpful in prenatal diagnosis.

REFERENCES

1. Altman NR, Naidich TP, Braffman BH. Posterior fossa malformations. *AJNR Am.J. Neuroradiol.* 1992; 13 (2): 691-724.
2. Parisi MA, Dobyns WB. Human malformations of the midbrain and hindbrain: Review and proposed classification scheme. *Mol.Genet. Metab.* 2003 t; 80 (1-2): 36-53.
3. Niesen CE. Malformations of the posterior fossa: Current perspectives. *Semin. Pediatr.Neurol.* 2002; 9 (4): 320-34.
4. Patel S, Barkovich AJ. Analysis and classification of cerebellar malformations. *AJNR Am.J.Neuroradiol.* 2002; 23 (7): 1074-87.
5. Ramaekers VT, Heimann G, Reul J, Thron A, Jaeken J. Genetic disorders and cerebellar structural abnormalities in childhood. *Brain* 1997; 120 (Pt 10): 1739-51.
6. Ross ME, Swanson K, Dobyns WB. Lissencephaly with cerebellar hypoplasia (LCH): A heterogeneous group of cortical malformations. *Neuropediatrics* 2001; 32 (5): 256-63.
7. Stromland K, Sjogreen L, Miller M, Gillberg C, Wentz E, Johansson M, et al. Mobius sequence--a Swedish multidiscipline study. *Eur.J.Paediatr.Neurol.* 2002; 6 (1): 35-45.
8. Nelson MD, Jr, Maher K, Gilles FH. A different approach to cysts of the posterior fossa. *Pediatr.Radiol.* 2004; 34 (9): 720-32.

9. Boltshauser E. Cerebellum-small brain but large confusion: A review of selected cerebellar malformations and disruptions. *Am.J. Med. Genet. A.* 2004 1; 126 (4): 376-85.
10. Patel MS, Becker LE, Toi A, Armstrong DL, Chitayat D. Severe, fetal-onset form of olivopontocerebellar hypoplasia in three sibs: PCH type 5? *Am.J.Med.Genet.A.* 2006 15; 140 (6): 594-603.
11. Barkovich AJ. *Pediatric Neuroimaging*. 4th ed. Philadelphia: Lippincott Williams & Wilkins; 2005.
12. Vialard F, Robyr R, Hillion Y, Molina Gomes D, Selva J, Ville Y. Dandy-Walker syndrome and corpus callosum agenesis in 5p deletion. *Prenat. Diagn.* 2005; 25 (4): 311-3.
13. Bish JP, Pendyal A, Ding L, Ferrante H, Nguyen V, McDonald McGinn D, et al. Specific cerebellar reductions in children with chromosome 22q11.2 deletion syndrome. *Neurosci.Lett.* 2006 22; 399 (3): 245-8.
14. Imataka G, Yamanouchi H, Arisaka O. Dandy-Walker syndrome and chromosomal abnormalities. *Congenit Anom (Kyoto)* 2007; 47 (4): 113-8.
15. Poot M, Kroes HY, V D Wijst SE, Eleveld MJ, Rooms L, Nievelstein RA, et al. Dandy-Walker complex in a boy with a 5 Mb deletion of region 1q44 due to a paternal t(1;20) (q44;q13.33). *Am.J.Med.Genet. A.* 2007 15; 143 (10): 1038-44.
16. Seabright M. A rapid banding technique for human chromosomes. *Lancet* 1971 30; 2 (7731): 971-2.
17. Yunis JJ. High resolution of human chromosomes. *Science* 1976 26; 191 (4233): 1268-70.
18. Verma RS, Babu A. Tissue culture techniques and chromosomes preparation. In: Verma RS, Babu A, editors. *Human chromosomes: A manual of basic techniques*. 2nd ed.: McGraw-Hill; 1995.
19. Pinkel D, Gray JW, Trask B, van den Engh G, Fuscoe J, van Dekken H. Cytogenetic analysis by in situ hybridization with fluorescently labeled nucleic acid probes. *Cold Spring Harb.Symp. Quant.Biol.* 1986; 51 Pt 1: 151-7.
20. Sarnat HB, Benjamin DR, Siebert JR, Kletter GB, Cheyette SR. Agenesis of the mesencephalon and metencephalon with cerebellar hypoplasia: Putative mutation in the EN2 gene--report of 2 cases in early infancy. *Pediatr.Dev. Pathol.* 2002; 5 (1): 54-68.
21. Maria BL, Boltshauser E, Palmer SC, Tran TX. Clinical features and revised diagnostic criteria in Joubert syndrome. *J.Child Neurol.* 1999; 14 (9): 583,90; discussion 590-1.
22. Louie CM, Gleeson JG. Genetic basis of Joubert syndrome and related disorders of cerebellar development. *Hum.Mol.Genet.* 2005 15;14 Spec No. 2:R235-42.
23. Zaki MS, Abdel Aleem A, Abdel Salam G, Marsh SE, Silhavy JL, Barkovich AJ, et al. The molar tooth sign: A new Joubert syndrome and related cerebellar disorders classification system tested in Egyptian families. *Neurology* 2008 12; 70 (7): 556-65.
24. Chance PF, Cavalier L, Satran D, Pel-

- legirino JE, Koenig M, Dobyns WB. Clinical nosologic and genetic aspects of Joubert and related syndromes. *J.Child Neurol.* 1999; 14 (10): 660, 6; discussion 669-72.
25. Hildebrandt F, Nothwang HG, Vossmerbaumer U, Springer C, Strahm B, Hoppe B, et al. Lack of large, homozygous deletions of the nephronophthisis 1 region in Joubert syndrome type B. APN Study Group. Arbeitsgemeinschaft fur Padiatrische Nephrologie. *Pediatr.Nephrol.* 1998;12 (1):16-9.
26. Maria BL, Quisling RG, Rosainz LC, Yachnis AT, Gitten J, Dede D, et al. Molar tooth sign in Joubert syndrome: Clinical, radiologic and pathologic significance. *J.Child Neurol.* 1999 ;14 (6): 368-76.
27. Valente EM, Silhavy JL, Brancati F, Barrano G, Krishnaswami SR, Castori M, et al. Mutations in CEP290, which encodes a centrosomal protein, cause pleiotropic forms of Joubert syndrome. *Nat.Genet.* 2006; 38 (6): 623-5.
28. Dixon Salazar T, Silhavy JL, Marsh SE, Louie CM, Scott LC, Gururaj A, et al. Mutations in the AHI1 gene, encoding joubertin, cause Joubert syndrome with cortical polymicrogyria. *Am.J.Hum. Genet.* 2004;75 (6): 979-87.
29. Steinlin M, Klein A, Haas Lude K, Zafeiriou D, Strozzi S, Muller T, et al. Pontocerebellar hypoplasia type 2: Variability in clinical and imaging findings. *Eur.J.Paediatr.Neurol.* 2007; 11 (3): 146-52.
30. Zelnik N, Dobyns WB, Forem SL, Kolodny EH. Congenital pontocerebellar atrophy in three patients: Clinical, radiologic and etiologic considerations. *Neuroradiology* 1996; 38 (7): 684-7.
31. Rajab A, Mochida GH, Hill A, Ganesh V, Bodell A, Riaz A, et al. A novel form of pontocerebellar hypoplasia maps to chromosome 7q11-21. *Neurology* 2003 27; 60 (10):1664-7.
32. Barkovich AJ, Kuzniecky RI, Jackson GD, Guerrini R, Dobyns WB. A developmental and genetic classification for malformations of cortical development. *Neurology* 2005 27; 65 (12):1873-87.
33. Barkovich AJ, Kuzniecky RI, Dobyns WB, Jackson GD, Becker LE, Evrard P. A classification scheme for malformations of cortical development. *Neuropediatrics* 1996; 27 (2): 59-63.
34. Dobyns WB, Patton MA, Stratton RF, Mastrobattista JM, Blanton SH, Northrup H. Cobblestone lissencephaly with normal eyes and muscle. *Neuropediatrics* 1996; 27 (2): 70-5.
35. Zanni G, Saillour Y, Nagara M, Bilhuart P, Castelnau L, Moraine C, et al. Oligophrenin 1 mutations frequently cause X-linked mental retardation with cerebellar hypoplasia. *Neurology* 2005 8; 65 (9): 1364-9.
36. Chabrol B, Girard N, N'Guyen K, Gerard A, Carlier M, Villard L, et al. Delineation of the clinical phenotype associated with OPHN1 mutations based on the clinical and neuropsychological evaluation of three families. *Am.J.Med. Genet.A.* 2005 1; 138 (4): 314-7.
37. Tamraz J, Rethoré MO, Lejeune J, Outin C, Goepel R, Stievenart JL, et al. Morphométrie encéphalique en IRM dans la maladie du chat. A propos

- de sept patients, avec revue de la littérature. Association pour la recherche sur la sclérose en plaques. [Brain morphometry using MRI in Cri-du-Chat Syndrome. Report of seven cases with review of the literature]. *Ann.Genet.* 1993; 36 (2): 75-87.
38. Mainardi PC, Pastore G, Castronovo C, Godi M, Guala A, Tamiazzo S, et al. The natural history of Cri du Chat Syndrome. A report from the Italian Register. *Eur.J.Med. Genet.* 2006; 49 (5): 363-83.
39. Feenstra I, Vissers LE, Orsel M, van Kessel AG, Brunner HG, Veltman JA, et al. Genotype-phenotype mapping of chromosome 18q deletions by high-resolution array CGH: An update of the phenotypic map. *Am.J.Med.Genet.A.* 2007 15; 143 (16): 1858-67.
40. Linnankivi TT, Autti TH, Pihko SH, Somer MS, Tienari PJ, Wirtavuori KO, et al. 18q-syndrome: Brain MRI shows poor differentiation of gray and white matter on T2-weighted images. *J.Magn.Reson.Imaging* 2003; 18 (4): 414-9.
41. Linnankivi T, Tienari P, Somer M, Kahkonen M, Lonnqvist T, Valanne L, et al. 18q deletions: Clinical, molecular and brain MRI findings of 14 individuals. *Am.J.Med.Genet.A.* 2006 15; 140 (4): 331-9.