

## MURCS Association: a Case Report

Rabah M. Shawky; Iman M. Talaat, Ihab Z. El-Hakim, Solaf M. Elsayed

Pediatric Department, Ain Shams University

### ABSTRACT

MURCS association is a rare developmental disorder that affects females. The acronym MURCS stands for **M**ullerian, **R**enal, **C**ervicothoracic **S**omite abnormalities. It appears to occur randomly (Sporadic) with a frequency of 1 in 50,000 females. In this paper, we present a two-year-old girl with typical features of this syndrome in association with right deviation of anorectal canal, subglottic stenosis and unilateral oblique inguinal hernia.

#### Key Words:

MURCS, congenital torticollis, anorectal-canal, abnormalities.

#### Corresponding Author:

Rabah M. Shawky

E-mail: rabahshawky@hotmail.com

### CASE REPORT

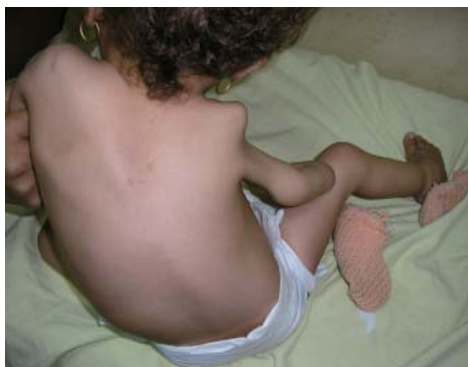Our patient is a 2 year old female, born to remote consanguineous parents from Upper Egypt. She is the fourth in order out of five offspring. She was born by normal vaginal delivery. The antenatal period showed first trimester vaginal bleeding, while the postnatal period was uncomplicated. During infancy, the child presented with the skeletal deformities, recurrent urinary tract infections, right oblique inguinal hernia, recurrent fractures of right humerus and failure to thrive. She had normal mental development, while motor development was affected by the multiple deformities.

On examination, her weight was 8kg (<-4 SD), height was 71.4cm (<-4 SD, proportionate), weight for height at the 50th percentile and head circumference

was 46.4cm (25<sup>th</sup> percentile). The child had hemifacial microsomia, congenital torticollis to the right side with short neck, low posterior hairline and congenital scoliosis with a small hemangioma over the back in the midline. There was an elevation of left shoulder blade. Left upper limb was normal. The right upper limb showed limited movement at shoulder joint, short clavicle, hypoplastic arm, immobile elbow joint, radial club hand, absent thumb, hypoplastic index and syndactyly between index and middle fingers. Both lower limbs showed talipes and club deformity, Figures (1-3). Subglottic stenosis was discovered when difficult intubation was observed during operative correction of the left vesicoureteric reflux. Chest, heart and abdominal examinations were free.



**Fig. 1:** MURCS association with hemifacial microsomia and congenital torticollus.

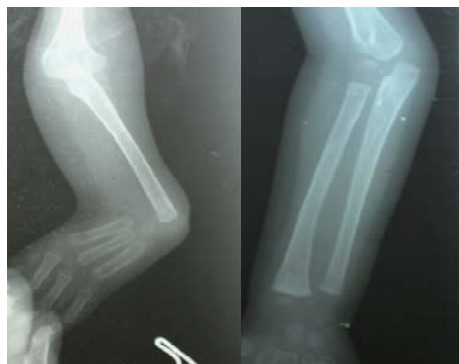

**Fig. 2:** MURCS association with scoliosis, low hair line, elevation of left shoulder blade and hemangioma over back.



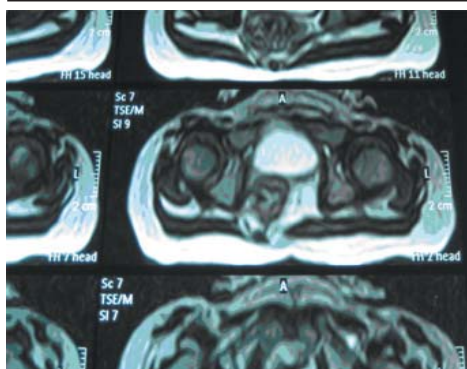
**Fig. 3:** MURCS association with radial club hand, absent thumb, hypoplastic index in addition, syndactyly between index and middle fingers.

Plain X ray of vertebrae showed hemivertebrae and fusion of cervical and dorsal vertebrae with supernumerary ribs and fusion on the right side. Right upper limb showed absent head of humerus, deformed humerus and ulna with malalignment of ulna, absent radius, one carpal bone (Versus 3 on left side), 3 metacarpal bones, absent thumb and rudimentary index finger phalanges, Figure(4).

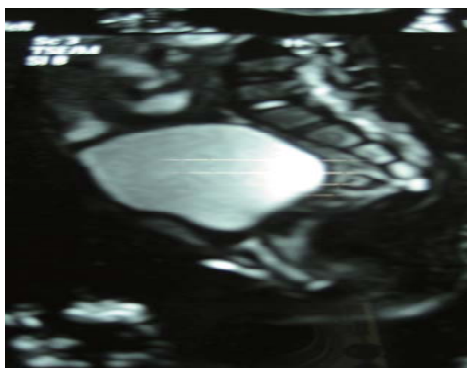


**Fig. 4:** Plain Xray shows right ulna with malalignment, absent radius, one carpal bone (Versus 3 on left side), 3 metacarpal bones, absent thumb and rudimentary index finger phalanges.

Real time abdominal sonography showed non-visualized right kidney and minimal pelvicalcyaeal dilatation. Voiding cystourethrogram showed left vesicoureteric reflux. Renal scan showed non-visualization of right kidney, with adequate function of left kidney with patent urine drainage and fourth degree vesicoureteric reflux. Real time pelvic sonography and pelvic MRI showed absent uterus, fallopian tubes, absent image of both ovaries, partial agenesis of the left levator ani muscles with right deviation of anorectal canal, Figures (5, 6). Echo cardiography and karyotyping were normal.



**Fig. 5:** MRI pelvis shows right deviation of anorectal canal and absent image of both ovaries.



**Fig. 6:** MRI pelvis shows absent image of the uterus.

## DISCUSSION

MURCS association is emerging as the second most frequent cause of primary amenorrhoea after Turner syndrome.<sup>1</sup> The realization that mullerian aplasia or hypoplasia sometimes occurs in association with a specific constellation of other congenital anomalies led to the description of the MURCS association<sup>2</sup> by Duncan in 1979.<sup>3</sup> It is postulated that the association stems from alteration of the blastemas of the upper somites, arm buds and pronephric ducts, which have an intimate relationship at the end of the fourth week of fetal life.<sup>4</sup> Some believe that an unidentified teratogen

may cause the initial defect. Support for this concept is provided by a patient exposed to thalidomide at the fetal age of 27-29 days.<sup>5</sup>

In almost all cases, affected females exhibit mullerian aplasia. The fallopian tubes may be rudimentary or absent. In most cases, the initial symptom is primary amenorrhoea and infertility but they experience normal secondary sexual development.<sup>2,6,7</sup> In our patient, the uterus, fallopian tubes and both ovaries were absent and the association of skeletal anomalies facilitated the early diagnosis.

The skeletal malformations reported included vertebral (Cervical and the upper thoracic vertebrae) dysplasia, may be missing or fused causing shortness of neck, limited neck motion and an abnormal low hair line (Klippel-Feil syndrome). In addition, affected females may exhibit dysplastic ribs, scoliosis, elevation of the shoulder blade (Scapulae) due to the scapula's failure to move into the appropriate position during fetal development (Sprengel deformity); and/or abnormalities of the hands and/or arms and unusually short stature.<sup>1</sup> Almost all these findings were found in our patient.

Patients also exhibit renal abnormalities, such as unilateral renal agenesis, and/or an ectopic kidney, increased susceptibility to urinary tract infections and/or nephrolithiasis.<sup>2,8</sup> Our patient had absent right kidney and left vesicoureteric reflux.

In rare cases, females with MURCS association may have additional physical abnormalities. These may include craniofacial malformations

(Micrognathia and cleft lip and palate), malformations of the gastrointestinal tract, unilateral adrenal agenesis, unilateral ovarian agenesis and/or ovarian, hypothalamic and pituitary dysfunction<sup>1,6,7</sup>, malformations of the central nervous system<sup>9</sup>, cardiovascular and pulmonary malformations<sup>9</sup>, suggesting a multisystem involvement.<sup>2</sup> None of these anomalies were present in our patient.

Most cases like our case appear to be sporadic, nevertheless there are some reports of families in which siblings displayed uterovaginal abnormalities of the MURCS association.<sup>1,6,10</sup> Therefore, the MURCS association may be described as a polytopic field defect of multiple etiologies.<sup>2</sup> However, the evidence has not yet been shown indicating that MURCS association may be inherited as a genetic trait.<sup>1</sup> The prognosis of each case varies and is probably dependent on the extent and severity of renal abnormalities.<sup>2</sup>

The association primarily affects females, although Wellesley and Slaney<sup>11</sup> reported a possible male case. He had experienced many urinary tract infections and was shown to have a right dysplastic kidney and left renal agenesis. There was fusion of C6-T8 with multiple deformities of neural arches. In addition, there were deformed ribs arising from C7. The testes were small and the vasa deferentia and epididymy were hypoplastic. There are reports hypothesizing this condition in males characterized by non obstructive azospermia in the place of uterine malformations.<sup>9</sup>

Differential diagnosis of our case should include VACTERL association which

is a rare disorder that occurs equally among males and females. VACTERL is an acronym that stands for (V)ertebral dysgenesis from the middle to the lower portion of spinal column, (A)nal atresia, (C)ardiac defects, (T)racheo (E)sophageal fistula, (R)enal anomalies, radial dysplasia, and other (L)imb defects. Occasionally, other abnormalities may occur in association, such as improper development of the vagina and/or uterus in affected females.<sup>1</sup>

Orstavik et al.<sup>12</sup> reported a female infant with overlapping features of VATER and MURCS associations (Vertebral and rib anomalies, renal dysplasia, anal atresia, a double blind vagina) as well as hydrocephalus secondary to aqueduct stenosis.

Also, David et al.<sup>13</sup> reported a child with overlapping features of MURCS association, Nager acrofacial dysostosis and VACTERL association. There was bilateral aplasia of the thumbs, mandibulofacial dysostosis, left pulmonary agenesis, KlippelFeil anomaly and vertebral synostoses.

Other differential diagnosis includes Mayer Rokitansky Kauster Hauser (MRKH) syndrome which is a rare disorder defined as karyotypical 46, XX females with vaginal agenesis, uterine malformations in association with renal or skeletal anomalies.<sup>14,15</sup> However, MURCS association is named when non random combination of the entire malformations (Skeletal, renal, cervicothoracic) are formed together.<sup>15,16</sup> Strubbe et al.<sup>17</sup>, recognizing additional anomalies, designated typical and atypical forms of (MRKH) syndrome. The typical form consisted of patients

with only symmetrical uterine buds and fallopian tubes, while the atypical form included patients with asymmetrical uterine buds or abnormally developed fallopian tubes.

MRKH syndrome has been associated with Klippel-Feil anomaly (It is characterized by missing and/or fusion of cervical vertebrae). As a result, the neck may be abnormally short with restricted movement and abnormally low posterior hairline.<sup>1</sup> This combination of features of both syndromes is classified as the MURCS association.<sup>15</sup> Strubbe et al.<sup>17</sup> noted in 1992 that among the atypical MRKH patients, 10 (19.2%) had corresponding scoliosis, and 14 (26.9%) also had KF anomaly, of which 10 of the 14 met criteria for the MURCS association.

In conclusion, the diagnosis of MURCS association may be confirmed when mullerian aplasia is found to occur in association with absence and/or ectopia of the kidneys, abnormalities of upper vertebrae in the spinal column, and/or malformations of the ribs and/or arms.<sup>1</sup> The association with subglottic stenosis and deviation of anorectal canal were not reported in literature. This emphasizes the fact that a thorough screening for associated traits should be undertaken in all developmental disorders.

## REFERENCES

1. Shakir S, Warady BA. MURCS association. In: The National Organization for Rare Diseases, editor. *In-depth guide to rare diseases*. Philadelphia: Lippincott Williams & Wilkins; 2003: 695.
2. Mahajan P, Kher A, Khungar A, Bhat M, Sanklecha M, Bharucha BA. MURCS association--a review of 7 cases. *J. Postgrad. Med.* 1992 Jul-Sep; 38(3): 109-11.
3. Gunsar C, Genc A, Sencan A, Daglar Z, Alparslan O, Mir E. MURCS association and rectovestibular fistula: Case report of a patient treated with one-stage posterior sagittal anorectoplasty and sigmoid loop vaginoplasty. *J. Pediatr. Surg.* 2003 Feb; 38(2): 262-4.
4. Duncan PA, Shapiro LR. MURCS and VATER associations: Vertebral and genitourinary malformations with distinct embryologic pathogenetic mechanisms. *Teratology* 1979; 19: 24A.
5. Hoffmann W, Grospietsch G, Kuhn W. Thalidomide and female genital malformations. *Lancet* 1976 Oct 9; 2 (7989): 794.
6. Mendez JP, Ulloa Aguirre A, Sanchez FJ, Mutchinick O, Perez Palacios G. Endocrine evaluation in a patient with MURCS association and ovarian agenesis. *Eur. J. Obstet. Gynecol. Reprod. Biol.* 1986 Jul; 22(3): 161-9.
7. Pablo Mendez J, Orozco M, Ivan Ruiz A, Orozco E, Diaz L. MURCS association and hypothalamic anovulation. *Rev. Invest. Clin.* 1992 Jan-Mar; 44(1): 115-21.
8. McKusick VA. *Mendelian inheritance in man*. 8th ed. Baltimore, MD: Johns Hopkins University Press; 1988.
9. Balasubramanian S, Muralinath S, Shivbalan S, Sripathi V, Shivakumar S. MURCS association. *Indian J. Pediatr.* 2004 Jul; 71(7): 653-4.

10. Winter JS, Kohn G, Mellman WJ, Wagner S. A familial syndrome of renal, genital, and middle ear anomalies. *J. Pediatr.* 1968 Jan; 72(1): 88-93.
11. Wellesley DG, Slaney SF. MURCS in a male? *J. Med. Genet.* 1995 Apr; 32(4): 314-5.
12. Orstavik KH, Steen Johnsen J, Foerster A, Fjeld T, Skullerud K, Lie SO. VACTERL or MURCS association in a girl with neurenteric cyst and identical thoracic malformations in the father: A case of gonosomal mosaicism? *Am. J. Med. Genet.* 1992 Aug 1;43(6): 1035-8.
13. David A, Mercier J, Verloes A. Child with manifestations of Nager acrofacial dysostosis, and the MURCS, VACTERL, and pulmonary agenesis associations: Complex defect of blastogenesis? *Am. J. Med. Genet.* 1996 Mar 1; 62(1): 1-5.
14. Griffin JE, Edwards C, Madden JD, Harrod MJ, Wilson JD. Congenital absence of the vagina. The Mayer-Rokitansky-Kuster-Hauser syndrome. *Ann. Intern. Med.* 1976 Aug; 85(2): 224-36.
15. Fisher K, Esham RH, Thorneycroft I. Scoliosis associated with typical Mayer-Rokitansky-Kuster-Hauser syndrome. *South. Med. J.* 2000 Feb; 93(2): 243-6.
16. Hensle TW, Kennedy WA. Abnormalities of the female genital tract. In: O'Neill JAJ, Rowe MI, Grosfeld JL, Fonkalsrud EW, Coran AG, editors. *Pediatric surgery*. 5th ed. St. Louis, MO: Mosby; 1998. p. 1819-33.
17. Strubbe EH, Lemmens JA, Thijn CJ, Willemsen WN, van Toor BS. Spinal abnormalities and the atypical form of the Mayer-Rokitansky-Kuster-Hauser syndrome. *Skeletal Radiol.* 1992; 21(7): 459-62.