


HOSTED BY



ELSEVIER

Contents lists available at ScienceDirect

The Egyptian Journal of Medical Human Genetics

journal homepage: www.sciencedirect.com

Case Report

First report of microcephaly-capillary malformations syndrome in Russia

Nataliya S. Demikova^{a,*}, Victoria S. Kakaulina^b, Nataliya L. Pechatnikova^b, Nina A. Polyakova^b, Ekaterina Y. Zakharova^c, Tatyana D. Krylova^c, Marina V. Zubkova^d^aScientific Research Clinical Institute of Pediatrics named Yu. E. Veltishchev of the Pirogov Russian National Research Medical University, Moscow, Russia^bMorozov Children's Municipal Clinical Hospital of the Moscow City Health Department, Moscow, Russia^cResearch Center for Medical Genetic, Moscow, Russia^dRussian Medical Academy Continuous Professional Education, Moscow, Russia

ARTICLE INFO

Article history:

Received 8 July 2017

Accepted 22 August 2017

Available online 1 September 2017

Keywords:

Microcephaly

Capillary malformations

Epilepsy

Deep developmental delay

STAMPB gene

ABSTRACT

Background: Microcephaly-capillary malformation (MIC-CAP) syndrome is a newly described autosomal recessive syndrome characterized by microcephaly, multiple cutaneous capillary malformations, intractable epilepsy and profound developmental delay. We present the first description of MIC-CAP syndrome in Russia.**Patient:** We describe a 6-month-old girl with severe congenital microcephaly, intractable epilepsy (infantile spasms), multiple cutaneous capillary malformations and facial abnormalities. Genetic studies revealed the presence of new *STAMPB* gene mutations in the compound heterozygous state: c.273delA and the intron replacement c.204-5 C > G.**Conclusions:** This report presents a case of MIC-CAP syndrome with earlier unreported new mutations of the *STAMPB* gene.© 2017 Ain Shams University. Production and hosting by Elsevier B.V. This is an open access article under the CC BY-NC-ND license (<http://creativecommons.org/licenses/by-nc-nd/4.0/>).

1. Introduction

Microcephaly-capillary malformations (MIC-CAP) syndrome is a newly described syndrome with an autosomal recessive mode of inheritance. The primary manifestations of the syndrome are congenital microcephaly, intractable epilepsy, multiple cutaneous capillary malformations, facial abnormalities and substantial delays in psychomotor development. This syndrome was first described by Carter MT et al. in 2011 [1]. Currently, there are 14 patients known to have MIC-CAP syndrome. Mutations in the *STAMPB* gene responsible for disease development have been identified in these patients. This paper presents the first report of MIC-CAP syndrome in Russia.

2. Clinical report

Our patient is a 6-month-old girl born from the fourth pregnancy to unrelated healthy Russian parents. The couple's first pregnancy ended in a medical abortion, the second pregnancy ended in a miscarriage at 6 weeks, and a healthy boy was born from their third pregnancy. The parents' fourth pregnancy was complicated by a threatened miscarriage at 20 weeks of gestation. Intrauterine

growth retardation was diagnosed at 30 weeks of gestation. A normal vaginal delivery occurred at 38 weeks of gestation. Apgar scores for the infant were 8 at 1 min and 9 at 5 min. Her birth weight was 2550 g (below 15th percentile), the birth length was 48 cm (below 50th percentile), and the head circumference was 30 cm (below 3rd percentile). At birth, the girl was noted to have multiple flat vascular stains on the trunk and on the extremities. She was discharged from the hospital 5 days after birth. The girl started to hold her head up at the age of 1 month, started to roll over at 3 months, and did not sit up or crawl.

At 1 month of life, the infant showed failure to thrive with frequent vomiting. At 2 months, she developed paroxysmal events consisting of a sudden stiffening of the body with arms and head bending forward for a second (infantile spasms). At the same age, she became less emotional, she stopped looking after objects and her head control became worse. At 4 months of life, the frequency of epileptic seizures increased. The girl stopped holding her head up, stopped fixing her eyes on objects and stopped smiling.

At 6 months, the girl was admitted to our hospital. On admission, the child's condition was critical due to neurological symptoms and frequent epileptic seizures. The following phenotypic features were observed: hypertelorism, a wide nasal bridge, a short nose, thin lips with drooping mouth corners, a long philtrum, gum hyperplasia, low-set ears, a short neck, short fingers due to hypoplasia of distal phalanges, hypoplastic nails and toe malposi-

Peer review under responsibility of Ain Shams University.

* Corresponding author.

E-mail address: ns_d@rambler.ru (N.S. Demikova).<http://dx.doi.org/10.1016/j.ejmhg.2017.08.011>

1110-8630/© 2017 Ain Shams University. Production and hosting by Elsevier B.V.

This is an open access article under the CC BY-NC-ND license (<http://creativecommons.org/licenses/by-nc-nd/4.0/>).

tion on feet. Her head circumference was 35 cm (4 SD below the mean for her age). Her hair was sparse and had an unusual pattern of growth with long hair along the sagittal suture forming a “Mohawk” (Fig. 1). Multiple flat capillary malformations of irregular shape, measuring 4–15 mm in diameter, were noted on the scalp, the skin of the trunk and the extremities (Fig. 2). The child was seriously retarded in psychomotor development: unable to hold her head, roll, or sit without support. She had roving eye movements without fixation, myoclonus of eyelids, bulbar syndrome, and spastic tetraparesis. On examination, epileptic seizures in the form of tonic spasms and oculotonic seizures were observed.

Considering the observed features, diagnosis of MIC-CAP syndrome was suspected.

A CT brain scan at the age of 3.5 months showed the growing size of the outer cerebrospinal fluid spaces, which can indicate an increase in cortical atrophy.

Brain MRI, performed at the age of 5 months, revealed diffuse cortical atrophy, atrophic ventriculomegaly, and a delay in white matter myelination (Fig. 3).

An EEG showed abnormally slow background activity, multifocal epileptiform spike-and-wave activity, and a burst suppression pattern. At the age of 5 months valproic acid was prescribed in dose 40 mg for each kg of body weight per day, but the frequency of epileptic seizures did not change.

Her blood amino acids and acyl carnitines, urine organic acids, lactate level, and TORCH titers were normal. ECG and abdominal ultrasound examination were unremarkable. Her karyotype was identified as normal (46,XX).

To establish the genetic cause of MIC-CAP syndrome, we performed a search of mutations by means of direct automated sequencing of the gene responsible for the disease. Two mutations were observed in our patient. One mutation was the heterozygous deletion c.273delA, leading to a frameshift and stop codon formation in the next triplet.

This deletion is probably highly pathogenic, although it is not described in the international HGMD database or polymorphisms database (dbSNP). The intron replacement c.204-5 C > G in the heterozygous state was also detected in our patient. This intron replacement has not been described in the international HGMD database, but according to the data of Human Splicing Finder pathogenicity program, it can be a splice site mutation and can be considered to be pathogenic. Thus, the child’s mutations are in the compound heterozygous state, which results in the formation of a MIC-CAP syndrome phenotype.

3. Discussion

Since this disease has been described quite recently, and there are only 14 published cases to date, we want to focus on the characteristics of these cases.

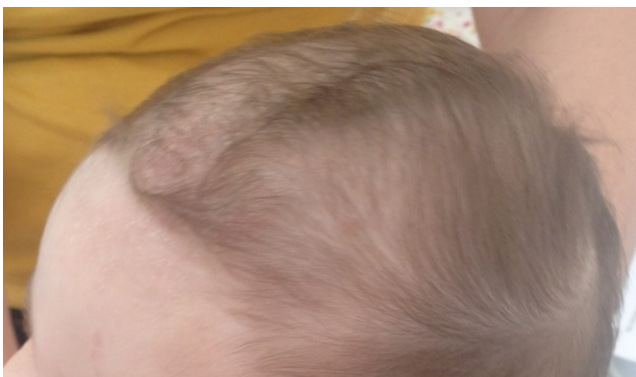

Fig. 1. Note unusual hair growth into a “Mohawk” pattern.

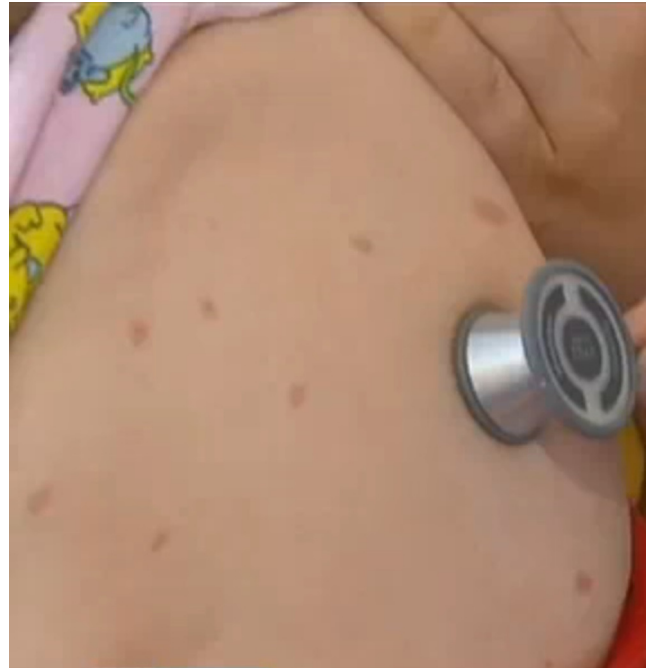

Fig. 2. The multiple capillary malformations on the trunk.

The first publication of Canadian pediatricians described two boys from unrelated families who had similar clinical manifestations [1]. A unique feature of both children was the presence of congenital multiple randomly placed red spots (“port-wine stains”) on the skin, which were the result of abnormal capillary development (or capillary malformations). Both patients had progressive microcephaly, neonatal resistant seizures, psychomotor retardation, similar craniofacial anomalies, short fingers, and toes with nail hypoplasia. Brain MRI detected diffuse cortical atrophy, thinning of the corpus callosum, and delayed myelination of the white matter of the brain in both children. Such a high level of similarities of the phenotypic manifestations in two patients allowed the authors to classify this condition as a new syndrome. However, the cause of the syndrome was not clear.

The other case reports from France and the United States appeared almost simultaneously in the same year. Isidor B. et al. described the third case with similar symptoms in a girl who had been observed for 5 years [2]. Mirzaa G.M. et al. from the United States reported three more cases of the disease from two families [3]. As there were two children with the same disease within one family, autosomal recessive inheritance of the disease was assumed. The syndrome was called microcephaly-capillary malformation syndrome (MIC-CAP, OMIM 614261).

In all cases, the children showed congenital microcephaly and multiple capillary malformations on the skin of the trunk, head and extremities, which increased in size with the growth of the child. The onset of epileptic seizures in the majority of cases occurred in the neonatal period. Epileptic seizures were polymorphic (focal, tonic, hemiclonic, secondary generalized seizures, infantile spasms) and were resistant to anticonvulsant therapy and ketogenic dieting.

All of the children showed a prominent neurological impairment, a rough psychomotor retardation, as well as dysmorphic facial features, including a receding forehead, low hairline, a round face, hypertelorism, epicanthal folds, elongated palpebral fissures, ptosis, a short nose with a broad nasal bridge, low set rotated ears, high palate, drooping mouth corners, and micrognathia. Several patients had abnormal hair growth in the form of a “Mohawk”

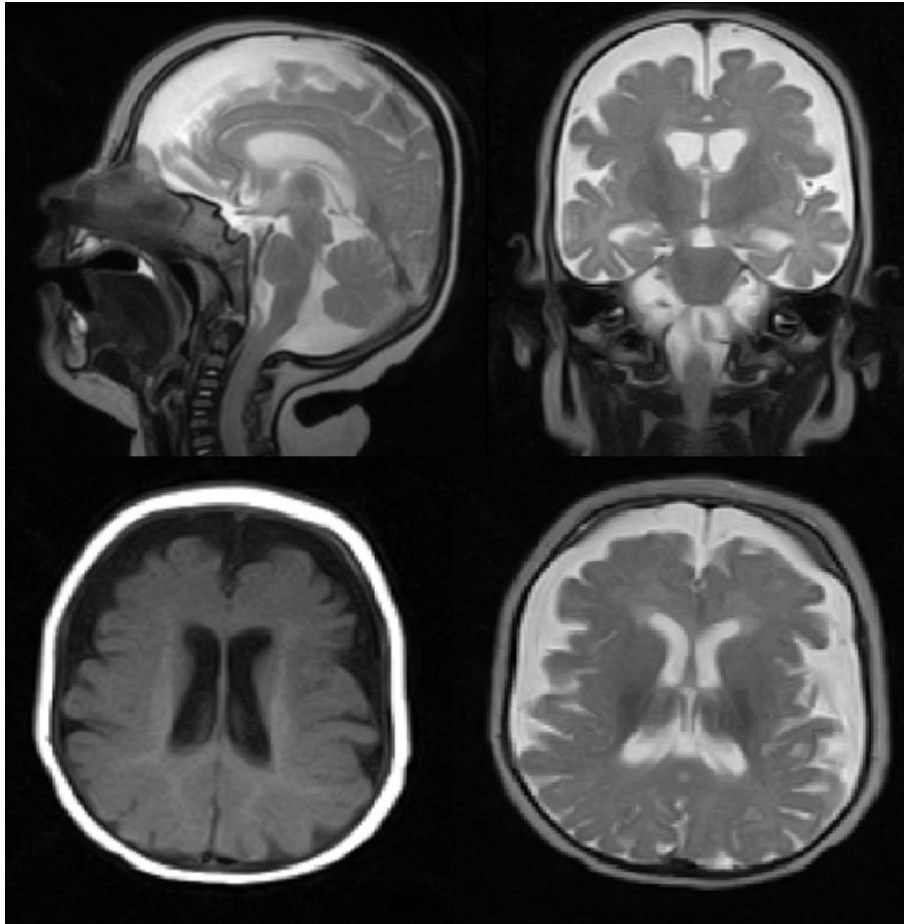


Fig. 3. Magnetic resonance imaging of the brain of Patient. Note diffuse symmetric atrophy of cerebral cortex, atrophic ventriculomegaly, delay in white matter myelination.

and anomalies of the distal limb segments (e.g., hypoplasia/absence of distal phalanges and nails, finger malposition, transverse palmar crease, clinodactyly of the fifth finger, and skin syndactyly). Hyperkinesias, myoclonus of the limbs and eyelids, optic nerve atrophy, divergent strabismus and floating eye movements have been described in a number of patients.

In one case, sensorineural hearing loss, cleft palate, adrenal insufficiency, renal anomalies, and cardiac defects were observed. MRI revealed flattening of the gyri, shallow cerebral fissures, the immaturity of the white matter, and hypoplasia of the hippocampus.

In most cases, the disease is severe, primarily due to nervous system damage. Many children die of septic complications in early childhood.

Taking into account that MIC-CAP is a rare disease, it is obvious that every new case of the syndrome is important to clarify the clinical manifestations of the disease, particularly the identification of common and rare symptoms and further evaluation of their diagnostic significance.

We compared the phenotypic characteristics identified in our patient with currently known data. Table 1 shows the data on clinical manifestations in our patient and the frequency of the features identified in the MIC-CAP syndrome according to the results of all the known descriptions (12 patients).

The high frequency of the features in all described cases allows us to distinguish the “core” symptoms, allowing us to diagnose MIC-CAP syndrome at pre-laboratory stage with a high probability. Such symptoms may include congenital microcephaly, capillary

Table 1

Manifestations of the MIC-CAP syndrome and frequency of symptoms.

Features	The case described	Other data [1–7]	%
Gender	Female	8 male, 4 female	2M:1F
Congenital microcephaly	+	12	100%
Capillary malformations	+	12	100%
Low birth weight	+	11	91,6%
Early-onset resistant seizures	+	11	91,6%
Distinct developmental delay	+	11	91,6%
Hypoplasia of distal phalanges	+	11	91,6%
Spastic tetraparesis	+	10	83,3%
Myoclonus	+	6	50%
Craniofacial anomalies, including:	+	12	100%
Round face	+	4	
Hypertelorism	+	6	
Short wide nose	+	5	
Drooping lip corners	+	3	
Low set ears	+	3	
Short neck	+	3	
Epicanthus	–	3	
Ptosis	–	2	

malformations, drug-resistant seizures, and typical craniofacial dysmorphias.

Initially, it was assumed that one or several genes involved in the processes of vasculogenesis and the regulation of growth are responsible for the development of MIC-CAP syndrome [3]. However, mutations in the *STAMBP* gene (locus 2p13.1) have been detected after whole exome sequencing of children with this

syndrome [4]. All identified types of mutations included 6 missense mutations, 2 nonsense mutations, 2 frameshift mutations and 3 intron mutations leading to alternative splicing. Identified pathogenic variants are mostly unique for each family. However, recurring mutations (p.Arg424Ter [c.1270C > T] p.Phe100Tyr [c.299T > A] and p.Arg38Cys [c.112C > T]) have also been detected, indicating the presence of hot spots in the *STAMBP* gene (NP_006454.1 and NM_006463.4).

Compound heterozygous pathogenic variants were identified and confirmed by molecular genetic testing in 9 out of 11 families with a MIC-CAP diagnosis. In the two remaining families, there was a homozygous variant (consanguineous marriage) in one case and a uniparental disomy in the other family [4].

In 2014, a description of the syndrome in two brothers (7 and 12 years old) of Arab origin from a consanguineous marriage was published. Unlike other cases, the disease was characterized by a milder course of symptoms (later epilepsy development and less prominent neurologic impairment) [5]. In addition to the previously described symptoms, hypothyroidism and autistic behavior have been detected in these patients. An accurate diagnosis was confirmed by molecular genetic testing, which identified a homozygous pathogenic mutation in the *STAMBP* gene. This case indicates the variability of the clinical manifestations of MIC-CAP syndrome. Faqeih EA et al. described an Arab family of two siblings with classic features of MIC-CAP syndrome, which additionally display previously unreported findings of congenital hypothyroidism and alopecia areata [6]. Naseer MI et al. described two brothers from a consanguineous family of Egyptian ancestry with a homozygous missense variant in *STAMBP* (p.K303R) in the two siblings [7].

In our case, the *STAMBP* gene deletion in a heterozygous state c.273delA and the intron replacement c.204–5 C > G in a heterozygous state, which are rare in the population according to the ExAC

database (0,000865%) and not described in HGMD mutations databases, were identified. Both mutations have been considered pathogenic. Additionally, the polymorphic variant c.1218 + 12T > C in a heterozygous state described in the international polymorphisms database was identified.

In summary, we report a child with recently recognized and genetically determined MIC-CAP syndrome. This syndrome is characterized by severe congenital microcephaly, diffuse capillary malformations, intractable epilepsy, including infantile spasms, and severe developmental retardation. In this case, previously unknown mutations of the *STAMBP* gene were identified.

References

- [1] Carter MT, Geraghty MT, De La Cruz L, Reichard RR, Boccutto L, Schwartz CE, et al. A new syndrome with multiple capillary malformations, intractable seizures, and brain and limb anomalies. *Am J Med Genet Part A* 2011;155A:301–6.
- [2] Isidor B, Barbarot S, Beneteau C, Le Caignec C, David A. Multiple capillary skin malformations, epilepsy, microcephaly, mental retardation, hypoplasia of the distal phalanges: report of a new case and further delineation of a new syndrome (Letter). *Am J Med Genet Part A* 2011;155A:1458–60.
- [3] Mirzaa GM, Paciorkowski AR, Smyser CD, Willing MC, Lind AC, Dobyns WB. The microcephaly-capillary malformation syndrome. *Am J Med Genet Part A* 2011;155A:2080–7.
- [4] McDonnell LM, Mirzaa GM, Alcantara D, Schwartzentruber J, Carter MT, Lee IJ, et al. Mutations in *STAMBP*, encoding a deubiquitinating enzyme, cause microcephaly-capillary malformation syndrome. *Nature Genet* 2013;45:556–62.
- [5] Pavlović M, Neubauer D, Al Tawari A, Heberle LC. The microcephaly-capillary malformation syndrome in two brothers with novel clinical features. *Pediatr Neurol* 2014;51(4):560–5.
- [6] Faqeih EA, Bastaki L, Rosti RO, Spencer EG, Zada AP, Saleh MA, et al. Novel *STAMBP* mutation and additional findings in an Arabic family. *Am J Med Genet Part A* 2015;167A(4):805–9.
- [7] Naseer MI, Sogaty S, Rasool M, Chaudhary AG, Abutalib YA, Walker S, et al. Microcephaly-capillary malformation syndrome: Brothers with a homozygous *STAMBP* mutation, uncovered by exome sequencing. *Am J Med Genet Part A* 2016;170(11):3018–22.