



CASE REPORT

Meier–Gorlin syndrome: An additional Egyptian patient with gastroesophageal reflux, hydronephrosis, renal stones and hypoplastic labia majora and minora with clitromegaly



Rabah M. Shawky*, Radwa Gamal

Pediatric Department, Genetics Unit, Ain Shams University, Egypt

Received 6 December 2015; accepted 15 December 2015
Available online 23 January 2016

KEYWORDS

Meier–Gorlin syndrome;
Gastro esophageal reflux;
Renal stones;
Hypoplastic labia majora;
Clitromegaly;
Microtia;
Absent patella;
Hydronephrosis

Abstract We report a 4.5 year old female child with the classical triad of Meier–Gorlin syndrome (microtia, absent patella and short stature) with normal mentality. She had small triangular face, long peaked nose, high nasal bridge, bilateral low set very small ears (microtia), retromicrognathia, high arched palate, maxillary hypoplasia, decayed teeth, and bilateral partial syndactyly between 2nd and 3rd toes. Our patient had a gastroesophageal reflux, renal stones, hydronephrosis and hypoplastic labia majora and minora with clitromegaly.

© 2016 Ain Shams University. Production and hosting by Elsevier B.V. This is an open access article under the CC BY-NC-ND license (<http://creativecommons.org/licenses/by-nc-nd/4.0/>).

1. Introduction

The Meier–Gorlin syndrome (MGS) is a rare autosomal recessive disorder characterized by severe intrauterine and postnatal growth retardation, microcephaly, bilateral microtia, and aplasia or hypoplasia of the patella [1]. Almost all cases have primordial dwarfism with substantial prenatal and postnatal growth retardation [2].

Mutations in five genes from the pre-replication complex (ORC1, ORC4, ORC6, CDT1, and CDC6) were identified in individuals with MGS [3].

Here we report the second Egyptian patient with MGS in the same hospital [4] after taking consent of the parents.

2. Case report

Our patient is a 4.5 year old female child, second in order of birth to healthy consanguineous Egyptian parents. The patient was delivered at full term by cesarean section. Her birth weight was 1.5 kg (< 5th centile). No problems were noted by the mother during pregnancy. The patient was referred to the Genetics Clinic, Pediatric Hospital, Ain Shams University complaining of short stature.

At birth, the patient had difficulty in breathing which necessitated admission to neonatal intensive care unit (NICU) for 3 days. At the age of 1 week, she had recurrent attacks of vomiting which were relieved by antiemetic drugs. Barium meal was done and revealed gastro esophageal reflux disease (GERD). She also had recurrent attacks of chest infections every month which improved at the age of 4 years. Since the age of 1 year, the patient had recurrent attacks of vomiting

* Corresponding author.

E-mail address: shawkyrabah@yahoo.com (R.M. Shawky).

Peer review under responsibility of Ain Shams University.

<http://dx.doi.org/10.1016/j.ejmhg.2015.12.006>

1110-8630 © 2016 Ain Shams University. Production and hosting by Elsevier B.V.

This is an open access article under the CC BY-NC-ND license (<http://creativecommons.org/licenses/by-nc-nd/4.0/>).

and hematemesis till the age of 3 years. This necessitated multiple endoscopic biopsies from duodenum, esophagus, stomach which revealed superficial gastritis and duodenitis. At the age of 4 years Nissen Fundoplication procedure was done for GERD.

Both parents were normal. Family history showed a previous sib death at the age of 3 days with cyanosis and another healthy sib.

On examination, her weight was 9 kg (below 3rd percentile), her height was 86 cm (below 3rd percentile), her span was 81.5 cm, weight for stature (< 3rd centile) and her skull circumference was 44 cm (below 3rd percentile).

The girl is slim and short. She had small triangular face, long peaked nose, high nasal bridge, bilateral low set very small ears (microtia), retromicrognathia, high arched palate, maxillary hypoplasia (Fig. 1), widely separated upper incisors and decayed teeth (Fig. 2).

There was bilateral partial cutaneous syndactyly between 2nd and 3rd toes (Fig. 3).

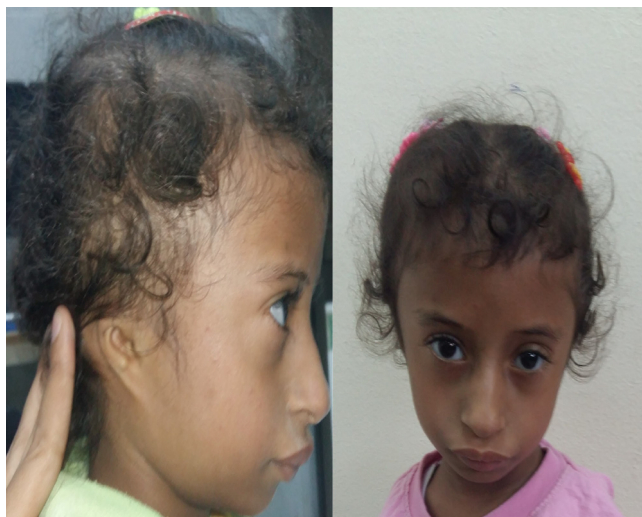

Figure 1 Facial features, small triangular face, long peaked nose, high nasal bridge, low set very small ear (microtia), retromicrognathia, high arched palate and maxillary hypoplasia.

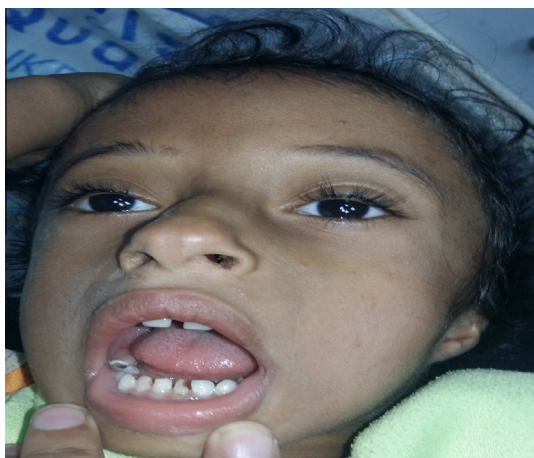

Figure 2 Widely separated upper incisors and decayed teeth.

Cardiac examination was apparently normal. Abdominal examination revealed scar of Nissen Fundoplication procedure (Fig. 4).

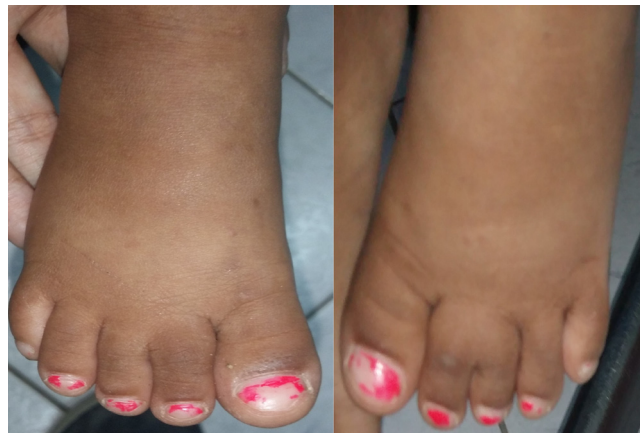

Figure 3 Bilateral partial syndactyly between 2nd and 3rd toes.

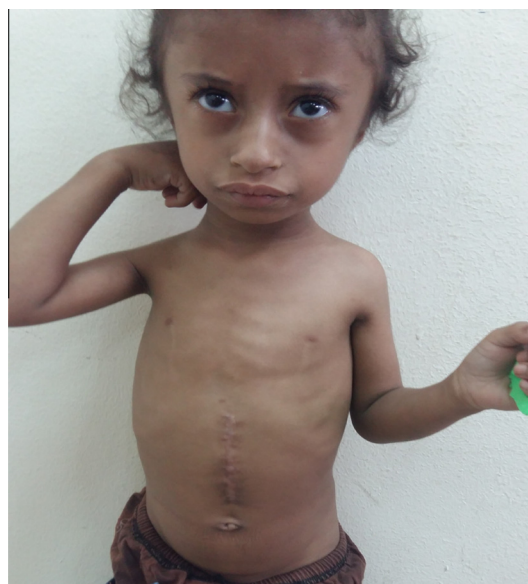

Figure 4 Scar of Nissen Fundoplication procedure.

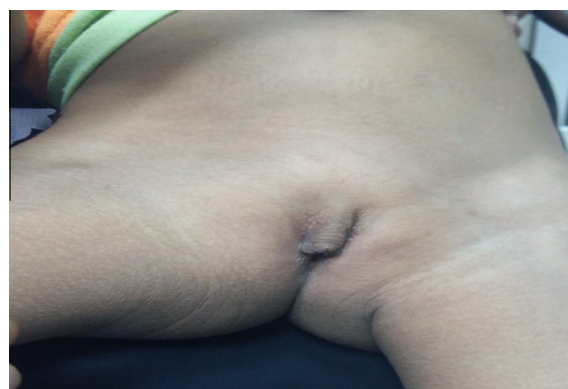

Figure 5 Hypoplastic labia majora and minora and clitoromegaly.

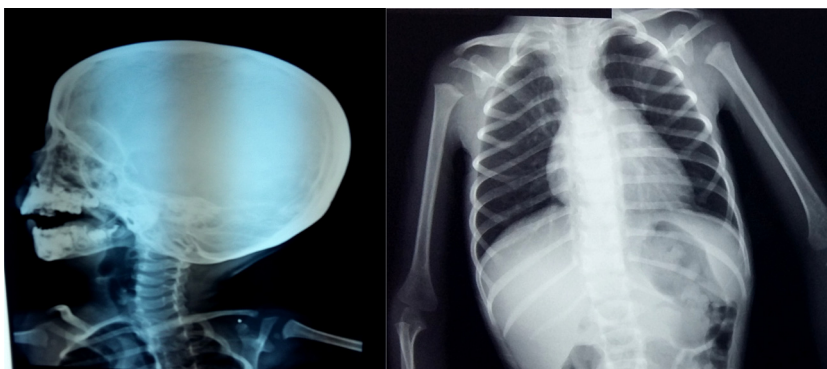


Figure 6 Thin long bones, small mandible and maxilla.




Figure 7 The patellar ossific center is not visualized.

Neurologic examination demonstrated normal tone and reflexes. IQ test was 83.

Genital examination revealed hypoplastic labia majora and minora with clitoromegaly (Fig. 5).

Abdomino-pelvic ultrasonography demonstrated left hydronephrosis and left multiple renal stones at its middle and lower calyces of average size 5.9 mm. ECHO cardiography was normal. Auditory brainstem evoked response revealed bilateral normal hearing. Skeletal survey revealed thin long bones, small mandible and maxilla and only 2 ossific centers of carpal bones are seen. The patellar ossific center is not visualized (Figs. 6 and 7).

Karyotype and growth hormone provocation test were normal. C.T. scan of the brain and temporal bones were normal.

3. Discussion

Meier-Gorlin syndrome (MGS) is a relatively rare condition whose features include short stature, small external ears and reduced or absent kneecaps (patellae). It was defined by Gorlin in 1975, although an earlier case report from 1959 was noted. Since then, additional cases have been reported worldwide [5].

Patients with MGS have a recognizable facial phenotype with microstomia, full lips and retro-/micrognathia at young age. The nose can be narrow and convex with a high nasal bridge. These characteristics of the nose become more prominent with age [6].

We report a 4.5 year old child with typical characteristics of Meier-Gorlin syndrome who presented with small triangular face, long peaked nose, high nasal bridge, bilateral low set very small ears (microtia), retromicrognathia, high arched palate, maxillary hypoplasia, decayed teeth, absent patella and short stature.

Our patient had a cheerful and friendly personality. Skeletal examination revealed absent patellae. Patellar anomalies are among the most frequent findings in MGS. In most patients, patellae are absent, but they may be hypoplastic [6].

Other skeletal manifestations of this syndrome include craniosynostosis, cleft soft palate, abnormal glenoid fossae, hooked clavicles, flat epiphyses, clinodactyly of the fifth finger. Skeletal survey of our patient revealed thin long bones, small mandible and maxilla and only 2 ossific centers of carpal bones are seen with absent patellar ossific centers.

Despite the presence of microcephaly, intellect is usually normal [2,7] as seen in our patient.

Abnormal genitalia, which was described in patients with MGS and consisted predominantly of cryptorchidism and hypoplastic labia majora/minora [8] and clitoromegaly in females [9]. Our patient had hypoplastic labia majora and minora with clitoromegaly.

All postpubertal females had mammary hypoplasia. Transvaginal ultrasound investigations were performed in five adult females (clinically diagnosed with MGS) and a small uterus was reported in three of them. Polycystic ovaries also were reported in two of these five females [10].

Intrauterine growth retardation is a constant sign in all patients with the Meier-Gorlin syndrome, as detected in our patient, and postnatal growth retardation is also characteristic and sometimes can be severe [5,11]. The short stature probably is not related to hormone deficiency because the evaluation of serum human growth hormone reserve and of insulin-like growth-factor 1 level were found normal or slightly subnormal [11,12].

Growth hormone therapy was unsuccessful in MGS patients with a known molecular defect. However, growth hormone therapy was successful in two patients with a clinical diagnosis of MGS, whose growth velocity continued to be low after the first year and who had low levels of IGF1 [10].

Feeding problems in infancy and young childhood were very common in individuals with MGS, with a prevalence of 81% in individuals with mutations and 100% in individuals without a known molecular cause. Feeding problems ranged from a small appetite to gastroesophageal reflux and failure to thrive.

Of 41 individuals, 17 had tube feeding or gastrostomy interventions [8]. Our patient had repeated attacks of vomiting and barium meal revealed gastroesophageal reflux disease. The patient endoscopic biopsies revealed superficial gastritis, duodenitis and mild reflux esophagitis. Nissen Fundoplication procedure was done for GERD.

Individuals with MGS show additional clinical features, such as pulmonary emphysema, brain malformations and congenital heart defects [8] which were not detected in our patient. Our patient had history of recurrent attacks of chest infections.

Microtia can be associated with narrow ear canals and conductive hearing loss [6]. Loeyes et al., [12] reported 2 brothers with Meier–Gorlin syndrome and both had severe deafness and congenital labyrinthine anomalies. Our patient had normal hearing. However our reported 1st case had bilateral moderate conductive hearing loss [4].

Papilledema was reported in MGS. Eye and fundus examinations were normal in our patient [13].

Unilateral kidney aplasia and kidney stones were reported [8] in MGS, as well as hypoplasia of corpora cavernosa and the medial segment of the urethra in some patients [9]. Abdomino-pelvic ultrasonography of our patient demonstrated left hydronephrosis and left multiple renal stones.

Echo cardiography of our patient was normal. The 1st reported MGS case in our locality had fenestrated interatrial septum at foramen ovale with minimal shunting [4].

Parental consanguinity and the occurrence of affected sibs of normal parents indicate autosomal recessive inheritance of MGS [14]. Consanguineous marriages are very common in Egypt (35.3%) [15] and this favors the appearance of autosomal recessive genetic syndromes.

In a patient clinically suspected to have MGS, the diagnosis can be confirmed by detecting compound heterozygous or homozygous mutations in one of the five prereplication complex genes (ORC1, ORC4, ORC6, CDT1, and CDC6). Mutations were detected in approximately 78% of patients clinically suspected for MGS [8]. Approximately 22 % of patients with a classical clinical phenotype of MGS lacked mutations in one of the five known genes of the pre-replication complex [8].

De Munnik et al., [8] studied 45 patients from 35 families with Meier–Gorlin syndrome [16]. Thirty-five patients from 26 families had mutations in 1 of the 5 known pre-replication complex genes, including 10 (29%) with mutations in ORC1, 7 (20%) in ORC4, 7 (20%) in ORC6, 10 (29%) in CDT1, and 1 (3%) in CDC6; 10 patients from 9 families did not have a definitive molecular diagnosis. The classic triad of microtia, absent or hypoplastic patellae, and short stature was observed in 82% of these patients with additional manifestations included mammary hypoplasia and abnormal genitalia, which was present in 42% and consisted predominantly of cryptorchidism and hypoplastic labia majora/minora. Individuals with ORC1 mutations had significantly shorter stature and smaller head circumference than individuals with mutations in the 4 other genes and individuals without definitive molecular diagnosis.

To conclude, we report an Egyptian patient with the diagnostic triad of MGS (microtia, absent patella and short

stature). Our patient also had gastroesophageal reflux disease, unilateral hydronephrosis, renal stones and hypoplastic labia majora and minora with clitoromegaly. This is the 2nd report of a patient with MGS in our locality.

Conflict of interest

The authors declare no conflict of interest.

References

- [1] Shalev SA, Hall JG. Another adult with Meier–Gorlin syndrome – insights into the natural history. *Clin Dysmorphol* 2003;12(3):167–9.
- [2] Bicknell LS, Bongers EMHF, Leitch A, Brown S, Schoots J, Harley ME, et al. Mutations in the pre-replication complex cause Meier–Gorlin syndrome. *Nat Genet* 2011;43:356–9.
- [3] Bicknell LS, Walker S, Klingseisen A, Stiff T, Leitch A, Kerzendorfer C, et al. Mutations in ORC1, encoding the largest subunit of the origin recognition complex, cause microcephalic primordial dwarfism resembling Meier–Gorlin syndrome. *Nat Genet* 2011;43:350–5.
- [4] Shawky RM, Elabd HSA, Gamal R, Mohammad SA, Gad S. Meier–Gorlin syndrome: report of an additional patient with congenital heart disease. *Egypt J Med Hum Genet* 2014;15(4):393–8.
- [5] Gorlin RJ, Cervenka J, Moller K, Horrobin M, Witkop Jr CJ. Malformation syndromes. A selected miscellany. *Birth Defects Orig Artic Ser* 1975;11(2):39–50.
- [6] de Munnik et al. Meier–Gorlin syndrome. *Orphanet J Rare Dis* 2015;10:114.
- [7] Buebel MS, Salinas CF, Pai GS, Macpherson RI, Greer MK, Perez-Comas A. A new seckel like syndrome of primordial dwarfism. *Am J Med Genet* 1996;64:447–52.
- [8] de Munnik A, Bicknell LS, Aftimos S, Al-Aama JY, van Bever Y, et al. Meier–Gorlin syndrome genotype-phenotype studies: 35 individuals with pre-replication complex gene mutations and 10 without molecular diagnosis. *Eur J Hum Genet* 2012;20(6):598–606.
- [9] Bongers EMHF, Hamel BCJ, Fryer A, Sarda P, Hennekam RCM, van Bokhoven H. The Meier–Gorlin syndrome: report of four additional cases and review. *Am J Med Genet* 2001;104:115–24.
- [10] de Munnik SA, Otten BJ, Schoots J, Bicknell LS, Aftimos S, Al-Aama JY, et al. Meier–Gorlin syndrome: growth and secondary sexual development of a microcephalic primordial dwarfism disorder. *Am J Med Genet A* 2012;158A:2733–42.
- [11] Hurst JA, Winter RM, Baraister M. Distinctive syndrome of short stature, craniosynostosis, skeletal changes, and malformed ears. *Am J Med Genet* 1988;29:107–15.
- [12] Loeyes BL, Lemmerling MM, Van Mol CE, Leroy JG. The Meier–Gorlin syndrome, or ear-patella-short stature syndrome, in sibs. *Am J Med Genet* 1999;84:61–7.
- [13] Kalappanavar NK, Gouli C, Syed Nasiruddin I. Meier–Gorlin syndrome with papilloedema. *J Public Health Med Res* 2013;1(1):53–4.
- [14] Cohen B, Temple IK, Symons JC, Hall CM, Shaw DG, Bhamra M, et al. Microtia and short stature: a new syndrome. *J Med Genet* 1991;28(11):786–90.
- [15] Shawky RM, El-Awady YM, Elsayed SM, Hamadan GE. Consanguineous matings among Egyptian population. *Egypt J Med Hum Genet* 2011;12(2):157–63.
- [16] Guernsey DL, Matsuoka M, Jiang H, Evans S, Macgillivray C, Nightingale M, et al. Mutations in origin recognition complex gene ORC4 cause Meier–Gorlin syndrome. *Nat Genet* 2011;43:360–4.