



Ain Shams University

The Egyptian Journal of Medical Human Genetics

www.ejmhg.eg.net
www.sciencedirect.com



ORIGINAL ARTICLE

Wolman disease in patients with familial hemophagocytic lymphohistiocytosis (FHL) negative mutations



Solaf Elsayed^{a,*}, Ezzat Elsobky^a, Azza Tantawy^a, Eman Ragab^a, Marine Gil^b, Nathalie Lambert^b, Geneviève de Saint Basile^{b,c}

^a Children's Hospital, Ain Shams University, Cairo, Egypt

^b CEDI, Hôpital Necker Enfants Malades, Paris, France

^c INSERM1163, Institut Imagine, Paris, France

Available online 26 September 2015

KEYWORDS

Wolman disease;
Familial hemophagocytic lymphohistiocytosis;
Hepatomegaly;
Splenomegaly;
Fever

Abstract *Background:* Familial hemophagocytic lymphohistiocytosis is a rare autosomal recessive disease that is usually evident in the first few months or years of life. Major signs and symptoms include hepatomegaly, splenomegaly, anemia, leucopenia or thrombocytopenias which resemble many inborn errors of metabolism and lysosomal storage diseases in which hemophagocytic lymphohistiocytosis has also been reported as a secondary association.

Case reports: We report three children with hemophagocytic lymphohistiocytosis for whom mutation screening for the known four genes of FHL ((*PRF1* (FHL2), *UNC13D* (FHL3), *STX11* (FHL4), and *STXBP2* (FHL5)) revealed no mutation, while sequencing of the *LIPA* gene confirmed the diagnosis of Wolman disease. Peculiar characteristics of these patients included absence of prominent fever, huge hepatomegaly and a severe failure to thrive.

Conclusion: Wolman disease should be excluded in patients with clinical and laboratory characteristics of FHL and negative molecular testing especially if the fever is not prominent and is associated with relatively huge hepatomegaly and/or severe failure to thrive.

© 2015 The Authors. Production and hosting by Elsevier B.V. on behalf of Ain Shams University. This is an open access article under the CC BY-NC-ND license (<http://creativecommons.org/licenses/by-nc-nd/4.0/>).

1. Introduction

Familial hemophagocytic lymphohistiocytosis (FHL) presents within the first months or years of life with prolonged fever (more than 7 days), cytopenias, hepatosplenomegaly, liver dysfunction, neurological dysfunction and hemophagocytic cells

in the bone marrow [1]. Secondary (acquired or reactive) hemophagocytic lymphohistiocytosis (HLH) is difficult to distinguish from FHL (primary) by clinical or histologic findings alone. The diagnosis of secondary HLH is usually made in association with infection by viruses, bacteria, fungi, or parasites or in association with lymphoma, autoimmune disease, or metabolic disease [2,3]. Inborn errors of metabolism including biotinidase deficiency [4], lysinuric protein intolerance [5], galactosemia [6], multiple sulfatase deficiency, Gaucher disease, Pearson syndrome, galactosialidosis, methylmalonic acidemia, and propionic acidemia [7] have all been reported

* Corresponding author at: Medical Genetics Center, 27 A Baghdad St., Korba, Cairo, Egypt. Tel.: +20 24151999/24150977. E-mail address: elsayed683@yahoo.com (S. Elsayed).

Peer review under responsibility of Ain Shams University.

<http://dx.doi.org/10.1016/j.ejmhg.2015.08.005>

1110-8630 © 2015 The Authors. Production and hosting by Elsevier B.V. on behalf of Ain Shams University.

This is an open access article under the CC BY-NC-ND license (<http://creativecommons.org/licenses/by-nc-nd/4.0/>).

in association with secondary HLH in some individuals. The main challenge to the physician in these cases is the diagnosis of the underlying IEM.

1.1. Case report (1)

Is a 2.5 month old boy, the second in birth order of double cousin parents who presented at the age of one month with abdominal distension. He had a history of mild fever for the last 5 days (37.7 °C). On examination, the patient's weight was 3 kg (birth weight was 3.250 kg), he had huge hepatomegaly and pallor. CBC showed hemoglobin level of 5 g/dl, total white blood cell count (WBC) of 3800/ μ l and platelets of 98,000/ mm^3 . Bone marrow aspiration revealed moderate hypercellular bone marrow. Erythropoiesis was the most stimulated and showed abundance of the marrow precursors. Late normoblasts showed defective hemoglobinization and deficient stainable iron. Granulocytopoiesis was stimulated to a lesser extent and showed normal morphology and normal maturation sequence. Myeloblasts were 2% of the nucleated marrow elements. The myeloid: erythroid series ratio was decreased to 1.7: (1) Megakaryocytes were increased and showed occasional young forms. Free platelets were decreased in count. Lymphocytes were normal in count (11%) and morphology. Plasma cells were normal, macrophages were markedly increased and showed features of activation with phagocytosis of intact blood cells and marrow elements.

Serum ferritin was 2363 ng/ml (normal; range 10–120), serum LDH was 1612 U/L (normal range 266–500), and serum triglyceride was 528 mg/dl. EBV IGM and CMV IgM were both negative

Abdominal ultrasound revealed markedly enlarged liver measuring 9.8 cm in span in mid clavicular line with homogeneous echopattern with no focal lesion and no dilatation of intrahepatic or extrahepatic bile ducts. The spleen was mildly enlarged measuring 11.2 cm in its long axis with no focal lesions. Both kidneys showed normal site, size and shape with normal thickness and echopattern, with no stones or back pressure changes. Pancreas and para aortic region were free. There was no ascites, no abdominal or pelvic masses or abnormal fluid collection.

Segregation of polymorphic markers study at *PERFORINE*, *UNC13D*, *STXBP2* and *SYNTAXIN 11* genes did show any homozygous haplotype. Sequencing of *LIPA* gene revealed homozygous G969A (W130X) mutation leading to the diagnosis of Wolman disease.

1.2. Patient (2)

Is a 3 month old girl, the second in birth order of double cousin marriage. She had a similar affected brother who died at the age of 3 months and a maternal cousin (girl) who died at the age of one month with a provisional diagnosis of FHL without molecular confirmation, Fig. 1. The patient presented with abdominal distension, pallor and mild fever (38 °C) that decrease with antipyretics. On examination the patient had severe failure to thrive, liver was hugely enlarged 6 cm below the costal margin, and the spleen was 8 cm below the costal margin. CBC showed hemoglobin level of 6.9 g/dl, total leukocytic count of $5.6 \times 10^3/\text{mm}^3$ and platelets of 95,000/ mm^3 . Bone marrow aspiration revealed a marrow infiltrated with

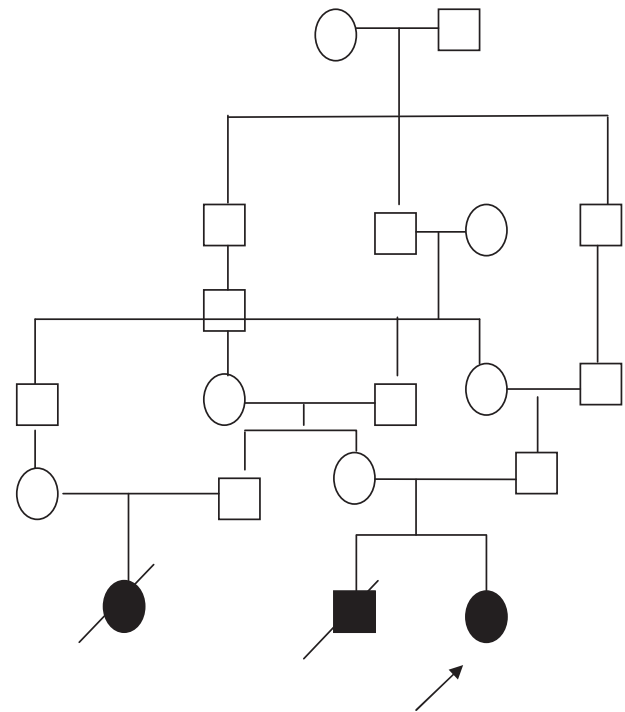


Figure 1 Family pedigree of patient (2).

giant macrophages which showed compressed nuclei due to extensive cytoplasmic vacuolation. These vacuoles contained unstainable contents. In addition many sea-blue histiocytes were seen. Phagocytosis of intact and/or damaged hematopoietic cells was rarely seen. The patient had an initial diagnosis of Niemann–Pick disease and so Beta-glucocerebrosidase enzyme was done and showed normal level of 5.3 $\mu\text{mol/h/g}$ of protein (normal 1–5), sphingomyelinase was also measured with the level of 2.7 $\mu\text{mol/gmpt/h}$ (normal 1.5–5 nmol/h/g) excluding both Niemann–Pick type A and Gaucher disease. Then, the patient was referred to the genetics clinic because of the family history of a genetic disease.

Plasma fibrinogen level was 150 mg/dl (normal value: 150–350), Serum ferritin was 1664 ng/ml (normal; range 10–120), serum LDH was 1612 U/L (normal range 266–500), serum triglyceride was 266 mg/dl, ALT was 17 U/ml (normal up to 30), AST was 78 U/ml (normal up to 40), albumin was 2.2 mg/dl.

Segregation of polymorphic markers study at *PERFORINE*, *UNC13D*, *STXBP2* and *SYNTAXIN 11* genes did show any homozygous haplotype. Sequencing of all coding sequences of *LIPA* gene revealed homozygous mutation c.438delC (p.S112X) leading to the diagnosis of Wolman disease.

1.3. Patient (3)

Is a 3 month old boy, the third in birth order of first cousin parents. The pregnancy was uncomplicated and he was delivered by CS with a birth weight of 3.5 kg. His condition started at the age of 2.5 months when the mother noticed progressive abdominal enlargement, failure to thrive and pallor. On examination, his weight was only 3 kg, length was 52 cm and had no fever except after one week of presentation (38 °C). His liver

was enlarged (8.5 cm below the costal margin), firm with rounded border and smooth surface. His spleen was also enlarged 8 cm below the costal margin. CBC showed hemoglobin level of 7.8 g/dl, total leukocyte count of $10.5 \times 10^3/\text{mm}^3$ and platelets of $80,000/\text{mm}^3$. Bone marrow aspiration was refused by the parents. Plasma fibrinogen level was 200 mg/dl (normal value: 200–400), Serum ferritin was 2543 ng/ml (normal range: 7–140), serum triglyceride was 947 mg/dl. Beta-glucocerebrosidase enzyme was 2.2 $\mu\text{mol}/\text{h}/\text{g}$ (normal 1–5), chitotriosidase was 919 $\text{umol}/\text{L}/\text{h}$ (normal 4–84).

A provisional diagnosis of WD was made and so sequencing of all coding sequencing of LIPA gene revealed homozygous mutation c.G969A (p.W289X) leading to the diagnosis of Wolman disease.

2. Discussion

Reports for the association of Wolman disease with HLH are scarce or underestimated as patients with Wolman disease usually have short life span that does not permit them to be fully investigated for the presence of HLH. In this report we described the clinical and laboratory investigations in three Egyptian patients with HLH and Wolman disease. To the best of our knowledge, this is the first report in Egyptian population.

Al Essa et al. reported the first patient with this association in 1998 in Saudi Arabia when they described an infant with Wolman disease, severe anemia and thrombocytopenia, increased ferritin and both foamy histiocytes and hemophagocytic cells in bone marrow [8]. Seven years later, Perry et al. from Canada studied children with primary adrenal insufficiency and included two patients with Wolman disease and presumptive diagnosis of HLH [9]. Another ten years passed then Rabah et al. described an infant from Oman with this association in whom Wolman disease diagnosis was confirmed by enzyme assay but not by molecular testing [10]. At the same year Taurisano et al. reported another child and explained this presentation by the tendency of cholesteryl esters- characteristic of Wolman disease – to form crystals and to stimulate activation of macrophage-mediated inflammation that could be a trigger of a sustained or acquired HLH which could then be perpetuated by cytokines and ferritin macrophage production. According to this explanation, the presence of HLH should be searched for in every infant with Wolman disease.

In contrast to previous reports, our patients (1 and 2) had a provisional diagnosis of FHL especially patient 2 had a cousin with the diagnosis of FHL diagnosis. Ironically patient (1) was diagnosed with Wolman disease almost 6 months after his death. The difficulties in diagnosis are attributed to the heterogeneous nature of HLH and the similarities of its clinical and laboratory manifestations to many lysosomal storage diseases especially when they are present together.

This difficulty and the long time we faced in reaching a definitive diagnosis (and thereby a proper genetic counseling) was a challenge that we overcame in the third patient where our initial diagnosis was Wolman disease and so time and money were saved and the definitive diagnosis was confirmed in less than one week.

This was through looking back to patients' files, where we noticed that both patients' fever was not as high as we usually see in typical FHL patients. Also both patients had huge livers

Table 1 Comparison between FHL diagnostic criteria and our patients' criteria.

	Patient 1	Patient 2	Patient 3	FHL [1]
Fever	+	+	+	+
Splenomegaly	+	+	+	+
Cytopenias				
Hemoglobin (g/l)	5	6.9	7.8	< 9
Platelets ($\times 10^9/\text{L}$)	98	95	80	< 100
Neutrophils ($\times 10^9/\text{L}$)	2.5	2.12	3.0	< 1.0
Hypertriglyceridemia/ hypofibrinogenemia				
Triglycerides (mg/dL)	528	300	947	≥ 265
Fibrinogen	–	150 mg/dL	200 mg/dL	$\leq 1.5 \text{ gm}/\text{L}$
Ferritin	2363 ng/ml	1664 ng/ml	2543 ng/ml	$\geq 500 \mu\text{g}/\text{L}$
NK cell activity	ND	ND	ND	
Soluble CD25	ND	ND	ND	
Hemophagocytosis in bone marrow	+	–	?	+

ND: not done.

The bold signifies the diagnostic criteria of FHL.

and severe failure to thrive although both did not have the typical diarrhea of Wolman disease patients.

FHL is a genetically heterogeneous disease for which approximately 30% of individuals diagnosed do not have identified mutations in any of the four known genes and evidence of additional loci was provided [11].

The three patients included in this report had clinical and laboratory criteria of FHL as present in Table 1 while their molecular testing for the four known gene of FHL revealed no mutations. We recommend testing of Wolman disease in patients with FHL negative mutation especially if the fever is not prominent and is associated with relatively huge hepatomegaly and/or severe failure to thrive

Conflict of interest

The authors declared no potential conflicts of interests with respect to the authorship and/or publication of this article.

References

- [1] Henter JI, Horne A, Aricó M, Egeler RM, Filipovich AH, Imashuku S, et al. HLH-2004: diagnostic and therapeutic guidelines for hemophagocytic lymphohistiocytosis. *Pediatr Blood Cancer* 2007;48:124–31.
- [2] Imashuku S, Tabata Y, Teramura T, Hibi S. Treatment strategies for Epstein–Barr virus-associated hemophagocytic lymphohistiocytosis (EBV-HLH). *Leuk Lymphoma* 2000;39:37–49.
- [3] Imashuku S, Ueda I, Teramura T, Mori K, Morimoto A, Sako M, et al. Occurrence of haemophagocytic lymphohistiocytosis at less than 1 year of age: analysis of 96 patients. *Eur J Pediatr* 2005;164:315–9.
- [4] Kardas F, Patoroglu T, Unal E, Chiang SC, Bryceson YT, Kendirci M. Hemophagocytic syndrome in a 4-month-old infant with biotinidase deficiency. *Pediatr Blood Cancer* 2012;59:191–3.
- [5] Duval M, Fenneteau O, Doireau V, Faye A, Emilie D, Yotnda P, et al. Intermittent hemophagocytic lymphohistiocytosis is a regular feature of lysinuric protein intolerance. *J Pediatr* 1999;134:236–9.
- [6] Marcoux MO, Laporte-Turpin E, Alberge C, Fournie-Gardini E, Castex MP, Rolland M, et al. Congenital galactosaemia: an unusual presentation. *Arch Pediatr* 2005;12:160–2.

- [7] Gokce M, Unal O, Hismi B, Gumruk F, Coskun T, Balta G, et al. Secondary hemophagocytosis in 3 patients with organic acidemia involving propionate metabolism. *Pediatr Hematol Oncol* 2012; 29:92–8.
- [8] Al Essa M, Nounou R, Sakati N, Le Quesne G, Joshi S, Archibald A, et al. Wolman's disease: the King Faisal specialist hospital and research centre experience. *Ann Saudi Med* 1998;18:120–4.
- [9] Perry R, Kecha O, Paquette J, Huot C, Van Vliet G, Deal C. Primary adrenal insufficiency in children: twenty years experience at the Sainte-Justine Hospital, Montreal. *J Clin Endocrinol Metab* 2005;90:3243–50.
- [10] Rabah F, Al-Hashimi N, Beshlawi I. Wolman disease with secondary hemophagocytic lymphohistiocytosis. *Pediatr Hematol Oncol* 2014;31(6):576–8.
- [11] Ménasché G, Feldmann J, Fischer A, de Saint Basile G. Primary hemophagocytic syndromes point to a direct link between lymphocyte cytotoxicity and homeostasis. *Immunol Rev* 2005;203: 165–79.