

# Therapeutic effect of emergency stent surgery combined with intravenous thrombolysis on patients with acute ischemic stroke and its influence on their quality of life

Tong Li<sup>1,\*</sup>, Ning Zhang<sup>2</sup>, Yang Yang<sup>2</sup>

## Abstract

**Objective:** Ischemic strokes can lead to severe cerebral infarctions with serious complications, as well as cause high disability and mortality rates, which cause a significant burden on the medical field. As of now, there is no permanent therapy for ischemic strokes. So there is a need to find a permanent solution for this complication. Therefore, the present study was to examine whether emergency stent surgery along with intravenous thrombolysis enhanced the health status of patients with acute stroke and ischemia.

**Methods:** In the current study, 106 patients with acute ischemic stroke hospitalized between November 2019 and November 2020 were randomly allocated to two groups, 53 cases in each study group and control group. The control group was treated with drug thrombolysis, while the study group underwent emergency stent surgery based on drug thrombolysis. The hemodynamic alterations, NIHSS score, Barthel score, and MRS score before and after therapy were evaluated among the two groups at 1 day, 7 days, and 14 days after the therapy. The hemodynamic alterations, NIHSS score, Barthel score, and MRS score before and after therapy were evaluated among the 2 groups at various intervals, 1 day, 7 days, and 14 days after the therapy. The serum cytokine levels of patients before and after treatment were compared, and the incidence of related complications was compared among the tested groups.

**Results:** Following treatment, both groups' Qmean and Vmean increased considerably, while their levels of R, DR, LBV, and HBV reduced significantly ( $P < 0.05$ ), with the index changes in the test group being more significant than the control group ( $P < 0.05$ ). The patients' NIHSS and MRS scores dropped after therapy, whereas their Barthel score increased ( $P < 0.05$ ). The study group's NIHSS and MRS scores were lower than the control group's at T1, T2, and T3 after treatment, whereas the control group's Barthel score was higher ( $P < 0.05$ ). The serum SOD levels of the two groups of patients developed after treatment, Chemerin, BNP, angii, IL-6, TNF- $\alpha$  and MDA levels decreased ( $P < 0.05$ ). The level of factor alterations was increased in the tested group as compared to the control group ( $P < 0.05$ ). Complications were less common in the study group as compared to the control group ( $P < 0.05$ ).

**Conclusion:** The result revealed that emergency stent surgery coupled with drug thrombolysis was more effective than drug thrombolysis alone, with lower complication rates, improved safety, and more successful practical applications. [*Ethiop. J. Health Dev.* 2022; 36(2) 163-170]

**Key words:** Emergency stent surgery; Intravenous thrombolysis; Acute ischemic stroke

## Introduction

Epidemiological survey results indicated that more than two million people died from cerebrovascular emergencies annually in China, and among them, the death rate of ischemic strokes (AIS) account for more than 70%, which seriously threatens the life and health of patients (1-3). AIS can cause acute cerebral infarctions, with serious/ complications and high disability and mortality rates (4), causing a great burden to patients' families and social medical systems. At present, commonly used clinical treatment methods include thrombolysis and stent implantation (5-6). One of the most successful treatments for AIS is to employ recombinant tissue plasminogen activators (rt-PA) during the therapy time frame to restore blood vessel patency and blood flow to the brain tissue (7-8). However, permanent stent implantation is a popular therapy for AIS (9-10). Under the guidance of ultrasound or X-ray, microfilament microtubules are placed at the

stenosis position of blood vessels, balloon dilation is carried out, the vascular stent is implanted, and the recanalization of occluded blood vessels is observed using angiography (11). Currently, a single method is often used to treat AIS clinically, many clinical guidelines suggest the use of an intravenous thrombolytic bridging stent thrombectomy for the treatment of acute large vessel occlusions (12). In this study, the therapeutic outcome and postoperative value for the lives of patients with intravenous thrombolysis alone and emergency stent surgery combined with intravenous thrombolysis were compared. The influence of different methods on the curative effect and prognosis of patients was explored, with the aim of providing evidence for the treatment of AIS patients in clinic.

## Materials and Methods

### General data

<sup>1</sup>Neurosurgery, Beijing Chao-Yang Hospital, Capital Medical University, Beijing 100020, China.

<sup>2</sup>Neurosurgery, The First Affiliate Hospital of Baotou Medical College, Baotou 014000, China.

\***Corresponding author:** Tong Li. Neurosurgery, Beijing Chao-Yang Hospital, Capital Medical University, Beijing 100020, China. **Email:** doctorlitong@126.com Gongren Tiyuchang Nanlu, Chaoyang District, Beijing 10020, China

A total of 106 patients with ischemic stroke who were hospitalized during November 2019 and November 2020 were chosen as research participants. The selected participants were split into two groups, with 53 cases in each. The test group consisted of 36 men and 17 females, with an average age of  $(65.13 \pm 9.42)$  years. The control group consisted of 32 males and 21 females, with an average age of  $(66.24 \pm 8.23)$  years. The diagnosis of an ischemic stroke for all patients was based on the Guidelines for Early Intravascular Interventional Diagnosis and Treatment of Acute Ischemic Strokes in China 2018 (13). Patients with malignant tumors, important organ injury, autoimmune system diseases, mental disorders and a previous cardiovascular history were not included in this study. The informed consent for the study was signed by all participants and their families, and it was validated by the hospital medical ethics committee.

### ***The Treatment of ischemic stroke in different groups***

**Thrombolytic therapy:** Both the test and control group received recombinant human TNK tissue plasminogen activator injections (Mingfule, Guangzhou Mingkang Bioengineering Co., Ltd., Guo Yao Zhun Zi S20150001) for thrombolytic therapy. 16mg was given at a single time. 16mg of drug powder was dissolved with 3ml normal saline and then injected within 5 ~ 10s using intravenous injections.

**Methods of emergency stenting:** Patients in the study group underwent emergency stenting based on thrombolytic therapy. Patients were given a glycoprotein IIb/IIIa inhibitor (GPI) tirofiban 055mg intravenous drip for 6-12 hours before and after the operation. Antiplatelet drugs aspirin and Polivir were taken orally before and after the emergency stenting operation, and 300mg Polivir was taken orally immediately after the emergency stenting operation. After heparinization, the patients underwent angiographic exploration. Under the guidance of a microfilament catheter, the microtubule was placed at the stenosis site for fixation, the balloon was released to dilate the blood vessel, and then the stent was released. Arteriography was used to check the recanalization of the blood vessel. Blood pressure was controlled, and nutritional support was given following the operation.

### **Observation indexes**

① Patients' hemodynamic changes, such as cerebrovascular blood flow ( $Q_{\text{mean}}$ ), mean cerebral circulation blood flow velocity ( $V_{\text{mean}}$ ), vascular peripheral resistance (R), dynamic resistance (DR), whole blood viscosity at low shear rates (LBV), and whole blood viscosity at high shear rates (HBV), were compared before and after therapies. ② T0, T1, T2, and T3 patients were classified as such prior to therapy, one day after treatment, seven days after treatment, and fourteen days after therapy, respectively. The baseline National Institutes of Health Stroke Scale (NIHSS) score, Barthel score and modified Rankin scale (mRS) score prior to onset were compared. The total score of NIHSS was 42 points, and the higher the score, the more severe the brain injury. The total score of Barthel score was 100, and the higher the score, the stronger the patient's self-care ability. The higher the score, the worse the nerve recovery of the stroke patients. The same physician compared the scores of the above scale between the two groups at T0, T1, T2 and T3. ③ the occurrence of hemiplegia, language disorder, motor disorder, and decline in learning and cognitive ability were compared between the two groups following treatment. ④ Enzyme-linked immunosorbent assay (ELISA) was used to compare the serum adipocytokine (Chemerin), plasma brain natriuretic peptide (BNP), angiotensin II (AngII), interleukin-6 (IL-6), tumor necrosis factor- $\alpha$  (TNF- $\alpha$ ), malondialdehyde (MDA), superoxide dismutase (SOD) levels in the two groups before and after treatment.

### **Statistical analyses**

SPSS 21.0 was used to analyze the data, and measured data with normal distributions were expressed as  $X \pm S$ , The Student-t test was employed to analyze the data in the two groups, the one-way ANOVA was used for multi-group comparisons, counting data was expressed as [n (%)], and the  $\chi^2$  T test was used to assess the two groups. The outcomes were considered statistically significant when  $P < 0.05$ .

### **Results**

#### ***Assessment of general data of patients***

The results indicated that there were no obvious differences in general data such as age, gender and BMI of patients, and the data was comparable, as indicated in Table 1.

**Table 1. Assessment of general data of test patients**

Indicators	Grouping	Study group (n=53)	Control group (n=53)	Statistical value	P
Gender (case)	Male	36	32	0.656	0.418
	Female	17	21		
Age (years old)		65.13±9.42	66.24±8.23	0.646	0.519
BMI (kg/m <sup>2</sup> )		24.12±2.65	24.31±2.47	0.382	0.703

<b>SBP (mmHg)</b>		147.22±13.53	149.61±15.71	0.839	0.403
<b>DBP (mmHg)</b>		84.63±9.79	83.15±8.69	0.823	0.412
<b>Complicated with hypertension</b>	<b>Yes</b>	33	31	0.158	0.691
	<b>No</b>	20	22		
<b>Complicated with diabetes mellitus</b>	<b>Yes</b>	23	24	0.038	0.845
	<b>No</b>	30	29		
<b>Combined with atrial fibrillation</b>	<b>Yes</b>	14	15	0.047	0.828
	<b>No</b>	39	38		
<b>Smoking or not</b>	<b>Yes</b>	26	25	0.038	0.846
	<b>No</b>	27	28		
<b>Drinking alcohol</b>	<b>Yes</b>	13	11	0.215	0.643
	<b>No</b>	40	42		

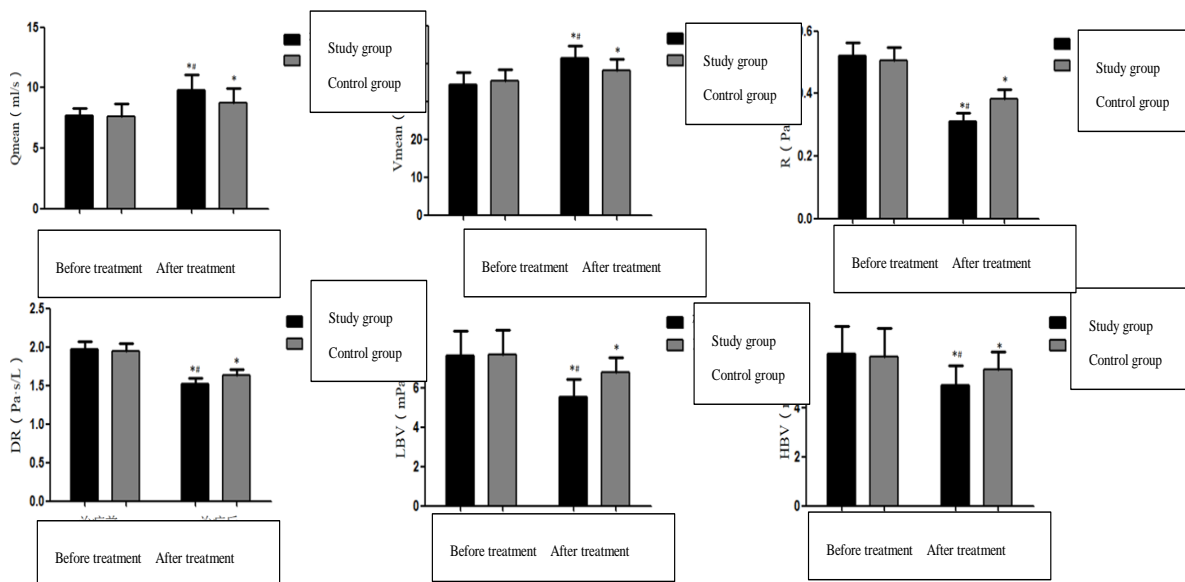
**Hemodynamic alterations in two groups before and after therapy:** The findings demonstrate that after diagnosis,  $Q_{\text{mean}}$  and  $V_{\text{mean}}$  of patients in both groups increased substantially, while R, DR, LBV,

and HBV levels decreased significantly ( $P < 0.05$ ), and the increased levels of  $Q_{\text{mean}}$  and  $V_{\text{mean}}$  in the test group were more noticeable than in the control group ( $P < 0.05$ ), see Table 2 and Figure 1.

Table 2. Hemodynamic alterations in two groups before and after therapy

Hemodynamic indexes	Study group (n=53)		Control group (n=53)	
	Before treatment	After treatment	Before treatment	After treatment
$Q_{\text{mean}}$ (ml/s)	7.64±1.71	9.77±2.02* <sup>#</sup>	7.58±1.73	8.59±1.91*
$V_{\text{mean}}$ (cm/s)	34.25±5.19	40.49±7.67* <sup>#</sup>	35.44±5.08	38.22±6.94*
R (Pa·s/L)	0.51±0.08	0.31±0.05* <sup>#</sup>	0.50±0.07	0.39±0.06*
DR (Pa·s/L)	1.97±0.19	1.51±0.12* <sup>#</sup>	1.94±0.18	1.64±0.15*
LBV (mPa·s)	7.62±2.14	5.51±1.72* <sup>#</sup>	7.59±2.32	6.39±1.78*
HBV (mPa·s)	6.14±2.01	4.82±1.53* <sup>#</sup>	6.05±2.02	5.56±1.77*

Note: \* $P < 0.05$  compared with that before treatment; <sup>#</sup> $P < 0.05$  compared to that control group



**Figure 1. Hemodynamic index changes in the two groups of patients before and after therapy**

**NIHSS score, Barthel score, and mRS score of the two groups at different time points:** The results revealed that following treatment, the NIHSS and mRS scores of the two groups were reduced, while the Barthel score increased, and the changes

were statistically significant ( $P < 0.05$ ). The NIHSS and mRS scores of patients in the study group were lower than those in the control group at T1, T2, and T3 following treatment, but the Barthel score was greater ( $P < 0.05$ ), see table 3 and figure 2.

**Table 3. NIHSS score, Barthel score, and mRS score of the two groups of patients at different time points**

Scoring	Grouping	T <sub>0</sub>	T <sub>1</sub>	T <sub>2</sub>	T <sub>3</sub>	F	P
NIHSS score	Control group	15.31±2.72	12.43±2.51	8.93±1.77	7.51±1.54	136.446	< 0.001
	Study group	15.43±2.81	11.24±2.32*	8.03±1.69*	6.12±1.31*	197.106	< 0.001
Barthel score	Control group	45.17±9.22	50.26±10.05	55.72±10.51	60.26±10.34	22.570	< 0.001
	Study group	45.43±9.31	53.03±10.39*	60.59±9.18*	68.92±10.71*	54.687	< 0.001
mRS score	Control group	2.69±0.33	2.51±0.31	2.15±0.25	1.68±0.17	142.066	< 0.001
	Study group	2.71±0.34	2.33±0.29*	1.91±0.23*	1.34±0.11*	276.493	< 0.001

**Note:** \*P means  $P < 0.05$  compared with the control group.

**Changes in serum associated cytokines in two groups before and after treatment:** The findings indicated that the blood SOD levels of the investigated patient groups increased considerably following therapy. Although serum Chemerin, BNP, AngII, IL-6, TNF-, and MDA levels considerably decreased ( $P < 0.05$ ). The serum cytokine changes in the study group after treatment were greater than those in the control group ( $P < 0.05$ ), as shown in table 4 and Figure 3.

Table 4. Changes in serum cytokines in the groups during therapy

Serum cytokines	Study group (n=53)		Control group (n=53)	
	Before treatment	After treatment	Before treatment	After treatment
Chemerin (ng/ml)	115.31±10.96	85.34±5.92* <sup>#</sup>	117.69±10.75	95.69±8.21*
BNP (pg/ml)	335.14±70.22	158.29±33.63* <sup>#</sup>	361.29±73.21	257.17±37.29*
AngII (ng/ml)	35.22±6.71	19.51±4.28* <sup>#</sup>	35.79±6.83	27.36±5.94*
IL-6 (ug/ml)	30.25±6.41	15.53±3.82* <sup>#</sup>	29.91±6.29	21.47±4.96*
TNF-α (umol/ml)	16.88±5.31	6.53±2.06* <sup>#</sup>	16.94±5.27	10.44±3.81*
SOD (nmol/ml)	75.13±8.44	95.64±10.29* <sup>#</sup>	76.29±8.52	85.22±9.41*
MDA (nmol/ml)	9.82±1.34	7.11±1.12* <sup>#</sup>	9.79±1.31	8.53±1.24*

Note: \**P* means *P* < 0.05 compared with that before treatment; <sup>#</sup>*P* denotes *P* < 0.05 compared to that control group

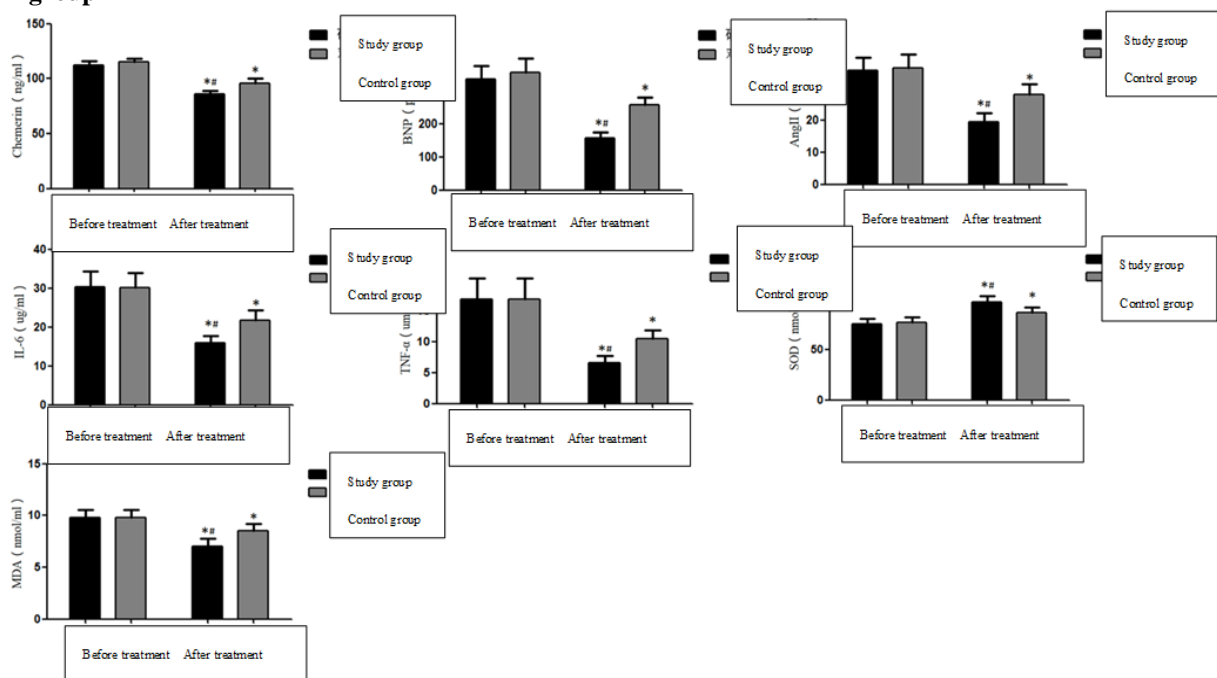


Figure 3. Changes in blood levels of related cytokines in the two groups during therapy

#### Complications after treatment in both groups:

There were two patients with hemiplegia, two patients with dyskinesia, three patients with language disorders, and three patients with cognitive decline in the control group, and ten patients with connected problems. However, there was only one

patient with a language issue and two patients with cognitive decline in the research group, for a total of three instances. As demonstrated in Table 5, the incidence of associated problems in the study group was considerably lower as compared to the control group (*P* < 0.05).

Table 5. Complications of the two groups of patients after treatment

Related complications	Control group (n=53)	Study group (n=53)	$\chi^2$	<i>P</i>
Hemiplegia n (%)	2(3.78)	0(0.00)		
Dyskinesia n (%)	2(3.78)	0(0.00)		
Language barrier n (%)	3(5.67)	1(1.89)		
Decreased cognitive function n (%)	3(5.67)	2(3.78)		
Total occurrence n (%)	10(18.90)	3(5.67)	4.296	0.038

## Discussion

AIS is a major source of morbidity and mortality in the world, and the incidence is increasing annually. About half of the incidences are caused by vascular occlusion or stenosis induced by intracranial atherosclerosis (14-16). Intravenous thrombolysis was the first therapy for treating ischemic strokes that was authorized by the FDA, but it has certain limitations, especially in patients with intracranial aorta involvement, and the probability of a recurrent stroke within one year for patients receiving regular thrombolytic therapy is higher than 10%, which often leads to the poor prognosis of patients (17). First-line intravenous thrombolytic drugs are often used within 6 hours of the onset of a stroke, which can reduce the effects of the stroke by reducing brain tissue damage, and at the same time it is easy to lead to instantaneous reclusion. At present, arteriovenous combined thrombolysis is often used clinically to reduce the side effects and improve the thrombolytic effect. The prognosis of patients is better when treatment is administered at the onset. Commonly used drugs for combined thrombolysis include rt-PA and urokinase (UK) (18).

Balloon angioplasty (BA) is a commonly used emergency stent operation in clinics, which has high feasibility. It has the advantages of simple operation and minimally invasive operation by penetrating a miniature guide wire into an obstructed blood vessel, expanding the blood vessel with a balloon, and then implanting a stent to maintain the shape of the blood vessel (19). Relevant studies indicate that the operation has a positive impact on the prognosis of AIS patients, but the prognosis of patients using BA alone is often poor, and the probability of a recurrent stroke or death within 30 days is higher than 10% (20), which may be related to arterial elastic retraction, acute thrombus dissection and residual stenosis following the operation. In addition, stent implantation can cause autoimmune reactions in patients with strokes caused by vascular re-blockage (21), which requires close monitoring after surgery and imaging examinations when necessary.

Heck and Brown (22) reported that the incidence of bleeding caused by thrombolytic therapy after emergency internal carotid artery stent implantation was 22%. However, studies by Broeg-Morvay et al. and an earlier study on intra-arterial thrombolysis followed by emergency stenting in patients with acute ischemic stroke suggested that arterial thrombolysis combined with emergency stenting was safe and effective (23-24). Papanagiotou et al. [25] found that compared with intracranial mechanical thrombolysis alone, emergency internal carotid artery stenting combined with thrombolytic therapy can significantly increase the vascular recirculation rate and provide a good prognosis rate. However, this study did not discuss the efficacy and safety of emergency internal carotid artery stenting combined with intravenous thrombolysis during mechanical thrombectomy of tandem occlusion.

The therapeutic effect and health status of AIS patients were evaluated in this investigation between emergency stent surgery coupled with intravenous thrombolysis (study group) and intravenous thrombolysis alone (control group). The findings revealed that, compared with the test group, blood viscosity was reduced, and their cerebral blood perfusion increased significantly, suggesting that emergency stent surgery combined with intravenous thrombolysis can solve the problem of insufficient cerebral blood supply more effectively. Chemerin, BNP, AngII, IL-6, TNF-, and MDA levels in the serum of participants in the tested group were considerably less than in the control group, signifying that the degree of brain injury and the level of body inflammation decreased, while the levels of SOD in the serum were significantly higher. SOD has the effects of reducing oxidative stress injury and repairing nerve injury. Its high expression often indicates a good prognosis for patients [26]. The treatment of AIS is often accompanied by complications. Symptoms such as hemiplegia, language and motor disorders, and the cognitive decline of patients seriously affects the health status of the patients (27). According to the findings of this study, the potential for negative reactions in the test group was much lower than in control group, suggesting that emergency stent surgery combined with intravenous thrombolysis has a higher safety factor. The investigation also evaluated the two groups' NIHSS, Barthel, and mRS scores before therapy, 1 day after treatment, 7 days after treatment, and 14 days after treatment. The finding indicated the test group patients had less NIHSS and mRS scores than those in the control group at 1 day, 7, 14 days after therapy, while the Barthel score was higher, indicating that the patients receiving emergency stent surgery combined with intravenous thrombolysis had lower nerve injuries, stronger independent living ability, and improved health status. In conclusion, emergency stent surgery combined with intravenous thrombolytic therapy has better therapeutic effects on AIS than intravenous thrombolytic therapy alone. After intravenous treatments, the patients' health status is improved, and it can effectively reduce the occurrence of complications, which may provide a clinical basis for emergency treatment of AIS. Therefore, intravenous thrombolysis combined with emergency extracranial stent placement of the internal carotid artery based on mechanical thrombectomy is safe and effective. Due to the nature of the retrospective study cohort and the small sample size of this study, the results of this study need to be further verified by multi-center, randomized controlled studies.

## Acknowledgement

The authors are thankful to the higher authorities for the facilities provided.

## Statements and Declarations

The author declares that no conflict of interest is associated with this study.

**Authors' contribution**

This study was done by the authors named in this article, and the authors accept all liabilities resulting from claims which relate to this article and its contents.

**Conflicts of interest**

There are no conflicts of interest.

**Availability of data and materials**

The data used to support the findings of this study are available from the corresponding author upon request.

**Funding**

No funding received for this study

**References**

1. Gupta R, Gupta P, Gupta S, Garg S. Comparative evaluation to determine the efficacy of conventional radiography, digital radiography and ultrasound imaging in the diagnosis of periapical lesions. *SPR* 2021; 1(3): 38 - 143.
2. Feske, Steven K. "Ischemic Stroke." *The American journal of medicine* vol. 134,12 (2021): 1457-1464.
3. Rabinstein, Alejandro A. "Update on Treatment of Acute Ischemic Stroke." *Continuum (Minneapolis, Minn.)* vol. 26,2 (2020): 268-286.
4. Ueno T, Nishijima H, Hikichi H, et al. Association of survival and hyperthermia after rt-PA for ischemic stroke. *Acta Neurol Scand* 2018; 138(6):574-578.
5. Herpich, Franziska, and Fred Rincon. "Management of Acute Ischemic Stroke." *Critical care medicine* vol. 48,11 (2020): 1654-1663.
6. Silva, Gisele S, and Raul G Nogueira. "Endovascular Treatment of Acute Ischemic Stroke." *Continuum (Minneapolis, Minn.)* vol. 26,2 (2020): 310-331.
7. Toyoda, Kazunori. Intravenous rt-PA therapy for acute ischemic stroke: efficacy and limitations. *Rinsho shinkeigaku = Clinical neurology* vol. 49,11 (2009): 801-3.
8. Behrouz, Réza. "The prospects and predicaments of intravenous rt-PA in childhood ischemic stroke." *Expert review of neurotherapeutics* vol. 14,3 (2014): 255-9.
9. Li, Dan-Dong et al. "Solitaire Stent Permanent Implantation as an Effective Rescue Treatment for Emergency Large Artery Occlusion." *World neurosurgery*, S1878-8750(19)30004-X. 19 Jan. 2019.
10. Cohen, José E et al. "Stent for temporary endovascular bypass and thrombectomy in major ischemic stroke." *Journal of clinical neuroscience : official journal of the Neurosurgical Society of Australasia* vol. 18,3 (2011): 369-73.
11. Ahmed, Syed Uzair et al. "Permanent implantation of the Solitaire device as a bailout technique for large vessel intracranial occlusions." *Journal of neurointerventional surgery* vol. 11,2 (2019): 133-136.
12. Müller MD, Gregson J, McCabe DJH, et al. Stent Design, Restenosis and Recurrent Stroke After Carotid Artery Stenting in the International Carotid Stenting Study. *Stroke* 2019; 50(11):3013-3020.
13. Samaila B, Bello A, Determination of radiation doses received during knee Joint X-ray procedures in Kebbi State, Nigeria, *SPR* 2021; 2(1): 411 - 415.
14. Kumar I, Gautam M, Correlation between individual dietary diversity score and nutrients adequacy ratio in the rural community, *SPR* 2021; 1(4): 229 – 234.
15. Warach SJ, Dula AN, Milling TJ Jr. Tenecteplase Thrombolysis for Acute Ischemic Stroke. *Stroke* 2020; 51(11):3440-3451.
16. Amarenco P, Denison H, Evans SR, et al. Ticagrelor Added to Aspirin in Acute Nonsevere Ischemic Stroke or Transient Ischemic Attack of Atherosclerotic Origin. *Stroke* 2020; 51(12):3504-3513.
17. Muresanu DF, Strilciuc S, Stan A. Current Drug Treatment of Acute Ischemic Stroke: Challenges and Opportunities. *CNS Drugs* 2019;33(9):841-847.
18. Kadooka K, Hagenbuch N, Anagnostakou V, et al. Safety and efficacy of balloon angioplasty in symptomatic intracranial stenosis: A systematic review and meta-analysis. *J Neuroradiol* 2020; 47(1):27-32. d
19. Gemmete JJ, Wilseck Z, Pandey AS, et al. Treatment Strategies for Tandem Occlusions in Acute Ischemic Stroke. *Semin Intervent Radiol* 2020; 37(2):207-213.
20. Zhao Qingshi, Zhu Shuanggen, Zhang Guogao, et al. A case of chronic intracranial occlusion of internal carotid artery treated by balloon angioplasty. *Chinese J Cerebrovasc Dis* 2020; 17(07):408-411.
21. Li L, Tovmasyan A, Sheng H, et al. Fe Porphyrin-Based SOD Mimic and Redox-Active Compound, (OH)FeTnHex-2-PyP4+, in a Rodent Ischemic Stroke (MCAO) Model: Efficacy and Pharmacokinetics as Compared to Its Mn Analogue, (H2O) MnTnHex -2-PyP5+. *Antioxidants (Basel)* 2020; 1;9(6):467.
22. Heck DV, Brown MD. Carotid stenting and intracranial thrombectomy for treatment of acute stroke due to tandem occlusions with aggressive antiplatelet therapy may be associated with a high incidence of intracranial hemorrhage [J] . *J Neurointerv Surg*, 2015 , 7 ( 3 ) : 170-175.
23. Wang Bin, Wang Yabing, Li Shenmao, et al. Treatment of acute ischemic stroke with thrombolysis combined with angioplasty: a single-center study [J]. *Chinese journal of cerebrovascular disease*, 2011,8 (2) : 65-69.
24. Broeg-Morvay A, Mordasini P, Slezak A, et al. Does antiplatelet therapy during bridging

- thrombolysis increase rates of intracerebral hemorrhage in stroke patients? [J] . *PLoS One*, 2017, 12 (1) .
25. Papanagiotou P, Hausen DC, Turjman F, et al. Carotid stenting with antithrombotic agents and intracranial thrombectomy leads to the highest recanalization rate in patients with acute stroke with tandem lesions [J] . *JACC Cardiovasc Interv*, 2018, 11 (13) : 1290-1299.
26. Ma Haoyuan, Zhao Yan, Hu Ming, et al. Comparison of direct thrombus aspiration and stent thrombectomy through SOFIA distal access in the treatment of early acute ischemic stroke. *Chinese Journal of Neuropsychiatry* 2020; 46(04):216-220.
27. Yuanli G, Ying T, Jie I, Quanyan Z, Rongyu C, Expression of eIF3A and eIF4E in ovarian cancer and its relationship with prognosis, *SPR* 2021; 2(1): 416 – 420