

# MASS TREATMENT OF ONCHOCERCIASIS WITH IVERMECT AT BEBEKA COFFEE PLANTATION IN ETHIOPIA

## I. Operational aspects for drug distribution and adverse reactions observed.

Tesfaye Bulto\*,BSc.,MD,MPH, Wondimu Workineh\*\*,BSc,  
Seyoum Taticheff\*, BSc.,MSc.,PHD, Amha Kebede\*,BSc, and Dejene Tilahun\*

**ABSTRACT:** A longitudinal study of mass treatment of onchocerciasis with ivermectin is going on at Bebekka Coffee Plantation in Ethiopia. In this paper we report findings of a pilot study conducted at the initial stage of the project to assess safety and feasibility of launching mass-therapy using this drug. Of 2083 persons examined between 23 and 30 April 1990, in two sub-localities, Berhane and Olme, in Bebekka Coffee Plantation, 826 (39.7%) persons were diagnosed as cases of onchocerciasis by clinical and skin snip examinations. Ivermectin was then administered to 640 persons eligible for treatment. Following treatment no severe adverse reactions were observed and only 51 cases, (8%), sought treatment for mild to moderate mazzoti type reactions and 7 of them (1%) had temporary incapacitation. In addition, 27 cases were systematically selected, among those treated on the first and second day, and examined daily for 4 days and pattern of adverse responses were noted. Over all therapy was well accepted.

## INTRODUCTION

The presence of onchocerciasis (river blindness) in Ethiopia was first confirmed from Keffa Administrative Region in 1939 by Italian scientists (1). It is now estimated that more than one million people are suffering from this disease (2), mainly in the southern and north-western part of the country (Fig.1). The major vector *Simulium damnosum* S.I. and members of this species complex are however widely distributed even outside the onchocerciasis belt (3).

Large scale development activities are being established in onchocerciasis endemic areas of the country. Therefore, control of this and other tropical diseases should be an important component of the development endeavour in these areas. Ivermectin, the new microfilaricide, has been shown to result in a prolonged reduction in microfilarial density and once or twice yearly administration of this drug in mass therapy programme either alone or in combination with vector control measures is considered to be a possible strategy for interrupting transmission (4,5,6).

Studies targeted at measuring the effect of regular community-based administration of single doses of ivermectin with respect to long term adverse effect, reduction in morbidity and transmission are underway in many African countries (7).

Similarly, studies on the long term impact of ivermectin on microfilarial load, morbidity as well as the determination of

---

\* National Research Institute of Health

\*\* Bebekka Coffee Plantation Enterprise

frequency of treatment are also presently undertaken by the Ethiopian National Research Institute of Health (NRIH).

In this paper observations made concerning adverse reactions and safety of ivermectin (mectizan), in the population at Bebek Coffee Plantation Enterprise in Keffa Administrative region in Ethiopia is reported and operational aspect of drug distribution is discussed.

## STUDY AREA AND POPULATION

Bebek Coffee Plantation is found in Keffa Administration, 590 kms south west, from Addis Ababa.

The area has an altitude of 900 to 1000 m and annual rainfall of about 1728 mm. According to the census taken by the health center in Bebek in January 1990 the total population is 18,884.

There are 5 farm sites and most workers live in apartments built by the project. All houses are numbered. Under the supervision of a central clinic, there are health stations at each farm site and health care is given free of charge.

## METHODOLOGY

Of the 5 farm sites, Berhane and Olme-Gojeb were selected for this study, because of the availability of a relatively well organized health facility to handle possible reactions.

About 50 households were asked to come to the clinics per day and all persons reporting to the clinics were registered and subjected to skin snip examination for microfilariae. They were then presented to a physician for clinical examination and determination of eligibility for treatment.

Clinical diagnosis was made after examining skin lesions and checking for the presence of elephantiasis, hydrocele, hanging groin and nodules. Ophthalmologic examination was not included since a previous study by an ophthalmologist did not indicate presence of eye lesions attributable to onchocerciasis in the area.

Examination for the presence of *Onchocerca* microfilaria was made by skin snip biopsies taken from both buttocks using Holth type punches. Previous observation (8) has shown that the buttocks are the best anatomical parts for sniping in Bebek. The snips were weighed on a torsion balance and then immersed in 0.5 ml of physiological saline in microtitre plate wells and kept closed for a maximum of four hours. Microscopic examination was done under dissecting microscope and the microfilarial count was recorded.

Those positive for onchocerciasis either by skin snip examination or clinically or by both methods and eligible for treatment were provided with a treatment card and asked to return to the clinic next morning fasting, to receive treatment.

Before administering the drug they were told about the disease and plans of the programme and about the possible adverse reactions following therapy as well as the availability of help for any untoward reactions. They were then weighed and asked to swallow ivermectin (150 micgm/kgm BWT) on the spot.

Data on adverse reactions from all treated were collected by recording the type of complaints for which they returned to the clinic. Among those treated on the first and second day 27 people were systematically selected and followed in-depth for 4 consecutive days.

## RESULTS

The total number of persons examined was 2083, and male to female ratio was 100/74. According to the 1990 census, male to female ratio of the population in the area was 100/77.

The overall prevalence rate of onchocerciasis in the two villages was 39%. Of the total 826 persons determined as cases 17% and 53% were positive clinically and by skin snip examination, respectively, while 30% were positive both by skin snip examination and clinically. It should be noted that fewer women and children were positive both clinically and by skin snip examination (Table 1).

Of those determined as cases, 85% of the males and 58% of the females received treatment. Among the untreated cases 111 (13.4%) were the illegible ones and of the eligible also 75 persons (10%) did not appear for treatment. Reasons for the illegibility were lactation, pregnancy, age (<5 years) and illnesses.

8% of the total cases treated with

Table 1. Number of persons diagnosed as cases of onchocerciasis by age, sex and methods of diagnosis

Age group	Sex	No. Diagnosed	Percent Positive			
			SS* (a)	Clinical (b)	Both a & b	Total
<5	Male	2	100	0	0	100
	Female	5	80	20	0	100
5-14	Male	26	80	12	8	100
	Female	18	78	6	16	100
15-44	Male	541	44	17	39	100
	Female	175	74	17	9	100
45+	Male	48	40	19	41	100
	Female	11	55	35	10	100
Total	Male	617	46	17	37	100
	Female	209	73	18	9	100
Total	Male & Female	826	53	17	30	100

\*SS = Skin Snip

ivermectin, (i.e. 10%, 6%, and 9% of those diagnosed clinically, by skin snip examination and both, respectively) returned to the clinic seeking treatment for various types of adverse reactions (Table 2). Most of them responded well to Aspirin and/or Antihistamine therapy and only 7 (1%) persons required 3 to 5 days sick leave.

Table 3 shows pattern of adverse reaction recorded through the four day follow up of the 27 cases treated on the first and second day of the mass therapy. In addition, 6 of them (22%) expelled adult ascaris after the ivermectin treatment. Most of the reactions lasted less than 4 days.

## DISCUSSION

Ivermectin a macrocyclic lactone produced by an actinomycete, *Streptomyces avermetilis*, introduced first as an antiparasitic agent in livestock (4), has undergone extensive trials, including comparative (9-12) and dose finding studies (13-15) in onchocerciasis patients. According to these studies ivermectin has been found to have important properties that make it suitable for mass treatment, and for many reasons it is found superior to formerly used drugs, such as Diethylcarbamazine (DEC) and Suramin. Ivermectin is given in a single dose but DEC is given over an extended period and Suramin requires parenteral administration. The mazzoti type reactions are milder in ivermectin and it causes no damage to the eye while ocular changes have been associated with DEC (9,16). The dermal microfilarial density remains low for a longer time after ivermectin therapy than with DEC (9-13).

It is also established that ivermectin does not kill the adult worm but inhibits production of new microfilariae for several months and retreatment every 6 or 12 months is necessary (17). For this reason besides study of the safety of the long term use of ivermectin, cost effective methods of its delivery needs to be determined.

Major options for the distribution of the drug in community-based therapy of onchocerciasis are 1) to treat skin snip positive cases only, 2) to treat skin snip positives and clinically suspected cases, 3) to treat entire population except the illegible ones.

The options involving skin snip examination would be expensive and time consuming, and a significant proportion of infected individuals, especially those with low microfilarial densities could be missed (8,18). This study has shown that among those who had mazzoti type reaction, there were those diagnosed on clinical bases only (Table 3), which indicates that they were false negatives.

The prevalence rate of onchocerciasis in Bebek is very low in women and children but

Table 2. Persons treated for adverse effect of ivermectin by method of diagnosis

Types of Reaction	Clinical n=10		Skin Snip n=20		Both n=21		Total n=51	
	No	%	No	%	No	%	No	%
Pruritis	8	80	7	35	14	67	29	57
Oedema	4	40	8	40	8	38	20	39
Headache	1	10	4	20	1	5	6	12
Vomiting	1	10	2	10	2	10	5	10
Dizziness	2	20	2	10	4	19	8	16
Myalgia	2	20	7	35	5	24	14	27
Diarrhea	0	0	1	5	2	10	3	6
Other	1	10	2	10	1	5	4	8

high among the males above 15 years of age (8). Accordingly, male field workers, who are nearly 40% of the total population, could receive mass treatment. The risk associated with ivermectin administration in uninfected individuals, especially adult males, is minimal, since most side effects are caused by the death of the microfilariae. On the other hand, some individuals will benefit from its deworming effect.

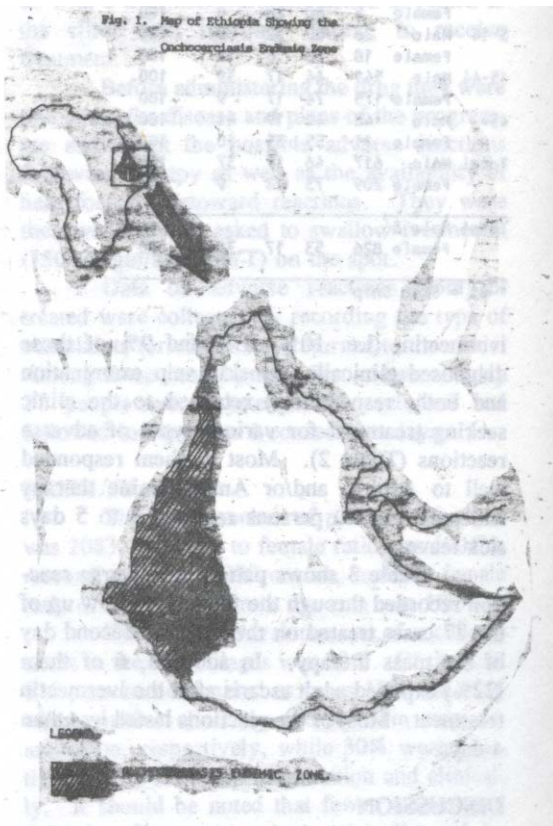
Table 3. Adverse effects recorded during first 4 days on 27 onchocerciasis patients treated with mectizan

Type of	Before treatment	1st day	2 day	3rd day	4th day
Pruritis	5	12	10	7	-
Myalgia	4	8	9	4	2
Dizziness	1	9	6	3	-
Headache	1	5	6	1	-
Oedema Facial or Peripheral	-	7	9	5	2
Abdominal pain	3	4	5	3	1
Nausea	-	4	2	-	-
B/P lowered	-	2	3	-	-
Temp. increased	-	-	3	-	-

In this study it has been shown that most reactions occur on the next day of the therapy. Therefore, if the drug is given to field workers on Fridays or Saturdays it is possible to minimize the number of workers requiring leave for the visit to the clinic and the temporary incapacitation seen in some patients after therapy. Screening by skin snip examination, would however be imperative in children and women because, besides the prevalence rate being low, most of the contraindications also concern these sectors of the population.

The safety of a drug and its acceptance by the community is very important for the success of a mass therapy. Adverse reactions observed in this study are similar to those observed elsewhere (7). The mild to moderate reactions and the deworming effect of ivermectin have rather demonstrated its effect in a short period and its acceptance by the community had been clearly observable in the study area.

Subsequent reports will be given on further findings of this on-going study and it is hoped that after obtaining more experience on the cost-effective methods of delivering treatment and determining optimal retreatment interval an extended treatment programmes will be launched in collaboration with the health services in the endemic areas of the country.



## ACKNOWLEDGEMENT

This investigation received support from the UNDP/World Bank/WHO Special Programme for Research and Training in Tropical Diseases. We sincerely thank the Merk Sharp Dohme for providing us with Mectizan free of charge.

## REFERENCES

1. Iacono I., Giaquinto-Mira M., Bucco G. Primi reperti de Onchocercosi in A.O.I. *Archiro Italiana disienze Mediche Coloniali*. 1940. 21, 49-58.
2. Zein A.Z. Onchocerciasis in *The ecology of Health and Diseases in Ethiopia*. (eds. Zein Ahmed Zein and H.Kloos) Ministry of Health, Addis Ababa, 1988. 166-176.
3. Mebratu Y., Abebe M. and Mekuria Y. Blackflies (Diptera: Simuliidae) of Ethiopia: Checklist and distribution, *Sinet Eth. J. Sci.* 1979. 3, 1-20.
4. Cambell W.C. Ivermectin: An update, *Parasitology Today*. 1985. 1 (1): 10-18.
5. Aziz M.A. Chemotherapeutic approach to control of onchocerciasis. *Rev. Infect Dis.* 1986. 8:500-504.
6. Taylor HR, Greene BM. The status of ivermectin in the treatment of human onchocerciasis. *Am. J. Trop. Med. Hyg.* 1989. (4): 460-6.
7. Report of a meeting of the TDR/OCP/OCT subcommittee for monitoring of community trials of ivermectin. Ouagadougou, Burkina Faso, 25-27 January 1989.
8. Taticheff S., Abebe M., Workineh W., Hanna G.N. Onchocerciasis: A prevalence study in Bebeke, Ethiopia. *Trop. Med. Parasit.* 1987. 38: 279-282.
9. Lariveience M., Vingtain P., Aziz MA., Beauvais B., Weimann D., Derouin F., Ginoux J., Schulz-Key H., Gaxotte P., Basset D. and Sarfati C. Double-blind study of ivermectin and DEC in African onchocerciasis Patients with Ocular involvement. *Lancet*. 1985. ii. 147-177.

10. Greene B.M., Taylor H.R., Cupp E.W., Murphy R.P., White A.T., Aziz M.A., Schulz-Key H., D'Anna S.A., Newland H.S., Goldschmidt L.P., Auer C., Hanson A.P., Vaani Freeman S., Reber E.W. and William P.N. Comparison of ivermectin and Diethylcarbamazine in the treatment of Onchocerciasis. *N. Engl. J. Med.* 1985. 313:133-138.
11. Awadzi K., Dadzie KY., Schulz-Key H., Gilles HM., Fulford AJ. and Aziz MA. The Chemotherapy of Onchocerciasis XI: Double-blind Study of ivermectin, DEC and Placebo in human onchocerciasis in Northern Ghana. *Ann. of Trop. Med. Parasit.* 1986. 80: 433-442.
12. Diallo S., Aziz MA., Lariviere M., Diallo JS., Diop-Mar I., N'Dir O., Bwadiane S., Py D., Schulz-Key H., Goxotte P. and Victorious A. A double-blind comparison of the efficacy and safety of ivermectin and diethylcarbamazine in a placebo controlled study of Senegalese Patients with onchocerciasis. *Trans. Roy. Soc. Trop. Med. Hyg.* 1986. 80: 927-934.
13. Albiensz EJ., Newland HS., White AT., Kaiser A., Greene BM. and Taylor DW. Chemotherapy of onchocerciasis with high dose of diethylcarbamazine or a single dose of ivermectin: microfilaria levels and side effects. *Trop. Med. Parasit.* 1988. 39: 19-24.
14. Awadzi K., Dadzi KY., Schulz-Key H., Haddock DRW., Gilles HM. and Aziz MA. The chemotherapy of onchocerciasis X. An assessment of four single dose treatment regimes of MK-933 (ivermectin) in human onchocerciasis. *Ann. Trop. Med. Parasit.* 1985. 79: 63-78.
15. White AT., Newland H.S., Taylor H.R., Erttmann K.D., Keyvan-Lirijani E., Nara A., D'Anna., William P.N. and Greene B.M. Controlled trial and dose finding study of ivermectin for treatment of onchocerciasis. *The J. Infect. Dis.* 1987. 156: 463-470.
16. Taylor HR., Murphy RP., Newland HS., White AT., D'Anna SA., Keyvan-Larijani E., Aziz MA., Cupp EW. and Greene BM. Treatment of onchocerciasis. The ocular effect of ivermectin and diethylcarbamazine. *Arch. Ophthalmol.* 1986. 104: 863-70.
17. Coulland JP., Lariviere M., Aziz MA., et al. Ivermectin in onchocerciasis. *The Lancet.* 1984. 2: 526-527.
18. Taylor HR., Munoz B., Keyvan-Larijani E. and Greene BM. Reliability of detection of microfilariae in skin snips in the diagnosis of onchocerciasis. *Am. J. Trop. Med. Hyg.* 1989. 41 (4): 467-71.

