

Electroencephalographic patterns in Ethiopian patients with epilepsy: A retrospective review

Birrie Deresse¹, Getahun Mengistu¹, Guta Zenebe¹, Mehila Zebenigus², James C. Johnston³

Abstract

Background: Epilepsy is a common problem throughout sub-Saharan Africa, including Ethiopia. Electroencephalography (EEG) is useful for the diagnosis and proper treatment of this condition. However, the literature is scanty of reports describing EEG patterns in Ethiopian patients with epilepsy. This study attempts to bridge that gap and provide a baseline for further research into the etiological basis of specific epileptiform abnormalities.

Objective: To review EEG patterns in Ethiopian patients with epilepsy.

Methods: We retrospectively reviewed EEG records of patients with epilepsy presenting to a specialized referral hospital (Addis Ababa University Tikur Anbessa Teaching Hospital) and a private clinic (Yehuleshet Higher Clinic) between September 2008 and August 2010.

Results: Two hundred and fifty one patients with mean age of 26 years (SD 14.8) and 1.2:1 male: female ratio was included in the study. One hundred and forty nine patients (59.4%) harbored EEG abnormalities. The majority of these abnormalities 61.1% were epileptiform discharges; the remainder 38.9% being nonspecific patterns. The most common epileptiform discharges were focal, with or without secondary generalization in 63.7%. These focal discharges originated from the left cerebral hemisphere in 43.1% cases and the right in 39.7%; 17.2% were bilateral. Multifocal cerebral and temporal lobe discharges accounted for 43.1% and 39.7% of all focal discharges, respectively.

Conclusion: The most common EEG abnormalities in Ethiopian patients with epilepsy are focal interictal epileptiform discharges, typically originating from multifocal cerebral loci and the temporal lobe, without hemispheric lateralization. It provides a foundation for prospective studies to address the etiological basis of focal abnormalities. [*Ethiop. J. Health Dev.* 2012;26(2):101-106]

Introduction

Epilepsy is a brain disorder characterized by the enduring predisposition for recurrent unprovoked seizures and all of the attendant neurobiological, cognitive, psychological, and social consequences (1). It is a worldwide public health problem with an estimated global prevalence approximating 8 per thousand populations (2). The reported prevalence in Ethiopia comports with this figure (3, 4). Other studies in developing countries document an extraordinarily high prevalence exceeding these numbers by a magnitude of seven (exceeding 15 per thousand populations) (5).

On a single wake EEG, 29-56% of adults with epilepsy have one or more interictal epileptiform discharges. This increases to 59-92% with repeated testing including sleep recording, but there is minimal additional yield beyond four studies (6-9). EEG performed within the first 24-48 hours following a seizure detects epileptiform abnormalities in 51% of patients, compared with 34% at later times (10). Sleep deprivation for 24 hours increases the yield of interictal epileptiform discharges by 20% or more (11, 12). Activation procedures including hyperventilation and intermittent photic stimulation further increase the likelihood of detecting epileptiform abnormalities.

EEG evidence of interictal epileptiform discharges helps differentiate between epileptic seizures and nonepileptic paroxysmal attacks. Epileptiform EEG patterns include spikes, polyspikes, sharp waves, spike wave complexes, slow spike-wave complexes, 3-Hz spike-wave complexes, hypsarrhythmia and status (9, 13). An interictal epileptiform discharge is defined as (i) paroxysmal, readily distinguished from background activity; (ii) sharp in appearance due to a rapid change in polarity; and (iii) of short duration, with a spike being less than 70 msec and a sharp wave between 70-200 msec. A community-based epidemiological study of neurological disorders in rural Ethiopia identified 316 persons with epilepsy. Seventy three percent of these had EEG done; 18% demonstrated epileptiform activity (14). A West African study documented EEG abnormalities in 64.4% of patients with epilepsy (15). Several studies document interictal epileptiform discharges occurring more frequently over the left cerebral hemisphere than the right (16-20).

The objective of this study is to review EEG patterns in Ethiopian patients with epilepsy, which will aid in the classification and management of this disorder. The data on EEG patterns in the Horn of Africa is scanty and this

¹Department of Neurology, School of Medicine, Addis Ababa University, Addis Ababa, Ethiopia;

² Assistant Professor of Neurology (Hon), Department of Neurology, School of Medicine, Addis Ababa University, and Consultant Neurologist, private practice, Yehuleshet Higher Clinic, Addis Ababa, Ethiopia;

³Professor of Neurology (Hon), Department of Neurology, School of Medicine, Addis Ababa University, Addis Ababa, Ethiopia; Consultant Neurologist and Attorney, private practice, Seattle, WA, USA.

study could provide a foundation for further research into the etiological basis of specific epileptiform abnormalities.

Methods

The EEG records of 251 patients with epilepsy presenting to Addis Ababa University Tikur Anbessa Teaching Hospital and Yehuleshet Higher Clinic in Addis Ababa, Ethiopia between September 2008 and August 2010 were retrospectively reviewed. Medical records provided the demographic and clinical data. The recordings were performed on a 16-channel digital Nicolet Biomedical EEG machine using the International 10-20 system with simultaneous ECG recording. Interictal EEG recordings were performed with the patient awake. Recordings were 20 to 30 minutes long, including hyperventilation for 3 minutes and intermittent photic stimulation. Two neurologists independently interpreted each EEG. If the interpretations differed, then a third neurologist was consulted. These neurologists were trained in electrophysiology or experienced in EEG reading for ten or more years. The EEG was included in the study only if all three neurologists concurred after review and discussion of the record. Each EEG was classified as normal or abnormal, the latter categorized as either epileptiform (spikes, sharp waves, spike and wave complexes) or with non-specific abnormalities (focal slowing, generalized slowing). EEGs with epileptiform discharges were labeled as focal, focal with secondary generalization or primarily generalized discharges. Cerebral hemisphere and cortical lobe of origin of the focal epileptiform discharges were analyzed.

Statistical analysis: Data were analyzed with the SPSS for Windows Evaluation Version 15.0. Continuous data are presented as mean \pm SD and categorical data are as frequencies and percentages. Chi-square (χ^2) test and bivariate analysis were used as appropriate. A two-sided P value of < 0.05 was considered significant.

Ethical issues: Protocol approval was obtained from the Research Ethics and Evaluation Committee of the Department of Neurology, School of Medicine, Addis Ababa University.

Results

Two hundred and fifty one patients with epilepsy having a mean age of 26.2 ± 14.8 years (ranging 2-75 years) with 1.2:1 male to female ratio were included in this study. Majority (57.4%) of the patients were between ages 10 and 29 years. (Table 1).

Table 1: **Demographic Data of 251 Patients with Epilepsy at Tikur Anbessa Teaching Hospital and Yehuleshet Higher Clinic**

Characteristics	No	%
Age (years)		
0-9	19	7.6
10-19	81	32.3
20-29	63	25.1
30-39	48	19.1
40-49	19	7.6
50-59	10	4.0
60+	11	4.4
Sex		
Male	134	53.4
Female	117	46.6
Location		
Right	224	89.2
Left	4	1.6
Not mentioned	23	9.2

Out of the total, 186 (74.1%) patients were classified by seizure type; the remaining were not specified (Table 2). One hundred and forty nine of 251 (59.4%) of EEG records were abnormal. Most of the abnormalities (61.1%) were interictal epileptiform discharges; the remainder (38.9%) being nonspecific patterns. The most common epileptiform discharges (63.7%) were focal, with or without secondary generalization. Primarily generalized epileptiform discharges including 3Hz spike-wave and status pattern occurred in 36.3% of the cases (Tables 2 and 3).

Table 2: **EEG findings according to clinical diagnosis, Tikur Anbessa Teaching Hospital and Yehuleshet Higher Clinic, 2011**

Clinical diagnosis	EEG finding							Total	
	Normal	Focal ED	Focal 2° ED	Primary GED	3 Hz	Status pattern	Non-specific	No	%
Seizure type not specified	23	10	1	13	0	1	17	65	25.9
Focal Seizure	30	16	3	2	0	0	13	64	25.5
2 nd ry GTCS	28	11	2	4	0	0	16	61	24.3
Primary GTCS	10	12	3	8	1	0	11	54	21.5
Absence	2	0	0	0	3	0	0	5	2.0
2 nd ry GTCS + Absence	0	0	0	0	1	0	0	1	0.4
PGTCS+ Myoclonic	0	0	0	0	0	0	1	1	0.4
Total	102	49	9	27	5	1	58	251	100.0
(%)	(40.6)	(19.5)	(3.6)	(10.8)	(2.0)	(0.4)	(23.1)		

ED=epileptic form discharges;
GTCS=generalized tonic clonic seizure;

GED=generalized epileptiform discharges
PTCS=primary generalized tonic clonic seizures

Table 3: EEG Abnormalities According to age (n=149), Tikur Anbessa Teaching Hospital and Yehuleshet Higher Clinic, 2011

EEG abnormalities	Age group (years)							Total	
	0-9	10-19	20-29	30-39	40-49	50-59	60+	No	%
Epileptiform discharges	11	37	16	14	5	4	4	91	61.1
Focal	4	17	7	9	5	3	4	49	53.8
Secondarily generalized	0	6	2	1	0	0	0	9	9.9
Primarily generalized	4	12	6	4	0	1	0	27	29.7
3Hz	2	2	1	0	0	0	0	5	5.5
Status pattern	1	0	0	0	0	0	0	1	1.1
Non-specific abnormalities	5	18	9	14	6	2	4	58	38.9
FIS	2	6	5	7	4	1	3	28	48.3
GIS	1	4	2	2	0	0	0	9	15.5
GS	1	7	1	4	1	1	1	16	27.6
FIRDA	1	0	1	0	1	0	0	3	5.2
OIRDA	0	1	0	0	0	0	0	1	1.7
Generalized fast activity	0	0	0	1	0	0	0	1	1.7
Total (%)	16	55	25	28	11	6	8	149	100.0
	(10.7)	(36.9)	(16.8)	(18.8)	(7.4)	(4.0)	(5.4)		

3Hz+Generalized 3-Hz spike-wave complexes, FIRDA = Frontal intermittent rhythmic delta activity, OIRD = Occipital intermittent rhythmic delta activity, FIS = Focal intermittent slowing, GIS = Generalized intermittent slowing, GS = Generalized slowing

Of 186 patients clinically classified into the different epileptic seizure types, 66 (35.5%) had epileptiform discharges. Out of the 66 epileptics, there was agreement between the clinical and EEG diagnosis in 45 (68.2%). There was some association between the clinical classification and the EEG classification of epileptic patients ($X^2 = 7.4$, $N=66$, $P=0.007$) but the chance corrected agreement of kappa score 0.32 was low (Table 4). Sixteen of 21 patients with focal seizures (76.2%) had EEG findings of focal epileptiform discharges. By contrast, only 2 of 17 patients harboring focal seizures with secondary generalization had corresponding EEG abnormalities. Eight of 24 patients (33.3%) with primary generalized tonic-clonic seizures had primarily generalized epileptiform discharges on EEG examination. Four of the six clinically diagnosed absence seizure cases had generalized 3-Hz spike-wave

complexes, the typical EEG finding of absence seizure.

Of the 58 EEG records demonstrating focal epileptiform discharges (with or without secondary generalization), 25 (43.1%) originated from the left cerebral hemisphere, 23 (39.7%) from the right and 10 (17.2%) were bilateral. The origins of these focal epileptiform discharges were multifocal, temporal, frontal and central in 43.1%, 39.7%, 15.5% and 1.7%, of the cases, respectively (Table 5).

About 90% of the 251 epileptic patients were put on single drug therapy and the majority (77.3%) were on either phenobarbitone or carbamazepine, the old generation anti-epileptics (Figure 1).

Table 4: Electroencephalographic Versus Clinical Diagnosis of Epileptics, Tikur Anbessa Teaching Hospital and Yehuleshet Higher Clinic, 2011, N=66

Clinical diagnosis	EEG diagnosis according to EEG pattern			X^2	P-value	Kappa score
	Focal epileptiform discharges with or without secondary generalization Frequency (%)	Primarily Generalized Epileptiform Discharges Frequency (%)	Total Frequency (%)			
Focal seizure with or without secondary generalization	32 (48.5)	6 (9.1)	38 (57.6)	7.4	0.007	0.32
Primarily generalized	15 (22.7)	13 (19.7)	28 (42.4)			
Total	47 (71.2)	19 (28.8)	66 (100.0)			

Table 5: **Cerebral Hemisphere or Cortical Origin of Focal Epileptiform Discharges, with or without Secondary Generalization, Tikur Anbessa Teaching Hospital and Yehuleshet Higher Clinic, 2011**

Cerebral hemisphere	No.	%	P = 0.77
Left	25	43.1	
Right	23	39.7	
Bilateral	10	17.2	
Total	58	100	
Cerebral cortex lobe			
Central	1	1.7	
Primarily frontal	9	15.5	
Primarily temporal	23	39.7	
Multifocal	25	43.1	
Total	58	100.0	
Multifocal			
	No	%	
Frontal + Temporal	12	48.0	
Bifrontal	3	12.0	
Bitemporal	2	8.0	
Centro - temporal	2	8.0	
Centro - parietal	2	8.0	
Temporal + Parietal	1	4.0	
Temporal + Occipital	1	4.0	
Temporal + Parietal + Occipital	1	4.0	
Fronto-central	1	4.0	
Total	25	100.0	

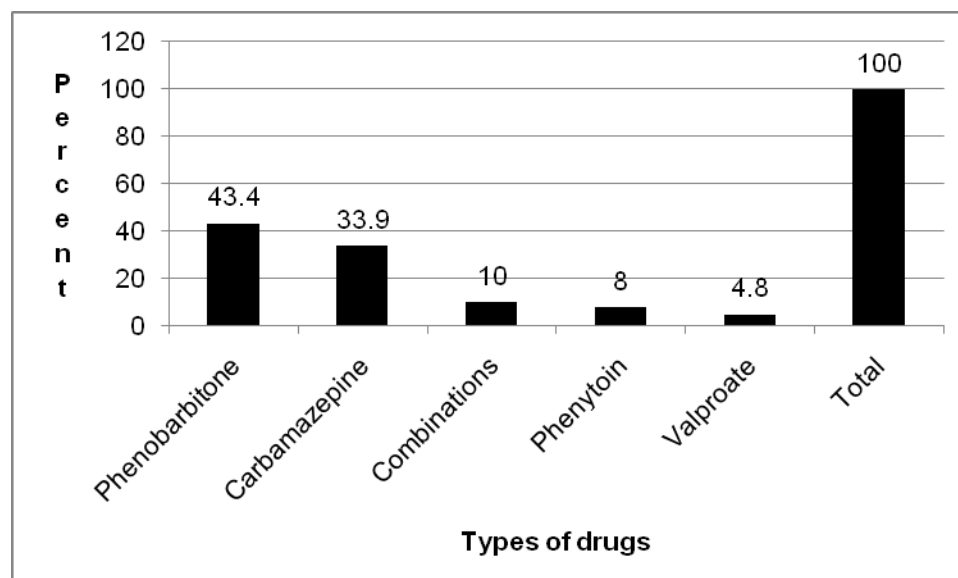


Figure 1: **Treatment of 251 epileptics at Tikur Anbessa Hospital and Yehuleshet Higher Clinic, 2011**

Discussion

The diagnosis of epilepsy is primarily based on careful clinical observation although EEG is a valuable investigative tool. In the advent of more sophisticated neuroimaging methods, epilepsy remains one of the few common clinical problems routinely demanding EEG evaluation although it serves a very useful role both in the diagnosis and proper management by (i) allowing localization of a seizure focus; (ii) permitting classification of the epilepsy syndrome; (iii) determining prognosis for recurrence after a single unprovoked seizure; and (iv) assessing the likelihood of seizure recurrence following antiepileptic drug withdrawal (9, 13, 21-23).

EEG abnormalities were recorded in 59.4% of epileptic patients in this study, which is comparable to 64.4% in a west African study (15). Most of the EEG abnormalities (61.1%) were epileptiform discharges. The most common epileptiform discharges were focal, with or without secondary generalization (63.7%). This is consistent with other African studies (16). Focal epileptiform discharges may indicate a secondary etiology for epilepsy and warrant further investigation. Over 60% of the focal epileptiform discharges, with and without secondary generalization, occurred in patients under 30 years of age. The retrospective nature of our study precludes etiological analysis of the epilepsy in this group. Further studies are warranted to address the relationship between secondary epilepsy and various cerebral injuries

including head injury and childhood central nervous system infections.

Classification of epilepsy is based on the clinical picture and EEG characteristics of one or more seizures. EEG is also important for follow up of epileptics, choice of anti-epileptics, discontinuation of treatment, confirmation of brain death in patients in coma. Studies in sub-Saharan Africa demonstrate a preponderance of generalized tonic-clonic seizures (~60%), which is probably secondary to improper seizure classification. (14, 24). There are a host of impediments to the proper diagnosis and classification of a seizure in sub-Saharan Africa. Patients and bystanders are generally uneducated and have limited ability to accurately describe an aura or recognize the partial onset of a focal seizure. Moreover, the patient with a secondary generalized seizure may have no recollection of the event. Clinical classification was not specified in a quarter of the cases in this study. Ethiopians traditionally associate seizures with evil spirits and superstitions condition impeding any reasonable history (25). Epilepsy is considered contagious in many parts of rural Ethiopia, and bystanders are not willing to assist and even shun victims. This makes difficult the extraction of adequate history of epileptic patients which is crucial for its diagnosis and classification as well as management of epilepsy in general and seizures in particular. These problems are compounded by the lack or severely limited EEG services. The only available equipment in Ethiopia is in the capital Addis Ababa. Thus, the vast majority of patients with seizures are treated solely on the basis of an incomplete or distorted clinical picture.

In this study, for example, 62.5% of the patients classified clinically as having a primary generalized tonic clonic seizure (GTCS) disorder actually had focal epileptiform discharges, some with secondary generalization. These focal epileptiform discharges originated from either the right or left cerebral hemisphere in 82.8% of cases, without a significant difference in lateralization; the remaining interictal discharges were bilateral. This finding contrasts with earlier studies suggesting a left hemispheric predominance of epileptogenicity (16-20, 26).

The focal epileptiform discharges in our study population originated from the following regions in descending order of frequency: multifocal regions, temporal lobe and frontal lobe. Multifocal cerebral cortex origin of the focal epileptiform discharges suggests diffuse or multiple areas of cerebral insult, and warrant further studies to establish the underlying etiological basis of focal discharges.

It is good that about 90% of epileptics were on a single drug therapy but the available and affordable drugs in this country are old generation anti-epileptics, with all their drawbacks of dulling the intellect and cognitive impairments. All of these drugs except valproic acid have

drug - drug interactions when combined or given with other medications.

Conclusion

The most common EEG abnormalities in Ethiopian patients with epilepsy are focal interictal epileptiform discharges, typically originating from multifocal cerebral loci and the temporal lobe, without hemispheric lateralization. We feel this provides a foundation for prospective studies to address the etiological basis of focal abnormalities. We recommend a well designed community based study.

Limitations of the study

This study was a retrospective review and we didn't measure the inter-rater reliability among neurologists who interpreted the EEG recordings.

Acknowledgements

To the Research Ethics and Evaluation Committee of the Department of Neurology, School of Medicine, Addis Ababa University for permitting the study. We thank Sr. Almaz Tilahun and other staffs at Yehuleshet Higher clinic, and nurses at the Neurology clinic of Tikur Anbessa Teaching Hospital, Addis Ababa University for their invaluable assistance in searching the patients' chart.

References

1. Fisher RS, Van Emde, Boas W, Blume W, et al. Epileptic seizures and epilepsy: Definitions proposed by the International League Against Epilepsy (ILAE) and the International Bureau for Epilepsy (IBE). *Epilepsia* 2005;46:470-72.
2. World Health Organization, International Bureau for Epilepsy, International League Against Epilepsy. Atlas - Epilepsy care in the world 2005. Geneva: World Health Organization; 2005.
3. Tekle-Haimanot R, Abebe M, Gebre-Mariam M, Forsgren J, Heijbel J, Holmgren G, et al. Community based study of neurological disorders in rural central Ethiopia. *Neuroepidemiology* 1990;9:263-277.
4. Giel R. The problem of epilepsy in Ethiopia. *Tropical and Geographical Medicine* 1970;22:439-442.
5. Senanayake N, Roman GC. Epidemiology of epilepsy in developing countries. *Bull of the WHO* 1993; 71:247-258.
6. Ajmone Marsan C, Zivin LS. Factors related to the occurrence of typical paroxysmal abnormalities in the EEG records of epileptic patients. *Epilepsia* 1970;11:361-81.
7. Goodin DS, Aminoff MJ. Does the interictal EEG have a role in the diagnosis of epilepsy? *Lancet* 1984;1(8381):837-839.
8. Salinsky M, Kanter R, Dasheiff RM. Effectiveness of multiple EEGs in supporting the diagnosis of epilepsy: an operational curve. *Epilepsia* 1987;28:331-334.

9. Binnie CD, Stefan H. Modern electroencephalography: its role in epilepsy management. *Clinical Neurophysiology* 1999;110:1671-1697.
10. King MA, Newton MR, Jackson GD, Fitt GJ, Mitchell LA, Silvapulle MJ, et al. Epileptology of the first seizure presentation: a clinical, electroencephalographic, and magnetic resonance imaging study of 300 consecutive patients. *Lancet* 1998;352:1007-11.
11. Mendez OE, Brenner RP. Increasing the Yield of EEG. *J Clin Neurophysiol* 2006;23:282-293.
12. Pillai J, Sperling MR. Interictal EEG and the diagnosis of epilepsy. *Epilepsia* 2006;47 Suppl 1:14-22.
13. Noachtar S, Rémi J. The role of EEG in epilepsy: a critical review. *Epilepsy Behav* 2009;15(1):22-33.
14. Tekle-Haimanot R, Forsgren L, Abebe M, Gebre-Mariam A, Heijbel J, Holmgren G, et al. Clinical and electroencephalographic characteristics of epilepsy in rural Ethiopia: A community based study. *Epilepsy Research* 1990;7:230-239.
15. Ahmed MH, Obembe A. Electroencephalographic abnormalities in 351 Nigerians with epilepsy. *West Afr J Med* 1991 Jul-Dec;10(3-4):216-21.
16. Jowi JO, Kidiga ZP, Gitau MG. A review of Electroencephalograms done at the Kenyatta National Hospital, Nairobi. *East Afr Med J* 2008 Feb;85(2):92-7.
17. Dean A, Solomon G, Harden C, Papakostas G, Labar D. Left Hemispheric dominance of epileptiform discharges. *Epilepsia* 1997;38(4):503-505.
18. Labar D, Dilone L, Solomom G, Harden C. Epileptogenesis: Left or right hemisphere dominance? Preliminary findings in a hospital-based population. *Seizure* 2001;10:570-572.
19. Holmes MD, Dodrill CB, Kutsy RL, Ojemann GA, Miller JW. Is the left cerebral hemisphere more prone to epileptogenesis than the right? *Epileptic Disord* 2001 Sep;3(3):137-41.
20. Loddenkemper T, Burgess RC, Syed T, Pestana EM. Lateralization of interictal EEG findings. *J Clin Neurophysiol* 2007;24:379-385.
21. Sundaram M, Sadler RM, Young GB, Pillay N. EEG in epilepsy: Current perspectives. *Can J Neurol Sci* 1999;26:255-62.
22. Britton JW. Significance of the EEG and epileptiform abnormalities in antiepileptic drug discontinuance. *J Clin Neurophysiol* 2010;27:249-254.
23. Krumholz A, Wiebe S, Gronseth G, Shinnar S, Levisohn P, Ting T, et al. Practice parameter: Evaluating an apparent unprovoked first seizure in adults (an evidence-based review): Report of the Quality Standards Subcommittee of the American Academy of Neurology and the American Epilepsy Society. *Neurology* 2007;69:1996-2007.
24. Preux PM, Druet-Cabanac M. Epidemiology and etiology of epilepsy in sub-Saharan Africa. *Lancet Neurol* 2005;4:21-31.
25. Tekle-Haimanot R, Abebe M, Forsgren L, Gebre-Mariam A, Heijbel J, Holmgren G, et al. Attitudes of rural people in central Ethiopia towards epilepsy. *Soc Sci Med* 1991;32(2):203-209.
26. Doherty MJ, Walting PJ, Morita DC, Peterson RA, Miller JW, Holmes MD, et al. Do nonspecific focal EEG slowing and epileptiform abnormalities favor one hemisphere? *Epilepsia* 2002;43:1593-1595.