

Euphorbia royleana*, a botanical pesticide affects ultimobranchial gland of the catfish *Heteropneustes fossilis

ManiRam Prasad, Abhishek Kumar, Sunil Kumar Srivastav & Ajai K Srivastav

Department of Zoology, D.D.U. Gorakhpur University, Gorakhpur 273009, India

Abstract

Heteropneustes fossilis were subjected to high and low doses of the latex of *Euphorbia royleana* for short-term and long-term exposures, respectively. The blood was analyzed for plasma calcium levels, and the ultimobranchial glands fixed and examined. Serum calcium levels declined after 48 h following short-term exposure, and this decrease continued until the end of the experiment. The ultimobranchial cells exhibited a decrease in the cytoplasmic staining response after 96 h following treatment, and the nuclear volumes slightly decreased. Chronically exposed fish also exhibited a decline in serum calcium levels, but much later, on day 7, again progressively declining until the close of the experiment. Up to day 14 following treatment there was no change in histological structure of the ultimobranchial glands, but then there was a decrease in nuclear volume and the cytoplasm displayed a weak staining response. There was some vacuolization and degeneration.

Keywords: Botanicals, calcitonin, calcium, teleost

Introduction

Botanical pesticides pose little threat to the environment or to human health, and for this reason they have long been touted as attractive alternatives to synthetic pesticides. *Euphorbia royleana* (Euphorbiaceae) is a common plant having molluscicidal and insecticidal properties (Singh & Agrawal 1984, 1990, Abdel-Hamed *et al.* 2003, Tiwari *et al.* 2004). It has analgesic and antipyretic properties in rat and rabbits (Bani *et al.* 1998). *Euphorbia* latex is cathartic, anthelmintic and used for a variety of conditions such as skin and eye diseases and snakebite (Chopra *et al.* 1958, Basak *et al.* 2009). The latex of *Euphorbia royleana* produces an intense conjunctival, corneal and iritic inflammatory reaction (Sood *et al.* 1971). Significant antiarthritic activity has been observed in subacute and chronic models of formaldehyde-induced arthritis, adjuvant-induced developing and established arthritis (Bani *et al.* 1998).

There exists several reports on the impact of environmental toxicants on fish, e.g., histopathology of vital organs (Srivastava *et al.* 1989, 1990, Poleksic & Karan, 1999, Kumar *et al.* 2010a), behavioural responses (Prasad *et al.* 2009, Srivastava *et al.* 2010), hematological anomalies (Harikrishnan *et al.* 2009, Kumar *et al.* 2010b, 2010c, Prasad *et al.* 2010a,b, Rai *et al.* 2010), but there exists no information regarding the impact of botanical pesticides (excluding synthetic pyrethroids) on the ultimobranchial gland of fish, an endocrine gland responsible for secretion of a hypocalcemic factor – calcitonin.

Thus the present investigation studied the effect of a botanical pesticide, the latex of *Euphorbia royleana*, on the serum calcium and histological changes in the ultimobranchial gland of a freshwater catfish, *Heteropneustes fossilis*.

Materials & Methods

Adult freshwater teleost *Heteropneustes fossilis* (both sexes, body weight 27–38 g) were collected locally. Healthy fish showing no external signs of injury and disease were selected for experiments and were acclimatized to laboratory conditions (under natural photoperiod;

temperature 27 ± 2 °C; pH 7.3 ± 0.1 ; hardness 168 ± 6 mg/L as CaCO₃; dissolved oxygen 7.9 ± 0.4 mg/L for 15 days in dechlorinated tap water.

In the present study, the latex of *Euphorbia royleana* was used, which has a 96-h LC₅₀ value of 3.090 mg/L for *H. fossilis* (Prasad *et al.* 2010c). For short-term exposure, the fish were subjected to 2.47 mg/L of latex (80% of the 96-h LC₅₀ value), while for the long-term exposure experiment the fish were subjected to 0.618 mg/L (20% of the 96-h LC₅₀ value). Simultaneously, a control group was also run for comparison, using tap water containing ethanol. Fish were kept in groups of 10 in 40 L media. Latex of *Euphorbia royleana* was weighed and a stock solution (4 mg/ml) prepared in 100% ethanol. Six fish were sacrificed at each time interval from control and experimental groups after 24, 48, 72 and 96 h in the short-term experiment, and after 7, 14, 21 and 28 days in the long-term experiment.

Blood samples were collected by sectioning of the caudal peduncle of fish. The sera were separated by centrifugation at 3500 rpm and analyzed for calcium levels (calcium kit, RFCL Limited India). After the collection of blood samples, the area adjoining the heart along with the oesophagus were removed and fixed in aqueous Bouin's fluid. Fixed tissues were routinely processed in a graded series of alcohols, cleared in xylene, and then embedded in paraffin wax. Serial sections were cut at 6 µm and stained with hemotoxylin-eosin (HE).

Nuclear indices (maximal length and maximal width) of ultimobranchial cells (50 nuclei per specimen; thus 300 nuclei were measured from six specimens) were taken with the aid of an ocular micrometer, and then the nuclear volume calculated as $\text{volume} = \frac{4}{3} \pi ab^2$, where 'a' is the major semiaxis and 'b' is the minor semiaxis.

All samples were estimated in duplicate. All data are presented as the mean \pm S.E. of six specimens and Student's 't' test used for the determination of statistical significance. In all studies, the experimental group was compared to the control group at the same time period. Two-way Analysis of Variance (ANOVA) was used for multiple group comparisons.

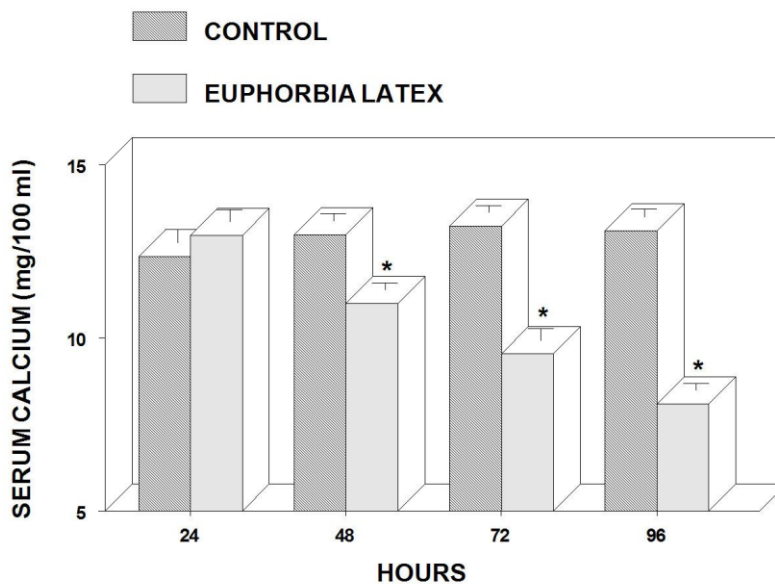


Fig. 1: Serum calcium levels in the fish *Heteropneustes fossilis* exposed over the short term to high concentrations (80% of 96-h LC₅₀) of the latex of *Euphorbia royleana*. Values are mean \pm SE of six specimens. Asterisks indicate significant differences ($p < 0.05$) from the control group.

Results

In the short-term experiment, no alteration was noticed in the serum calcium levels of *H. fossilis* at 24 h following exposure to *Euphorbia royleana* latex. The levels then progressively decline from 48 h to 96 h (Fig. 1). Analysis of variance indicated that the levels of serum calcium were significantly different between groups (between intervals $F_{3,43} = 20.8$, $p < 0.0001$; between treatments $F_{1,43} = 169.5$, $p < 0.0001$).

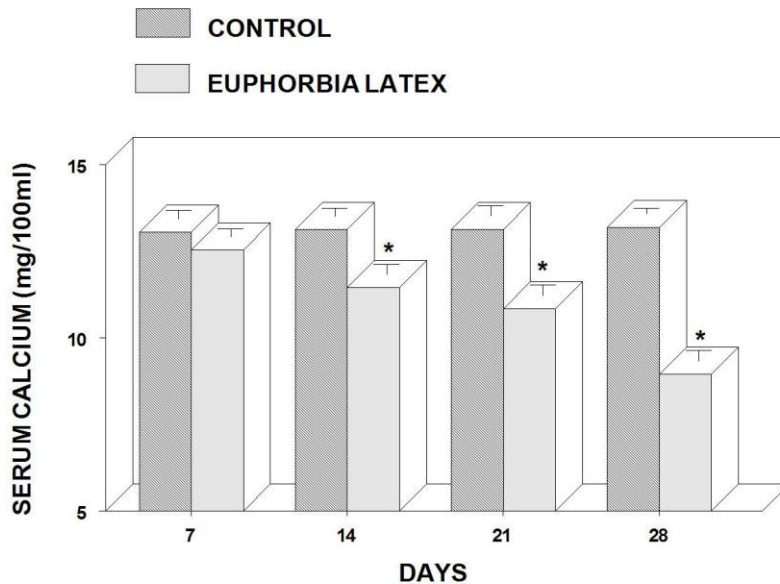


Fig. 2: Serum calcium levels in the fish *Heteropneustes fossilis* exposed over the long term to low concentrations (20% of 96-h LC_{50}) of the latex of *Euphorbia royleana*. Values are mean \pm SE of six specimens. Asterisks indicate significant differences ($p < 0.05$) from the control group.

In the long-term experiment, latex of *Euphorbia royleana* provoked a decrease in the serum calcium level on day 7. This decrease continued progressively till the close of the experiment (28 days) (Fig. 2). Analysis of variance indicated that the level of serum calcium were significantly different between groups (between intervals $F_{3,43} = 14.4$, $p < 0.0001$ between treatment $F_{1,43} = 152.2$, $p < 0.0001$).

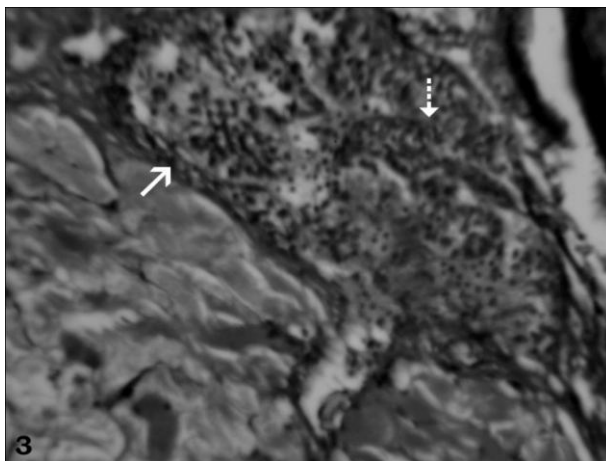


Fig. 3. Ultimobranchial gland of control *H. fossilis* exhibiting follicles (arrow) and cell cords (broken arrow). HE \times 200.

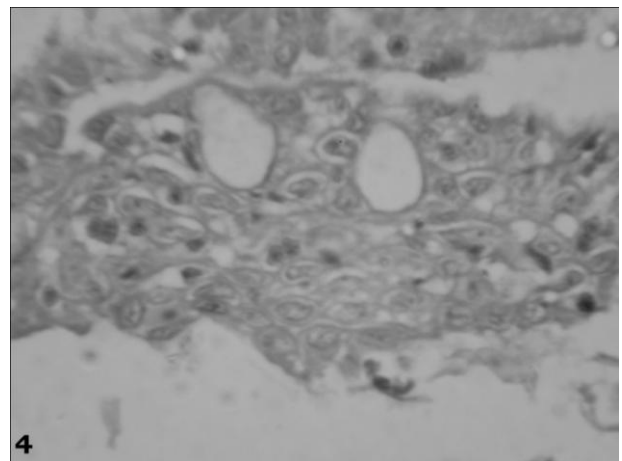


Fig. 4. Ultimobranchial gland of treated *H. fossilis* (72 h) exhibiting follicles (arrow) and cell cords (broken arrow). HE \times 500.

The histological structure of the ultimobranchial glands of control fish usually consisted of solid parenchyma composed of cell cords and small follicles (Fig. 3). All the cells are alike and their cell boundaries are indistinct. When stained with HE, the cytoplasm of these cells are noticed slightly eosinophilic.

In the short-term experiment, no histological change was seen in the ultimobranchial glands up to 72 h following treatment with latex. After 96 h following treatment, a decrease in the staining response of the cytoplasm of ultimobranchial cells was noticed (Fig. 4). The nuclear volume of these cells decreased slightly (Fig. 5) with time ($F_{3,43} = 3.67$, $p < 0.02$), but did not differ between treatments ($F_{1,43} = 2.81$, $p < 0.10$).

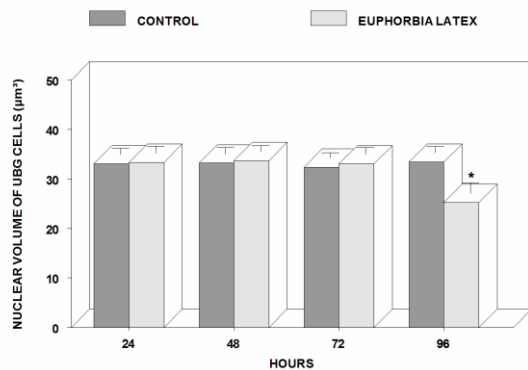


Fig. 5: Nuclear volume of ultimobranchial cells of *H. fossilis* treated with high-dose short-term amounts of latex of *Euphorbia royleana*. Mean \pm SE (n=6). Asterisks indicate differences ($p < 0.05$) from control group.

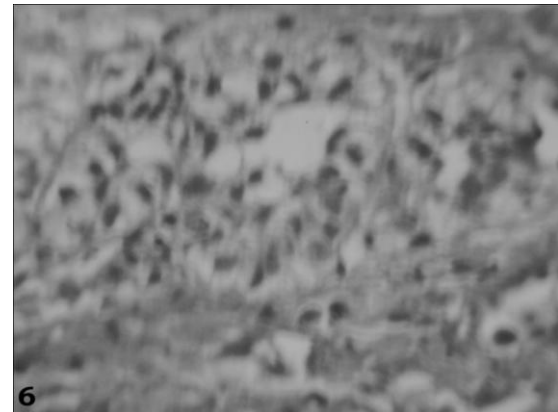


Fig. 6: Ultimobranchial gland 21 days after treatment with latex of *Euphorbia royleana*, showing decreased staining response of the cytoplasm HE \times 500.

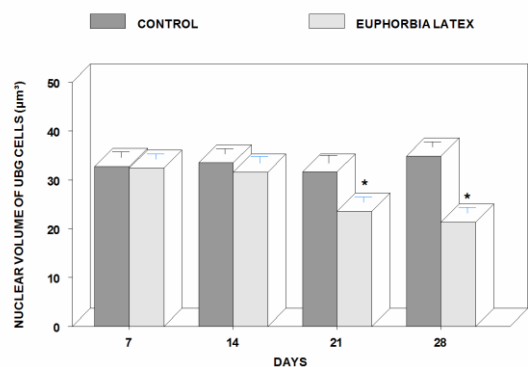


Fig. 7: Nuclear volume of ultimobranchial cells of *H. fossilis* treated with low-dose long-term amounts of latex of *Euphorbia royleana*. Mean \pm SE (n=6). Asterisks indicate differences ($P < 0.05$) from control group.

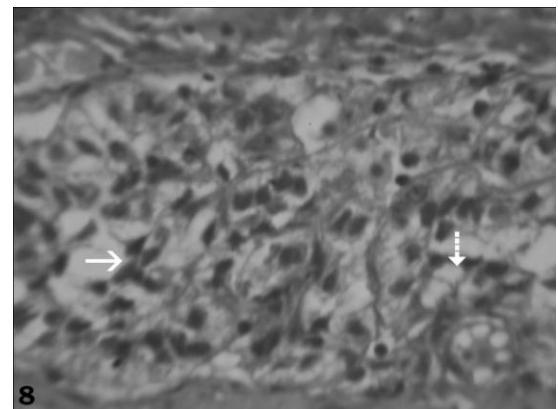


Fig. 8: Ultimobranchial gland of 28 days after treatment with latex of *Euphorbia royleana* exhibiting degeneration (arrow) and vacuolization (broken arrow). HE \times 500.

In the long-term experiment, the ultimobranchial gland exhibited no change up to 14 days following latex exposure. A slight decrease in the staining response of the cell cytoplasm was seen at day 21 (Fig. 6), and the nuclear volume decreased (Fig. 7). After 28 days the nuclear volume decreased further (Fig. 7), and degeneration and vacuolization appeared (Fig.

8). Analysis of variance indicated that the nuclear volumes differed significantly between groups (between intervals $F_{3,43} = 10.2$, $p < 0.0001$; between treatments $F_{1,43} = 48.4$, $p < 0.0001$).

The ultimobranchial glands exhibited inactivity in latex-treated fish, expressed by the diminished staining response and decreased nuclear volume of their cells. The glands of treated fish also exhibited vacuolization and degeneration. Inactivity of the ultimobranchial glands could be attributed to the prolonged hypocalcemia caused by exposure to the latex of *Euphorbia royleana*. No comparable report is available regarding the effects of the latex of *Euphorbia royleana* on the activity of fish ultimobranchial glands. Inactivity of these glands in treated fish is similar to the observations of other investigators who exposed the fish to different toxicants - deltamethrin (Srivastav *et al.* 2002), metacid (Mishra *et al.* 2004), cypermethrin (Mishra *et al.* 2005), and cadmium (Rai *et al.* 2009).

Hypoactivity/inactivity of the ultimobranchial glands has also been observed in response to experimentally induced hypocalcemia after calcitonin administration to fish - *Anguilla anguilla* (Peignoux-Deville *et al.* 1975), *Gasterosteus aculeatus* (Wendelaar Bonga 1980), *Clarias batrachus* (Srivastav *et al.* 1989), *Amphipnous cuchia* (Tiwari 1993) and *Heteropneustes fossilis* (Srivastav *et al.* 2009). The observed degeneration and vacuolization in the gland may be due to the continuous disuse of the ultimobranchial gland caused by prolonged hypocalcemia in treated fish.

It can be concluded from the present study that *Euphorbia royleana* is effective in inducing histological changes in the ultimobranchial gland of fish and causing physiological disturbances.

Acknowledgements

References

- Abdel-Hamid HF (2003) Molluscicidal and *in-vitro* schistosomicidal activities of the latex and some extracts of some plants belonging to Euphorbiaceae. *Journal of Egyptian Society of Parasitology* 33: 947-954.
- Bani S, Suri KA, Suri OP & Sharma OP (1998) Analgesic and antipyretic properties of *Euphorbia royleana* latex. *Phytotherapy Research* 11: 597-599.
- Basak SK, Bakshi PK, Basu S & Basak S (2009) Keratouveitis caused by *Euphorbia* plant sap. *Indian Journal of Ophthalmology* 57: 311-313.
- Chopra RN, Chopra IC, Honda LK & Kapoor LD (1958) *Chopra's indigenous drugs of India*. U.N. Dhar and Sons Pvt. Calcutta. pp816.
- Harikrishnan R, Balasundaram C, Kim M, Kim J & Heo M (2009) Effective administration route of azadirachtin and its impact on haematological and biochemical parameters in goldfish (*Carassius auratus*) infected with *Aeromonas hydrophila*. *Bulletin of the Veterinary Institute in Pulawy* 53: 613-619.
- Kumar A, Prasad M, Srivastava K, Tripathi S & Srivastav Ajai K (2010a) Branchial histopathological study of catfish *Heteropneustes fossilis* following exposure to purified neem extract, azadirachtin. *World Journal of Zoology* 4: 239-243.
- Kumar A, Prasad M, Mishra D, Srivastav SK & Srivastav Ajai K (2010b) Effects of *Euphorbia tirucalli* latex on blood calcium and phosphate of the freshwater air-breathing catfish *Heteropneustes fossilis*. *Toxicological & Environmental Chemistry* DOI: 10.1080/02772248.2010.539570
- Kumar A, Prasad M, Mishra D, Srivastav SK & Srivastav Ajai K (2010c) Botanical pesticide, azadirachtin attenuates blood electrolytes of a freshwater fish *Heteropneustes fossilis* *Pesticide Biochemistry & Physiology* DOI: 10.1016/j.pestbp.2010.11.014.
- Mishra D, Srivastav SK & Srivastav Ajai K (2004) Plasma calcium and inorganic phosphate levels of a teleost *Heteropneustes fossilis* exposed to metacid-50. *Malaysian Applied Biology* 33: 19-25.
- Mishra D, Srivastav SK & Srivastav Ajai K (2005) Effects of the insecticide cypermethrin on plasma calcium and ultimobranchial gland of the teleost *Heteropneustes fossilis*. *Ecotoxicology & Environmental Safety* 60: 193-197.
- Peignoux-Deville J, Lopez E, Lallier F, Bagot EM & Milet C (1975) Responses of ultimobranchial body in eels (*Anguilla anguilla* L.) maintained in seawater and experimentally matured to injections of synthetic salmon calcitonin. *Cell & Tissue Research* 164: 73-83.
- Poleksic V & Karan V (1999) Effects of trifluralin on carp: biochemical and histological evaluation. *Ecotoxicology & Environmental Safety* 43: 213-221.

- Prasad M, Kumar A, Mishra D, Srivastav SK, Suzuki N & Srivastav Ajai K (2009) Acute toxicities of diethyl ether and ethanol extracted *Nerium indicum* leaf to the fish, *Heteropneustes fossilis*. *Nigerian Journal of Natural Products & Medicine* 13: 53-57.
- Prasad M, Kumar A, Mishra D, Srivastav SK & Srivastav Ajai K (2010a) Blood electrolytes of a freshwater catfish *Heteropneustes fossilis* in response to treatment with a botanical pesticide, *Euphorbia royleana* latex. *Integrative Zoology* (in Press).
- Prasad M, Kumar A, Mishra D, Srivastav SK & Srivastav Ajai K (2010b) Alterations in blood electrolytes of a freshwater catfish, *Heteropneustes fossilis* in response to treatment with a botanical pesticide, *Nerium indicum* leaf extract. *Fish Physiology & Biochemistry* DOI: 10.1007/s10695-010-9452-1.
- Prasad M, Kumar A, Mishra D, Srivastav SK & Srivastav Ajai K (2010c) Acute toxicity of *Euphorbia royleana* latex on freshwater catfish, *Heteropneustes fossilis*. *Acta Toxicologica Argentina* (in Press).
- Rai R, Mishra D, Srivastav SK & Srivastav Ajai K (2009) Ultimobranchial gland of a freshwater teleost, *Heteropneustes fossilis* in response to cadmium treatment. *Environmental Toxicology* 24: 589-593.
- Rai R, Tripathi S, Mishra D, Srivastav SK & Srivastav Ajai K (2010) Cadmium-induced changes in the corpuscles of Stannius of a freshwater teleost, *Heteropneustes fossilis*. *Egyptian Journal of Biology* 12: 74-80.
- Singh DK & Agarwal RA (1984) Correlation of the anti-cholinesterase and molluscicidal activity of the latex of *Euphorbia royleana* Bioss. on *Lymnaea acuminata*. *Journal of Natural Products* 47: 702-705.
- Singh DK & Agarwal RA (1990) Molluscicidal and anti-cholinesterase activity of Euphorbiales. *Biological Agriculture & Horticulture* 7: 81-91.
- Sood GC, Sofat BK, Chandel RD (1971) Injury to the eye by the sap of *Euphorbia royleana*. *British Journal of Ophthalmology* 55: 856.
- Srivastav Ajai K (1989) Effect of 1, 25 dihydroxycholecalciferol administration on prolactin cells of the freshwater catfish *Clarias batrachus*. *Zoologische Jahrbucher Abteilung fur Allgemeine Zoologie und Physiologie der Tiere* 93: 241-244.
- Srivastav Ajai K, Srivastava SK, Mishra D, Srivastav S & Srivastav SK (2002) Ultimobranchial gland of freshwater catfish, *Heteropneustes fossilis* in response to deltamethrin treatment. *Bulletin of Environmental Contamination & Toxicology* 68, 584-591.
- Srivastav Ajai K, Srivastava SK, Mishra D, Srivastav SK & Suzuki N (2009) Effects of deltamethrin on serum calcium and corpuscles of Stannius of freshwater catfish, *Heteropneustes fossilis*. *Toxicological & Environmental Chemistry* 91: 761-772.
- Srivastava SK, Tiwari PR & Srivastav Ajai K (1989) Chlorpyrifos induced histological changes in the gill of freshwater catfish *Heteropneustes fossilis*. *Boletim de Fisiologie Animale* 13: 23-28.
- Srivastava SK, Tiwari PR & Srivastav Ajai K (1990) Effects of chlorpyrifos on the kidney of freshwater catfish *Heteropneustes fossilis*. *Bulletin of Environmental Contamination & Toxicology* 45: 748-751.
- Srivastava AK, Mishra D, Srivastava S, Srivastav SK & Srivastav Ajai K (2010) Acute toxicity and behavioural responses of *Heteropneustes fossilis* to an organophosphate insecticide, dimethoate. *International Journal of Pharma & Bio Sciences* 1: 359-363.
- Tiwari PR (1993) Endocrinal regulation of calcium in teleost. Ph.D. Thesis, University of Gorakhpur, Gorakhpur, India.
- Tiwari S, Singh SK, Singh A (2004) Toxicological effect and biochemical alteration induced by different fractions of *Euphorbia royleana* latex in freshwater harmful vector Snail *Lymnaea acuminata*. *Indian Journal of Experimental Biology* 42: 1220-1225.
- Wendelaar Bonga SE (1980) Effect of synthetic salmon calcitonin and low ambient calcium on plasma calcium, ultimobranchial cells, Stannius bodies and prolactin cells in the teleost *Gasterosteus aculeatus*. *General & Comparative Endocrinology* 40: 99-108.

الملخص العربي

إيوفوربيا رويلينا (*Euphorbia royleana*) مبيد نباتي ضد الآفات ويؤثر على الغدة الخيشومية لسمكة القبط (*Heteropneustes fossilis*)

مانيرام براساد، أبهيشيك كومار، سونيل كومار سريفاستاف & أجاي سريفاستاف

قسم علم الحيوان، جامعة دين دايال أبادهاي جوراكير، الهند

الملخص العربي

تعرضت سمكة القبط (*Heteropneustes fossilis*) لجرعات عالية ومنخفضة من عصارة نبات إيوفوربيا رويلينا (*Euphorbia royleana*) لفترات قصيرة وطويلة على التوالي. تم تحليل مستويات الكالسيوم ببلازما الدم، كما تم فحص الغدد الخيشومية. ومن خلال الفحص والتحليل وجد أن مستويات الكالسيوم قد انخفضت في بلازما الدم بعد 48 ساعة من التعرض لفترات قصيرة وظلت منخفضة حتى نهاية التجربة. أظهرت خلايا الغدة الخيشومية انخفاضاً في الاستجابة لعملية صبغ السيروبلازم بعد 96 ساعة من المعالجة بعصارة النبات، كما أن الأنوية قد تقلصت في الحجم قليلاً. أما بالنسبة للأسماك التي تعرضت بشكل مزمن لعصارة النبات فقد أظهرت كذلك انخفاضاً في مستويات الكالسيوم في الدم، وبعد ذلك وبدايةً من اليوم السابع على وجه التحديد بدأت مستويات الكالسيوم في التراجع مرة أخرى بشكل تدريجي حتى نهاية التجربة. وصولاً إلى اليوم الرابع عشر بعد المعالجة لم يكن هناك أي تغيير في التركيب النسيجي للغدد الخيشومية، ولكن بعد ذلك ظهر انخفاض في حجم الأنوية، كما أصبح السيروبلازم ضعيف الاستجابة للصبغة. كان هناك بعض الفجوات الموجودة بالنسيج وبعض التلف.