

Marjolin's ulcer arising from cutaneous lichen planus

O.A. Olawoye^{1,2}, A.I. Michael², O.A. Oluwasola³

¹Department of Surgery, University of Ibadan.

²Department of Plastic and Reconstructive Surgery, University College Hospital Ibadan.

³Department of Pathology, University of Ibadan and the University College Hospital Ibadan

Correspondence to: Dr O. A. Olawoye, email: yinkaolawoye@yahoo.co.uk

The association between cutaneous lichen planus and Squamous cell carcinoma has been controversial. The rarity of documented cases, has led some to suggest that it may represent a chance association. Whilst there have been many reports of Marjolin's ulcer arising from oral lichen planus, reports of Squamous cell carcinoma arising from or associated with cutaneous lichen planus in the literature remains sparse. The aim of this review is to report the case of a patient with a lesion previously diagnosed as cutaneous lichen planus, who developed Marjolin's ulcer in the same location, in the absence of known exposure to exogenous carcinogens. The development of Marjolin's ulcer from cutaneous lichen planus is not as rare as previously believed although the pathogenic mechanism for the transformation remains largely unknown.

Keywords: Cutaneous lichen planus, Marjolin's ulcer, Squamous cell carcinoma

Introduction

Marjolin's ulcer is an epidermoid carcinoma arising from chronic ulcers and scars. This condition is most commonly seen in burn scars as originally described by Jean Nicholas Marjolin in the 19th century. However, it has also been reported in relation to other conditions such as pressure ulcers¹ osteomyelitis² skin graft donor site³ injection sites^{4,5} venous ulcers⁶ scar tissue around colostomies⁷ and occult trauma⁸. There have also been several reports of Squamous cell carcinoma arising from or associated with oral lichen planus^{9,10,11,12}.

Malignant transformation of cutaneous lichen planus, though a rare occurrence, has been described in chronic hypertrophic lesions of lichen planus on the legs^{13,14,15,16,17} including a case of metastatic Squamous cell carcinoma developing in a 34-year-old male in chronic hypertrophic lesions of lichen planus on the legs of more than 10 years duration¹⁸. This is a report of a patient with a skin lesion previously diagnosed as cutaneous lichen planus, who later developed Marjolin's ulcer in the same location, in the absence of exposure to known exogenous carcinogens.

Case Report

A 39 year old lady presented to our service in June 2012 with an ulcer on the distal aspect of her left leg of six months duration. The ulcer developed spontaneously from the site of a previously diagnosed lichen planus 15 years before presentation. She has had no exposure to any known exogenous carcinogens since the diagnosis of lichen planus was made. The lichen planus was bilateral involving the distal aspects of both legs (Figure 1). The ulcer was located on the antero-lateral aspect of the distal left leg and measured 12 cm by 8 cm. The wound edges were raised with surrounding hyperkeratotic skin and adjoining licheneferous lesions. She had a non tender discrete ipsilateral enlarged inguinal lymph node which measured 5cm by 3 cm. The other systemic examination and ancillary laboratory work up as well as radiologic evaluation was unremarkable.

A clinical diagnosis of Marjolin's ulcer with inguinal lymph node metastasis was made. She had a wide local excision of the ulcer with a 2 cm margin and split thickness skin grafting done (Figure 2).

The histology of the excised lesion showed a malignant epithelial neoplasm composed of moderately pleomorphic cells disposed in nests and trabeculae (Figure 3). The component cells had

hyperchromatic to vesicular nuclei with eosinophilic cytoplasm. Also seen were keratin pearls and individual cell keratinization. There was ulceration of the underlying epithelium. All the margins of resection were free of tumour. A histological diagnosis of invasive squamous cell carcinoma was made with associated inguinal lymph node metastasis (Figure 4). She declined a planned groin dissection and rather consented to post operative adjuvant radiotherapy.

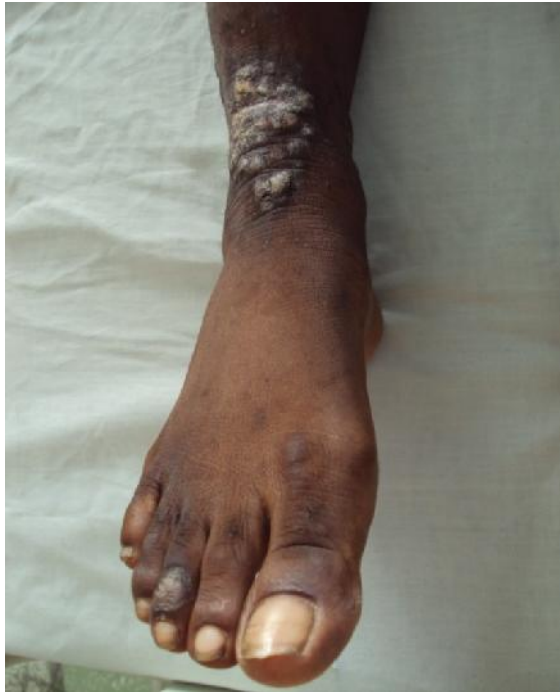

Figure 1. Lichen planus on contra-lateral leg

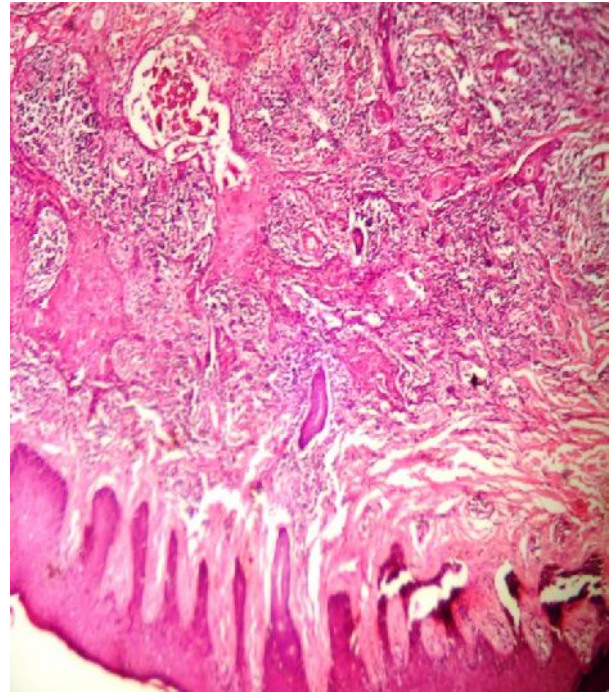


Figure 3. Photomicrograph demonstrating invasive Squamous cell carcinoma within the dermis.

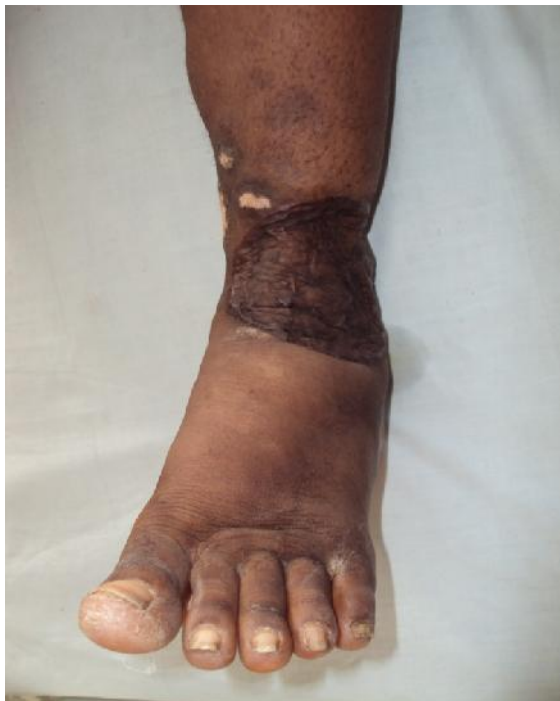

Figure 2. Post operative picture showing the grafted site of the excised ulcer

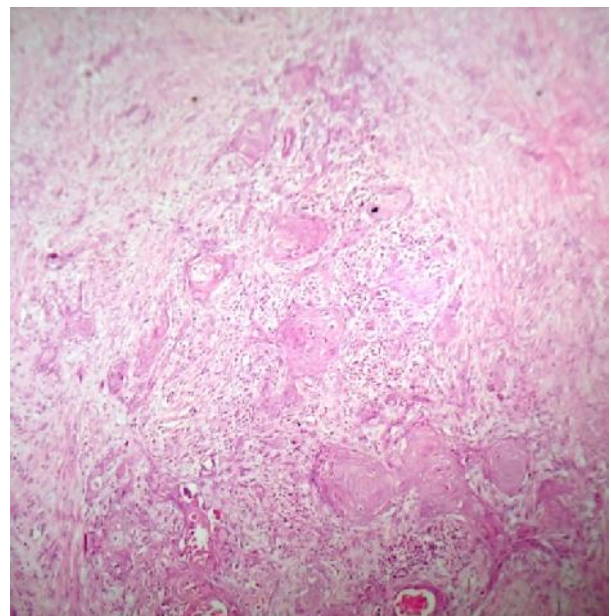


Figure 4. Photomicrograph demonstrating lymph node metastasis by Squamous cell carcinoma



Discussion

Lichen planus is a chronic mucocutaneous disease which presents as an itchy rash affecting the oral mucosa, tongue, scalp, nails, genitalia and skin. The oral lesions are more common and are usually tender or painful and located on the sides of the tongue or inside the cheek or on the gums while the cutaneous lesions are usually located on the inner wrist, legs, torso or genitals. They are itchy and usually symmetrical. They may be single or arranged in clusters and they often have distinct sharp borders. They usually present as papules and they commonly affects middle aged adults. The exact cause of lichen planus is unknown, however it is likely to be related to allergic or immune reaction.

The incidence of Squamous cell carcinoma arising in oral lichen planus has been reported as between 0.4 and 15% but the true incidence may be nearer 1%¹⁹. Despite the unclear aetiological basis, the association between oral lichen planus and Squamous cell carcinoma is now widely accepted.

Du Castell reported the first case of squamous cell carcinoma arising in cutaneous lichen planus on the lower leg of a 50 year old man in 1903²⁰. Since then, less than a hundred cases have been reported. Perhaps the largest series so far was that reported by Sigurgeirsson and Lindelof²¹ from a longitudinal study of 2071 patients with lichen planus over an average of 9.9 years in which only 8 patients developed Squamous cell carcinoma from their cutaneous lesion. Several other authors have reported isolated cases of Squamous cell carcinoma arising from cutaneous lichen planus^{22,23,24}.

The lesion in our patient was located in the lower leg similar to what has been documented in the majority of other reports, while the duration of her lichen planus before the malignant transformation was 15 years. This falls within the range of 4 months to 34 years (mean 12.9 years) reported by Patel et al¹⁴. It has been suggested that the chronicity of the lichen planus appears to be a risk factor for the development of Marjolin's ulcer. There are conflicting reports about the morphologic type of lichen planus that is most commonly associated with progression to malignancy between the ulcerative and the hypertrophic forms. The more recent reports¹⁴ suggest that this association maybe higher with the ulcerative types as was found in our patient.

There is therefore a need for prompt surgical intervention in patients with persistent lichen planus either of the ulcerative or hypertrophic type to prevent progression into malignancy and the occurrence of ulcer in a patient with chronic lichen planus should prompt the exclusion of a malignant transformation.

Conclusion

The development of Marjolin's ulcer from cutaneous lichen planus is not as rare as previously believed although the pathogenic mechanism for the transformation remains largely unknown.

Acknowledgement

We wish to acknowledge Prof George, the Consultant Dermatologist who made the initial diagnosis of Lichen planus and Prof O M Oluwatosin for reviewing the manuscript. We also Acknowledge Dr Aliyu Lawan for preparing the photomicrographs.

References

1. Stancard C.E., Cruse C.W., Wells K.E. et al.: Chronic pressure ulcer carcinomas. *Ann. Plast. Surg.*, 1993; 30: 274-7
2. Johnson L.L., Kempson R.L.: Epidermoid carcinoma in chronic osteomyelitis: Diagnostic problems and management. *J. Bone Joint Surg.*, 1965; 47: 133-45
3. Hammond J.S., Thomson S., Ward C.G.: Scar carcinoma arising acutely in a skin graft donor site. *J. Trauma*, 1987; 27: 681-3



4. Escudero Nafs F.J., Troyas G.R., Montejano-Sierra M.P., San Juan C.C.: Basal cell carcinoma in a vaccination scar. *Plast. Reconstr. Surg.*, 1995; 95: 199
5. Braithwaite I.J., Miller G., Burd A.R.: Basal cell carcinoma in a BCG scar in a young woman. *Scand. J. Plast. Reconstr. Hand Surg.*, 1992; 26: 233
6. Fleming M.D., Hunt J.L., Purdue G.F. et al: Marjolin's ulcer: A review and re-evaluation of a difficult problem. *J. Burn Care Rehabil.*, 1990; 11: 460-9
7. Dildorkar M.S., Douglas H.O., Holyoke E.D., Elias E.G.: Basal cell carcinoma originating at the colostomy site: Report of a case. *Dis. Colon Rectum*, 1975; 18: 399
8. Barr L.H., Menard J.W.: Marjolin's ulcer: The LSU experience. *Cancer*, 1983; 52: 173-5
9. Jose M.,G, Marcio D. F., Pilar G. V., Andres B. C., Jose, M. S., Abel C. G. Malignant transformation of oral lichen planus in lingual location: report of a case. *Oral Oncol.*, 1998; 34; 239-46,
10. Larsson, A., Warfvinge, G. Malignant transformation of oral lichen planus. *Oral Oncol.* 2003; 39; 630 – 632
11. Per-Olof R., Mats J., Ulf M., Erik H. Cancer and oral lichen planus in a Swedish population. *Oral Oncol.* 2004; 40: 131 -138
12. Barnard N., Scully C, Everson J. W. et al. Oral cancer development in oral lichen planus. *J. oral pathol med.* 1993; 22: 421 – 424
13. Sigurgeirsson, B., Lindelof B. Lichen planus and malignancy. *Arch dermatol.* 1991; 127; 1684 – 1688.
14. Patel G.K., Turner R. J., Marks R. Cutaneous lichen planus and Squamous cell carcinoma. *J. Eur Acad dermatol venereal* 2003; 17: 98 – 100
15. Potter B, Fretzin D. Well differentiated epidermoid carcinoma arising in hypertrophic lichen planus. *Arch Dermatol* 1966, 94:805-6.
16. Gawkrödger DJ, Stephenson TJ, Thomas SE. Squamous cell carcinoma complicating lichen planus: A clinico-pathological study of three cases. *Dermatology* 1994;188:36-9.
17. Manz B, Paasch U, Stierherling M. Squamous cell carcinoma as a complication of long standing hypertrophic lichen planus. *Int J Dermatol* 2005; 44:773-4.
18. Ardabili M, Gambicher T, Rotterdam S, Altmeyer P, Hoffmann K, Stucker M. Metastatic cutaneous squamous cell carcinoma arising from chronic hypertrophic lichen planus. *Dermatol Online J* 2003; 9:10.
19. Kovesi G., Banoczy J. Follow up studies in oral lichen planus. *Int J oral surg.* 1973; 2: 13 -19
20. Du Castel M. Lichen Corne: epitheliome. *Ann Derm Syph (purix)* 1903; 4: 412 – 418
21. Sigurgeirsson, B., Lindelof, B. Lichen Planus and malignancy: An Epidemiologic Study of 2071 Patients and a Review of the Literature. *Arch Dermatol.*1991; 127:1684-1688.
22. Yesudian P, Rao R. malignant transformation of hypertrophic lichen planus. *Int J Dermatol.* 1985; 24; 177-178.
23. Mayron R. Grimwood R. Siegle RJ, Camisa C. Verrucous carcinoma arising in ulcerative lichen planus of the soles. *J Dearmatol Surg Oncol.* 1988; 14:547 – 551.
24. Ruocco V, Satriano RA, De Rosa G. et al Malignancy in lichen planus. *Int J Dermatol.* 1989; 28; 542 – 544