

Clinicopathological Characteristics of Aural Polyps

O.A. Sogebi

Department of Surgery, College of Health Sciences (OACHS), Olabisi Onabanjo University (OOU), Sagamu and Department of ENT, Olabisi Onabanjo University Teaching Hospital (OOUTH), Sagamu.

Correspondence to: Dr O.A. Sogebi, E mail: ayosogebi2000@yahoo.com

Background: *The objective of this study was to characterize aural polyps, documenting its clinical, audiological, radiological and histopathological features.*

Methods: *Retrospective retrieval of information on named characteristics from the case records of patients with aural polyps. It compared these characteristics between children and adult patients. Analysis was done using SPSS version 19.0.*

Results: *Data of 52 patients were analyzed. Aural polyps constituted 11.1% of otology cases. The majority (63.5%) of the patients were females and 34.6% were children. The mean age was 27.1 years. The major presenting symptoms included earache in 44 (84.6%), ear discharge (82.7%) and fullness in the ear (65.4%). The median duration of symptoms was 4 weeks with no laterization of polyp. In 69.2% of the ears, there were perforations of the eardrum. Hearing impairment was recorded in 53.8% of the patients while 69.2% of the aural polyps were associated with otitis media. Most polyps were attached to the anterior wall of the external auditory canal (EAC). In the PTA, 37.9% had conductive hearing loss; 55.2% out of assessed mastoid radiographs had sclerotic cells while 26.5% of the histopathology reports had cholesteatoma. Significant differences occurred in the experience of two symptoms between children and adults.*

Conclusions: *Both clinical and pathological characterizations are important in effective management of aural polyps. Aural polyps should be considered serious aural lesion.*

Introduction

Aural polyps, fleshy and oedematous growth in the external auditory canal (EAC) of the ear is a lesion that Otolaryngologists and general duty physicians are sometimes confronted with. It occurs worldwide; although it tends to be more common in the developing countries due to its association with chronic inflammatory diseases of ear which are more prevalent in these places¹. Polyps usually arise from hyperemic inflamed mucosa and progressively enlarge so that it blocks drainage via the external auditory meatus. The surface can be ulcerated, covered in a hyperemic respiratory mucosa or have areas of squamous metaplasia². Nevertheless, other infrequently encountered inflammatory diseases, tumors and pseudo-tumors involving the middle ear cleft may cause symptoms and signs identical with those of chronic otitis media and manifest with polyps invading the EAC³. Unusual cases of aural polyps occurring sporadically have been reported in humans⁴ as well as in companion animals like dogs⁵ and cats⁶.

Polyps often present with copious mucoid or purulent ear discharge but this can be scanty and offensive when there is an associated complication. Many patients present to physicians when symptoms of either earache, hearing loss or feeling of fullness in the ear is noticed, or when the ear discharge becomes bloody^{7,9}.

While aural polyps can be managed by simple aural polypectomy, those arising from inflammatory ear diseases are more difficult to manage and are also associated with grievous consequences⁴. The consequences include progression of the disease process and presence of cholesteatoma. A cholesteatoma is a keratinized squamous epithelial-lined pocket containing keratinous debris which is locally invasive and digests a lot of tissues causing extensive destruction.

Many studies in the literature concern case reports of unusual pathologies presenting as aural polyps^{1, 10, 11} and highlighted their management. The general picture and characterization of polyps in terms of frequency

distribution, mode of clinical presentation and other associations is generally sparse while there is no available documentation on aural polyps in Nigeria. This study therefore aimed to characterize aural polyps, documenting initial clinical presentation, location, extent, associations as well as the type of audiological, radiological and histopathological findings. It also aimed to compare if there is any difference in these characteristics between children and adult patients.

Patients and Methods

This was a Retrospective study and analysis of patients with clinical diagnoses of aural polyps managed at the Ear, Nose and Throat (ENT) clinic of Olabisi Onabanjo University Teaching Hospital (OOUTH), Sagamu, Nigeria between July 2007 and June 2012. The case notes of the patients with aural polyps who had excision biopsies (simple aural polypectomies) were retrieved and data was obtained from the records.

Information retrieved from the case records included the demographic data, the main presenting symptoms, duration of symptoms at the index presentation, affected ear, otoscopic findings including location and attachment of polyp, state of the tympanic membrane, clinical evidence of hearing loss from tuning fork tests, clinical diagnosis, and whether there was previous history of aural polyp (recurrence). Investigation results noted were pure tone audiometric (PTA) pattern, radiological findings with emphases on the mastoid antrum, and histopathology report of the polyp. Patients that had recurrences after excision were also noted. Excluded were data from patients who had documented tumors in the ears with evidence of local and regional aggression, sometimes with features of distant metastasis.

The study was approved by OOUTH Health Research and Ethics Committee, HREC. The information was entered as data into a spreadsheet, analyzed and presented in simple descriptive forms as tables and graphs. The clinical and pathological characteristics were compared between children and adult patients using Chi square test for discrete variables (expressed as proportions), and student t-test for continuous variables. The level of statistical significance was set at $p < 0.05$. The analysis was done using the SPSS version 19.0 (Illinois).

Results

Sixty three patients had aural polyps but only 52 case notes had enough information to be included in the analysis. This number constituted 11.1% of total number (569) of otology cases seen in the clinic in the period of study. Thirty three (63.5%) of the 52 patients were females, while 18 (34.6%) were children, 30 patients (57.7%) were adults and 4 patients (7.7%) were elderly patients (Mean age was 27.1 years). The age distribution according to sex of the patients is shown in Figure 1.

The clinical characteristics of the patients are presented in Table 1. The major symptoms that the patients presented with were earache (84.6%), ear discharge (82.7%), and fullness in the ear (65.4%). The duration of symptoms before index presentation ranged between 1 and 13 weeks, with a median of 4 weeks. There was no differential laterization of polyp to either of the ears. Majority of the involved ears (69.2%) had perforations of the eardrum. Clinically 28 (53.8%) of the patients had subjective conductive hearing impairment. Thirty six (69.2%) of the aural polyps were associated with otitis media. Three patients were seen with recurrent aural polyps at the index presentation in our clinic while four others were discovered with recurrences after initial polyp excision.

Table 2 shows the pathological characteristics of the Polyps. Almost half (23; 44.2%) of the polyps were located at the junction between the inner two thirds and outer third of the EAC. Most polyps (16/29 of documented) were attached to the anterior wall of the EAC while it was difficult to delineate the attachment in (23/52) 23.1% of the polyps. PTA of 29 patients were assessed, 37.9% (11/29) of these had conductive hearing losses, while (7/29; 24.1%) had normal audiograms in the affected ears. Sixteen (55.2%) out of

assessed mastoid radiographs had sclerotic mastoids while 13 (26.5%) of the histopathology reports had cholesteatoma.

Comparison of the clinical characteristics between the children and adult patients revealed significant differences in the experience of symptoms of fullness in the ear and also in presentation with Tinnitus (Table 3), while there were no differences in the pathological characteristics between the children and adult patients seen in Table 4.

Table 1. Clinical Characteristics of 52 Patients

Variable	Number	%
<i>Symptoms at presentation</i>		
Otalgia	44	84.6
Fullness in the ears	34	65.4
Otorrhoea	43	82.7
Tinnitus	24	46.2
Vertigo	2	3.8
<i>Affected ear</i>		
Right	29	55.8
Left	23	44.2
<i>Duration of symptoms (weeks)</i>		
0-4.0	34	65.4
4.1-8.0	14	26.9
8.1-12.0	3	5.8
>12.1	1	1.9
<i>Mean \pmSD : 4.3\pm2.7; Median: 4.0</i>		
<i>Tympanic membrane</i>		
Intact	16	30.8
Perforation: Central	15	28.8
Subtotal	16	30.8
Marginal	5	9.6
<i>Clinical evidence of conductive hearing loss</i>	28	53.8
<i>Clinical aetiology of polyp</i>		
Otitis externa	11	21.2
Otitis media	36	69.2
Unknown	5	9.6
Recurrence	9	17.3

Table 2. Pathological characteristics of 52 Patients

Variable	Number	%
<i>Location in EAC</i>		
Outer third	12	23.1
Junction of outer third and inner two third	23	42.2
Inner two third	17	32.7
<i>Affected wall</i>		
Anterior	22	43.3 (55.0)
Posterior	8	15.4 (20.0)
Roof	4	7.7 (10..0)
Floor	6	11.5 (15.0)
Undocumented	12	23.1
<i>Pure tone audiograph (PTA) findings</i>		
Normal	13.5	24.1
Conductive hearing loss	11	21.2 (37.9)
Sensorineural hearing loss	3	3 (10.3)
Mixed hearing loss	8	15.4 (27.6)
Not available	23	44.2
<i>Mastoid radiographs</i>		
Cellular	13	25 (44.8)
Sclerosis	16	55.2
Not available	23	44.2
<i>Histopathology</i>		
Inflammation	34	65.4 (69.4)
Cholesteatoma	13	25.0 (26.5)
Granulation tissue	2	3.8 (4.1)
Not available	3	5.8

NOTE: Figures in parenthesis are the proportion of cases relative to the available results

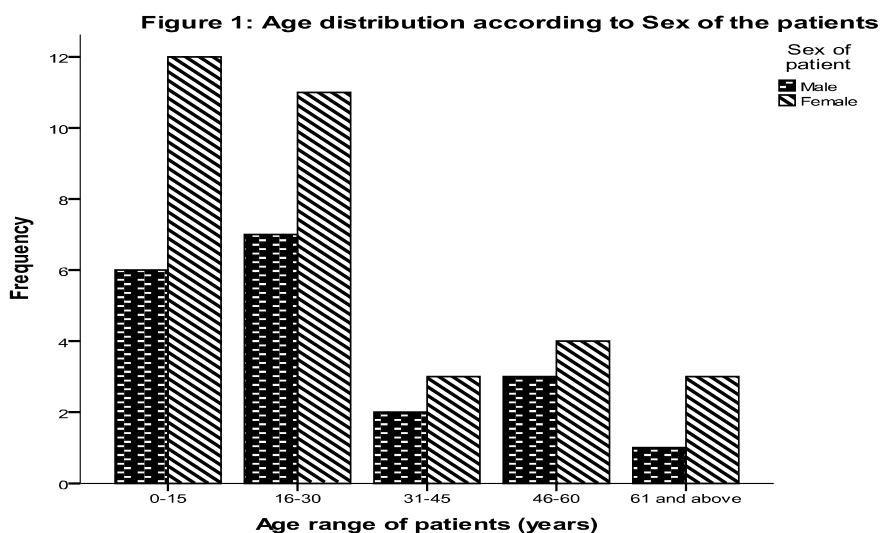


Table 3. Comparison of Clinical characteristics between Children and Adult patients

Variable	Children (%)	Adult (%)	Statistics	p
	n= 18	n= 34		
Sex (Male)	33.8	38.2	0.122	0.727
Otalgia	83.3	85.3	0.035	0.852
Ear fullness	33.8	82.4	12.495	0.000*
Otorrhoea	83.3	82.4	0.008	0.929
Tinnitus	22.2	58.8	6.344	0.012*
Vertigo	0.0	5.9	1.101	0.538
Affected side: Right	44.4	61.8	1.431	0.232
TM perforation	66.7	70.6	3.748	0.290
Conductive HL	50.0	55.9	0.164	0.686
Aetology: Otitis media	66.7	70.6	4.604	0.100
Recurrence	11.1	14.7	0.131	0.718
Duration of symptoms (Mean)	4.2	4.5	0.383	0.399

Table 4. Comparison of Pathological Characteristics Between Children and Adult Patients

Variable	Children (%)	Adults (%)	Statistics	p
	n=18	n=34		
Position of polyp:				
Junction	50.0	41.2	1.394	0.498
Affected wall:				
Anterior	55.6	35.3	2.495	0.646
PTA type				
Conductive HL	50.0	33.3	5.769	0.123
Mastoid radiographs:				
Sclerosis	80.0	50.0	1.506	0.220
Histopathology:				
Cholesteatoma	27.8	25.8	0.198	0.906

Discussion

Aural polyps presented clinically with discomforting symptoms of earache, ear discharge, and fullness in the ear, associated with perforations of the tympanic membranes, otitis media sometimes complicated with cholesteatoma and conductive hearing loss. Most of the patients presented within the first four weeks and had radiological evidence of sclerotic mastoid air cells. Majority of these presentations were similar in both children and adult patients. Crude aural polyp prevalence of 11.1% of otology cases was comparable to 15.8% found among patients with chronic otitis media in Spain¹². Most patients with aural polyps previously had chronic suppurative otitis media characterized by copious ear discharges; however, aural polyps tend to exacerbate the symptoms with increasing discomfort from earache and fullness in the ear⁹ prompting patients' presentation at the hospital.

The finding that majority of the tympanic membranes were perforated and sizeable proportion of patients were diagnosed clinically with otitis media (corroborated with conductive hearing loss, and mastoid sclerosis) led credence to the assertion that the pathology has a strong etiological link with aural polyp. Some authors attribute aural polyps to be sequel or complication of CSOM alone^{2, 13}. The outset of suppurative otitis media (SOM) as a childhood disease which progressed into adult life, and complicated by polyp in the ear may be responsible for the differential age distribution in favour of adults compared with

children observed in this study. Patients with CSOM understandably have conductive hearing loss resulting from tympanic membrane perforation and/or changes in the ossicular chain due to fixation or erosion caused by the chronic inflammatory process^{14, 15}. However, the mass effect of aural polyps in the EAC may in addition impair sound conduction into the inner ear; these two mechanisms possibly explain why a sizeable proportion of our patients had both clinical and audiometric evidences of conductive hearing loss.

There was no differential laterisation of the aural polyps to a particular side in this study. Although few studies had reported differential localization of pathologies to particular ears, this had not been consistent^{16,17}. Moreover, we did not observe any case of bilateral aural polyps nor involvement of both ears at different times. Bilateral inflammatory aural polyps have been described in asthmatic patients with aspirin hypersensitivity, and chronic rhinosinusitis with sinonasal polyposis (Samtad's triad)^{18,19}. Aural polyps were found to be associated with otitis externa as occurred in 21.2% of the patients in this study. While there are scanty reports to suggest a link between otitis externa and aural polyps in the literature, the presence of a polyp obstructing the EAC predisposes to inflammation presenting as otitis externa⁸. Thus the otitis externa could have been sequel of the aural polyp which occurred de novo. In five patients we could not ascribe any etiological connection to the polyps.

Histopathological analysis of surgical specimens after simple aural polypectomy is important in confirming the diagnosis, discovery of unusual lesions and also assists in the subsequent management of the patients. EAC polyps are most commonly inflammatory¹³ and non-specific in nature. While this may connote uncomplicated pathology which can be managed by simple aural polypectomy, the necessity for regular and long time follow up needs to be emphasized because a previously diagnosed case of inflammatory polyp may turn out to be a more serious pathology after prolonged follow-up².

Furthermore, this analysis will also assist in proper categorization of the lesions; 26.5% of our surgical specimens were confirmed with underlying cholesteatoma. Squamous epithelium was present on the surface of all polyps with underlying cholesteatoma. These superficial cells possessed elongated microvilli, microplicae of different sizes, grooves and pits. Such surface structures reflect different stages of the keratinization process that seems to be characteristic for the epithelial lining of polyps with underlying cholesteatoma²⁰. Cholesteatoma is locally invasive causing destruction of surrounding tissue due to its production of digestive enzymes especially Ras-related C3 botulinum toxin substrate 1 (RAC1) which has been associated with its rapid epithelial differentiation and invasive properties in human beings²¹. While cholesteatoma underlying polyp was a common finding in chronic middle ear disease with aural polyps, ears with cholesteatoma were at surgeries, also found with aural polypoidal growth^{4,22,23}.

Cholesteatoma was also prevalent in recurrent polyp cases seen in this study as previously reported.²⁴ Recurrence may be due to progression of disease resulting from incomplete clearance of underlying cholesteatoma; the four patients that had recurrences at follow-up had diagnoses of cholesteatoma. While simple aural polypectomy may be relevant in initial diagnosis, and oftentimes in treatment of aural polyps, it may not be adequate in treating extensive ear disease associated with cholesteatoma²⁵. Moreover due to the apparent linkage and synergistic effects of aural polyps and cholesteatoma, it is reasonable to treat any case of aural polyp resulting from CSOM as an extensive middle ear disease with apparent cholesteatoma which may require a minimum of mastoid exploration from the outset^{4, 26}. On the contrary, cholesteatoma may not always be associated with middle ear disease. Cholesteatoma was reportedly associated with congenital abnormalities of EAC and cases of congenital cholesteatoma have been reported^{27,28,29}. In these patients the noted symptoms of CSOM were absent and the tympanic membranes were intact³⁰.

Two patients had histological diagnosis of granulation tissue. The finding of granulation tissue reaction and keratina in an aural polyp were adjudged good predictors for the presence of cholesteatoma¹². Unusual

pathologies including tumors had been reportedly found in patients presenting with aural polyps and should reasonably be considered in its differential diagnosis³¹⁻³³. More than half of the patients (55.2%) had sclerotic mastoid air cells signifying an extensive disease affecting the mastoid. This may not be the perfect representation of the disease processes because of the inherent setbacks of plain X-rays (mastoid) as a diagnostic tool. Sclerotic mastoid may be a variant of normal, or may be due to incomplete development of the mastoid air cells in younger children³⁴. High resolution computerized tomography (CT) imaging is key to assessing any associated temporal bone destruction with up to 98.6% accuracy in diagnosing middle ear diseases and its complications^{34,35}. Only three of our patients had CT confirmation of mastoid air cells disease. Despite the availability of CT scan in our centre, affordability in terms of cost is still a constraint in most of our patients who need these services. Brea and Roldan Fidalgo³⁶ noticed an apparent scarcity in request for temporal bone CT scan to assess benign EAC lesions. When combined with patients clinical findings, CT findings can assist in disease stage classification which is helpful for the definitive surgery⁹.

The pathological characters appeared more reliable than the clinical features when assessing aural polyps since there was no significant difference between these in the two categories of patients. Two clinical presentation characteristics (ear fullness and Tinnitus) were significantly different between these categories of patients. The likelihood of children not appreciating fullness in the ears, subjective reduction in hearing and noise in the ear, (which can be masked by more discomforting symptom of earache) compared with adults may be responsible for this difference. However the difference may also be attributable to the retrieval of information from case notes rather than directly from the patients which is a limitation in this study.

The other limitations of this study include its retrospective nature with inadequate and loss of general and specific information on follow-up which makes it difficult to sufficiently measure the outcome and recurrences. Despite these, this study has been able to characterize the clinical and pathological features seen in aural polyps and also to detect the subtle differences in presentation between children and adult patients.

Conclusion

In conclusion, aural polyps should be considered as a serious aural lesion and effective management should include both clinical and pathological characterization. While simple aural polypectomy is relevant in initial treatment of aural polyps, histopathological examination of surgical specimen will assist in planning further treatment in extensive diseases. There is also a need for longitudinal controlled study on aural polyps.

Acknowledgement

The author wishes to acknowledge the efforts of the Resident doctors in the department in retrieving the case notes for data extraction.

References

1. Monasta L, Ronfani L, Marchetti F, Montico M, Vecchi Brumatti L, Bavcar A, et al., Burden of disease caused by otitis media: systematic review and global estimates. PLoS One. 2012; 7(4):e36226. Epub 2012 Apr 30.
2. Xenellis J, Mountriha K, Maragoudakis P, Kandiloros D, Assimakopoulos D, Linthicum FH, et al., A histological examination in the cases of initial diagnosis as chronic otitis media with a polypoid mass in the external ear canal. *Auris Nasus Larynx*. 2011; 38: 325–328.
3. Sanna M, Russo A, De Donato G, Caruso A, Taibah A. Diseases affecting the External Auditory Canal. In: *Color Atlas of Otoscopy. From Diagnosis to Surgery*. Thieme; 2002. p. 4–34.
4. Prasannaraj T, De NS, Narasimhan I. Aural polyps: safe or unsafe disease? *Am J Otolaryngol*. 2003; 24(3):155-158.

5. Pratschke KM. Inflammatory polyps of the middle ear in 5 dogs. *Vet Surg.* 2003; 32(3):292-296.
6. MacPhail CM, Innocenti CM, Kudnig ST, Veir JK, Lappin MR. Atypical manifestations of feline inflammatory polyps in three cats. *J Feline Med Surg.* 2007; 9(3):219-225.
7. Markou K, Karasmanis I, Vlachtsis K, Petridis D, Nikolaou A, Vital V. Primary pleomorphic adenoma of the external ear canal. Report of a case and literature review. *Am J Otolaryngol.* 2008; 29(2):142-146.
8. Caversaccio M, Häusler R, Helbling A. Otolgic manifestations in Samter's syndrome. *ORL J Otorhinolaryngol Relat Spec.* 2009; 71(1):6-10.
9. Chen B, Ye F, Wang L. The clinical characteristics and the treatment of external auditory canal cholesteatoma. *Lin Chung Er Bi Yan Hou Tou Jing Wai Ke Za Zhi.* 2011; 25(19):868-870.
10. Brugler G. Tumors presenting as aural polyps: a report of four cases. *Pathology.* 1992; 24(4):315-319.
11. Uppal HS, Kabbani M, Reddy V, Kaur S. Ectopic extra-cranial meningioma presenting as an aural polyp. *Eur Arch Otorhinolaryngol.* 2003; 260(6):322-324.
12. López Aguado D, López Campos D, Pérez Piñero B, Campos Bañales ME. Aural polyp in chronic inflammatory middle ear disease. *Acta Otorrinolaringol Esp.* 2003; 54(3):161-164.
13. Harris KC, Conley SF, Kerschner JE. Foreign body granuloma of the external auditory canal. *Pediatrics.* 2004; 113(4):e371-373.
14. da Costa SS, Rosito LP, Dornelles C. Sensorineural hearing loss in patients with chronic otitis media. *Eur Arch Otorhinolaryngol.* 2009; 266(2):221-224.
15. Maharjan M, Kafle P, Bista M, Shrestha S, Toran KC. Observation of hearing loss in patients with chronic suppurative otitis media tubotympanic type. *Kathmandu Univ Med J (KUMJ).* 2009; 7(28):397-401.
16. Yoon YH, Park CH, Kim EH, Park YH. Clinical characteristics of external auditory canal cholesteatoma in children. *Otolaryngol Head Neck Surg.* 2008; 139(5):661-664.
17. Olusesi AD. Otitis media as a cause of significant hearing loss among Nigerians. *Int J Pediatr Otorhinolaryngol.* 2008; 72(6):787-792.
18. Shen J, Peterson M, Mafee M, Nguyen QT. Aural polyps in Samter's triad: case report and literature review. *Otol Neurotol.* 2012; 33(5):774-778.
19. Brobst R, Suss N, Joe S, Redleaf S. Bilateral Inflammatory Aural Polyps: A Manifestation of Samter's Triad. *Int J Otolaryngol.* 2009; 2009:464958. Epub 2010 Feb 21.
20. Składzień J, Litwin JA, Nowogrodzka-Zagórska M, Miodoński AJ. Surface structures of aural polyps: a scanning electron microscopic study. *J Laryngol Otol.* 2002; 116(6):420-425.
21. Lee NH, Chang JW, Choi J, Jung HH, Im GJ. Expression of Ras-related C3 botulinum toxin substrate 1 (RAC1) in human cholesteatoma. *Eur Arch Otorhinolaryngol.* 2012 Feb 23. [Epub ahead of print].
22. Arroyo GR, Herráiz P C, Santos SS, Olaizola GF. Polyps of the external auditory canal and cholesteatoma. *Acta Otorrinolaringol Esp.* 1997; 48(6):447-451.
23. Youngs R. The histopathology of mastoidectomy cavities, with particular reference to persistent disease leading to chronic otorrhea. *Clin Otolaryngol Allied Sci.* 1992; 17(6):505-10
24. Gliklich RE, Cunningham MJ, Eavey RD. The cause of aural polyps in children. *Arch Otolaryngol Head Neck Surg.* 1993; 119(6):669-671.
25. Williams SR, Robinson PJ, Brightwell AP. Management of the inflammatory aural polyp. *J Laryngol Otol.* 1989; 103(11):1040-1042.
26. Cheng YF, Shiao AS, Lien CF. Pediatric external canal cholesteatoma with extensive invasion into the mastoid cavity. *Int J Pediatr Otorhinolaryngol.* 2005; 69(4):561-566.
27. Mazita A, Zabri M, Aneeza WH, Asma A, Saim L. Cholesteatoma in patients with congenital external auditory canal anomalies: retrospective review. *J Laryngol Otol.* 2011; 125(11):1116-1120.
28. Quantin L, Carrera Fernández S, Moretti J. Congenital cholesteatoma of external auditory canal. *Int J Pediatr Otorhinolaryngol.* 2002 1;62(2):175-179.

29. Choi JH, Woo HY, Yoo YS, Cho KR. Congenital primary cholesteatoma of external auditory canal. *Am J Otolaryngol.* 2011;32(3):247-249.
30. Owen HH, Rosborg J, Gaihede M. Cholesteatoma of the external ear canal: Etiological factors, symptoms and clinical findings in a series of 48 cases. *BMC Ear Nose Throat Disord* 2006; 6:16–24.
31. Vasileiadis I, Kapetanakis S, Petousis A, Karakostas E, Simantirakis C. Rapidly growing chondroid syringoma of the external auditory canal: report of a rare case. *Case Report Med.* 2011;2011:589680. Epub 2011 Sep 15.
32. Kim CW, Rho YS, Cho SJ, Lee CH, Bae WJ. A case of ceruminous adenocarcinoma of the external auditory canal presenting as an aural polyp. *Am J Otolaryngol.* 2008;29(3):205-208.
33. Selcuk A, Ensari S, Cetin MA, Sak SD, Dere H. Ceruminous gland carcinoma of the external auditory canal presenting as chronic otitis media. *B-ENT.* 2007; 3(4):195-199.
34. Cheng YF, Shiao AS, Lien CF. Pediatric external canal cholesteatoma with extensive invasion into the mastoid cavity. *Int J Pediatr Otorhinolaryngol.* 2005; 69(4):561-566.
35. Sun XW, Zhang JJ, Ding YP, Dou FF, Zhang HB, Gong KB, et al., Efficacy of high-resolution CT in differential diagnosis of chronic suppurative otitis media and cholesteatoma otitis media by soft-tissue shadows. *Zhonghua Er Bi Yan Hou Tou Jing Wai Ke Za Zhi.* 2011; 46(5):388-392.
36. Brea B, Roldán Fidalgo A. Imaging diagnosis of benign lesions of the external auditory canal. *Acta Otorrinolaringol Esp.* 2012 Aug 14. (Epub ahead of print).