

Macrostomia Repair: Comparison of the Z-Plasty Repair with the Straight line Closure

O.A. Olawoye¹, O.M. Fatungashe², B.A. Ayoade³, A.O. Tade³

Department of Plastic Surgery, University College Hospital, Ibadan¹. Departments of Anaesthesiology² and Surgery³, Olabisi Onabanjo University Teaching Hospital, Sagamu

Correspondence to: Dr. Olayinka A. Olawoye, Email: yinkaolawoye@yahoo.co.uk

Background: Macrostomia, also called Tessier 7 or lateral cleft is an uncommon congenital anomaly which results from the failure of fusion of the maxillary and mandibular processes of the first branchial arch. It could be syndromic or isolated, unilateral or bilateral. There is no consensus among surgeons about the single most acceptable method of repair and as such various methods of repair which attempt to restore normal anatomy have been proposed. This article presents the two cases managed at our hospital and compares the two most commonly performed procedures.

Case Report: The two patients who presented to the Plastic and Reconstructive Surgery unit of our Hospital, with bilateral macrostomia over a three year period from 1st April 2004 to 31st March 2007 form the basis for the report. One patient had a Z-plasty repair while the second patient had a straight line closure. The outcome of management of the two patients is presented

Conclusion: The scar in the patient with the Z-plasty repair appeared more prominent. Both patients however had normal appearing commisures. The multiplicities of options available for the repair of macrostomia suggest that no single method has been found to be most acceptable. The fear of scar contracture in simple line closure appears to be exaggerated.

Introduction

Macrostomia also referred to as Tessier 7 cleft, lateral cleft, commissural or transverse cleft is a rare congenital anomaly which results from the failure of fusion of the maxillary and mandibular processes of the first branchial arch^{1,2}. It could be syndromic or isolated, unilateral or bilateral. It is responsible for one in three hundred cases of facial cleft^{1, 2, 3}. Transverse facial fissures are present to varying degrees. The facial structures may also be involved and complete division of the face may be seen in some cases⁴.

The key element in the surgical repair of macrostomia to which all surgeons agree is the adequate reconstruction of the orbicularis oris muscle^{4, 5, 6}. However there is no consensus on the best option for the reconstruction of the commisure and the skin closure; hence various methods of repair which attempt to restore normal anatomy have been described. These include Z plasty repair on the skin⁷, the modified Estlander-type flap to repair the oral commissure⁸, the reverse double Z-plasty². Others include the two triangular flaps⁹, the refined simple line closure¹⁰, the incorporation of W plasty⁶ and the modification of the Ono et al's two triangular flaps¹¹.

Most of the modifications and refinement in techniques were introduced by various authors to improve the appropriate placement of the commisures as well as improve the appearance of the cheek scars. Despite the criticisms of the Z plasty repair, it's proponents continue to cite it's advantage of better placement of the commisure especially with the prevention of lateral contracture of the straight line scar with time. There does not appear to be a consensus among surgeons about the single most acceptable method of repair.

This article presents the two cases managed at our hospital using the two most commonly employed techniques and reviews the literature for the comparative advantages and disadvantages of the two methods.

Case Reports

Case 1

The first patient was a 5-month old baby boy with bilateral facial clefts. He was a product of a full term uneventful pregnancy delivered by spontaneous vaginal delivery at a private clinic. He was the first child of the parents and there was no family history or any other risk factor for oro-facial clefting. The perinatal history was normal. Physical examination revealed a healthy male infant with bilateral facial clefts. He had no other congenital anomaly. The results of his perioperative investigations were normal. He had overlapping repair of the orbicularis oris muscle, closure of the mucosa and a straight line repair of the skin under general anaesthesia.

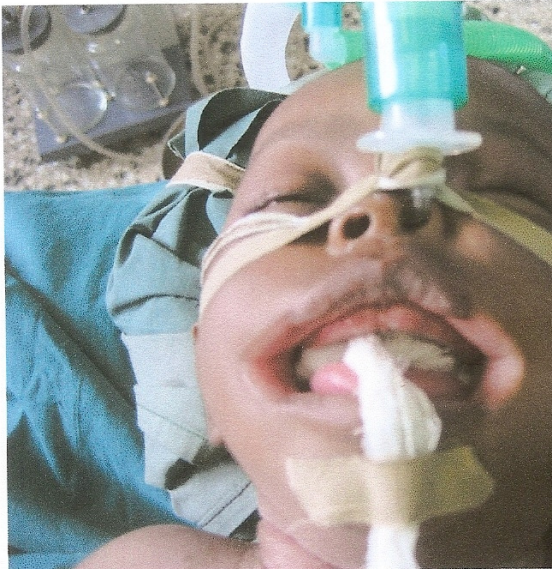

Figure 1. Pre-operative picture

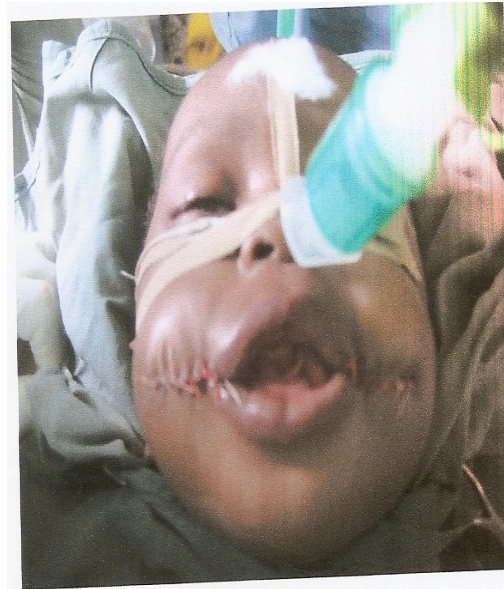

Figure 2. Immediate post operative picture

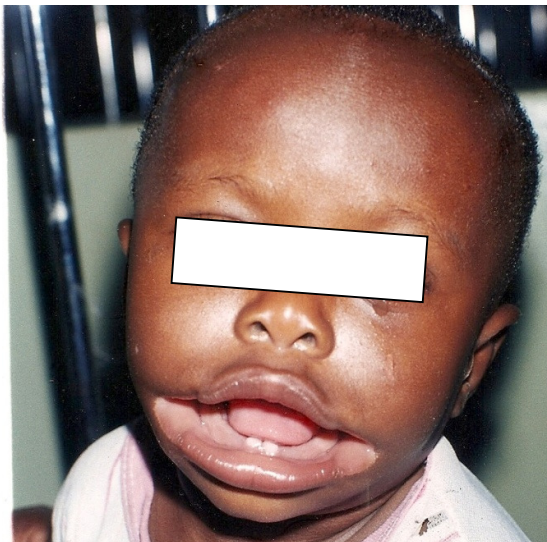

Figure 3. Pre-operative picture

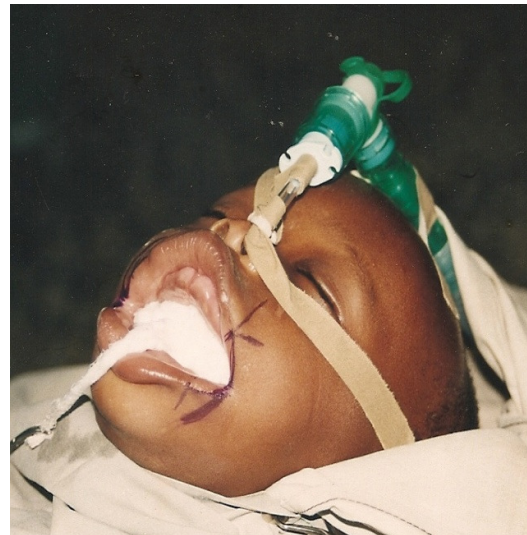

Figure 4. Intra operative Marking

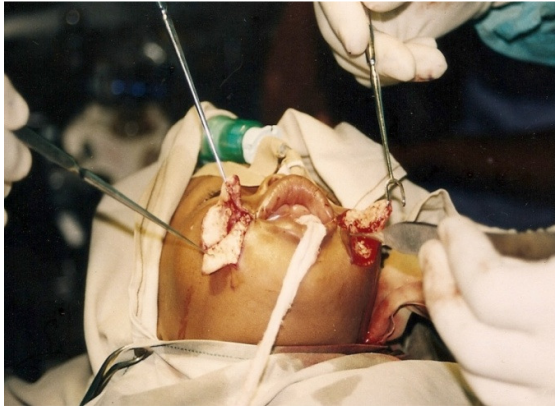


Figure 5. Intraoperative Z Plasty flaps

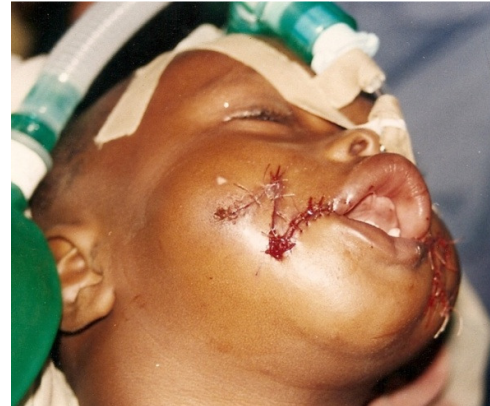

Figure 6. Immediate post operative picture.

Case 2

The second patient was a 15 month old male child who presented with bilateral facial cleft. He was delivered by spontaneous vaginal delivery following a term pregnancy at a peripheral clinic. His mother's pregnancy was uneventful and the child has had normal developmental milestone. His physical examination revealed bilateral facial cleft. He did not have any other anomaly. He also had normal haematological parameters and he had repair of the orbicularis muscle, closure of the mucosa layer and a Z plasty skin closure under general anaesthesia

Both patients had satisfactory post operative courses. The last follow visit of the first patient was three months post operation while that of the second patient was six months post operation.

Discussion

The surgical considerations for the repair of macrostomia is borne out of a proper understanding of the pathology of the defect which have been succinctly summarized by Ono and Tateshita⁹ as follows: the commissure of the mouth on the affected side is expanded and displaced inferolaterally in a cleft-like form, the disruption of facial expression muscles including the orbicularis muscle and finally the cleft of the oral mucosa. Hence any surgical option of repair should aim at achieving anatomical and functional as well as cosmetically acceptable closure.

Therefore the therapeutic goals of repair include the formation of symmetric lips and symmetric commissure of the mouth¹², the reconstruction of the orbicularis muscle of the mouth to restore labial function⁸, reconstruction of the natural-looking commissure of the mouth to produce a natural contour,¹³ the avoidance of extensive scarring and the prevention of future scar contracture with lateral migration of the commissure¹⁴. Although many surgical procedures have been introduced to achieve these therapeutic goals, no single procedure has been able to achieve all the set goals, therefore reconstructive surgeons select the most appropriate procedure for individual patients.

Of equal importance is the timing of repair. Early repair from the age of three months have been recommended to prevent sialorrhoea and leaking of food during chewing especially in patients with bilateral macrostomia. Early repair also prevents speech distortion; allay parents' fear and anxiety. It has also been reported that early repair prevents psychological and social problems¹⁵. One of the most popular and possibly the earliest option of skin closure is the Z plasty repair which was popularized by Boo-chan¹⁶; Mansfield and Herbert¹⁷; Torkut and Coskunfrat.² An advantage of Z-plasty is that the position of the commissure of the mouth can be adjusted to be the same as that on the unaffected side. It is also said to avoid scar contracture of the straight line closure and to provide better function of the oral sphincter.

The proponents of the straight line closure include Sugihara et al¹⁸, Yoshimura et al¹⁹, Kawai et al²⁰ and they cite the poor cosmetic appearance of the Z plasty as a major disadvantage. The straight line repair is said to be a simpler procedure with minimal scarring and better cosmetic appearance, however, with the straight line method, the commissure of the mouth tends to be retracted inferolaterally due to contracture and there is difficulty in adjusting the position of the commissure of the mouth. The scar contracture of the straight line closure has prompted recent modifications to the surgical techniques of macrostomia repair. The modifications include the refined simple line closure which involved the introduction of a mucosal triangular flap on the commissure region¹⁰ the use of the Vermilion square flap method (Eguchi et al¹⁴) and the use of two triangular flaps⁹. Long time follow up results of these newer techniques are still been awaited before conclusions can be drawn on their superiority to the older methods. The first patient in our series had the straight line closure while the second patient had the Z plasty repair.

The longest follow up period in both patients was six months. This did not give room for long term evaluation of the cosmetic appearance of the scar, however preliminary evaluation suggested that the cosmetic appearance of the patient that had Z plasty repair was significant compared with that of the patient with straight line repair. No residual dog ear or scar contracture was noticed in the patient that had the straight line closure.

References

1. Powell, W. J., and Jenkins, H. P. Transverse facial clefts: Report of three cases. *Plast. Reconstr. Surg.* (1969) 42: 454.
2. Torkut, A., and Coskunfirat, O. K. Double reversing Z-plasty for correction of transverse facial cleft. *Plast. Reconstr. Surg.*(1997) 99:885,
3. Askar, I., Gurlek, A., and Sevin, K. Lateral facial clefts (macrostoma). *Ann. Plast. Surg.* (2001) 47: 355.
4. May, H. Transverse facial clefts and their repair. *Plast. Reconstr. Surg.* (1962) 29: 240.
5. Bauer BS, Margulis A. Invited discussion of surgical repair for congenital macrostomia vermilion square flap method. *Ann Plast Surg.* (2001);47:328–329.
6. Bauer BS, Wilkes GH, Kernahan DA. Incorporation of the w-plasty in repair of macrostomia. *Plast Reconstr Surg.* (1982);70:752–757.
7. Longacre JJ, de Stefano G, Holmstrand KF. The surgical management of first and second branchial arch syndromes. *Plast Reconstr Surg* (1963); 1: 507
8. Nagai I, Weinstein I. Surgical repair of horizontal facial clefts. *J Oral Surg* (1963); 21: 251
9. Ono I and Tateshita T. New surgical technique for macrostomia repair with two triangular flaps. *PRS*, (2000) Vol 105(2) Feb, 688-694
10. Hikosaka M, Nakajima T, Ogata H, Miyamoto J. Refined simple line closure for macrostomia repair: Designing a mucosal triangular flap on the commissure region. *Journal of Cranio-Maxillofacial Surgery* (2009) 37, 341e343
11. Fadeyibi IO, Ugburo AO, Ogunbanjo CV, Ilombu CA, Ademiluyi SA .The Surgical Repair of Macrostomia: .Cleft Palate–Craniofacial Journal (2009), Vol. 46 No. 6; 642-647
12. McCarthy, J. G., Grayson, B. H., Coccaro, P. J., and Wood-Smith, D. Craniofacial Microstomia. In J. G. McCarthy (Ed.). *Plastic Surgery*. Philadelphia: Saunders, (1990) Pp. 3054–3100.
13. Stark, R. B., and Saunders, D. E. The first branchial arch syndrome: The oral-mandibular-auricular syndrome. *Plast. Reconstr. Surg.*(1992) 29:229,
14. Eguchi T, Asato H, Takushima A, Takato T, Harii K. Surgical repair for congenital macrostomia: Vermilion square flap method. *Ann Plast Surg* (2001);47:629-3
15. Akinmoladun V I,Owotade F J, and Afolabi A O . Bilateral Transverse Facial Cleft as an Isolated Deformity: Case Report. *Annals of African Medicine* (2007)Vol 6, No 1; 39 – 40
16. Boo-Chai, K. Transverse facial cleft: Its repair. *Br. J. Plast. Surg.* (1969) 22:119,.
17. Mansfield, O. T., and Herbert, D. C. Unilateral transverse facial cleft: A method of surgical closure. *Br. J. Plast. Surg.* (1972) 25:29,.



18. Sugihara, T., Ohura, T., Ishikawa, T., et al. Commissuroplasty for congenital macrostomia. *Jpn. J. Plast. Reconstr. Surg.* (1985) 28:404,
19. Yoshimura, Y., Nakajima, T., and Nakanishi, Y. Simple line closure for macrostomia repair. *Br. J. Plast. Surg.*(1992)45:604,.
20. Kawai, T., Kurita, K., Echiverre, N. V., et al. Modified technique in surgical correction of macrostomia. *Int. J. Oral Maxillofac. Surg.*(1998) 27:178,.