

## Management of Sudden Post-Operative Lung Collapse in Austere Environment: A case report

M.B.L. Lutomia<sup>1</sup>, D. Nott<sup>2</sup>;

<sup>1</sup>Egerton University, Medical School, Kenya

<sup>2</sup>Charing Cross Hospital, London.

*Correspondence to:* Dr. MBL Lutomia, Email: mlumbasi77@yahoo.com

We describe the management of a patient who sustained fragment injuries from a motor shelling blast, presenting to a field surgical hospital 12 hours later, with an isolated acute abdomen. Plain radiographs showed small fragments in the chest and abdomen, without pneumothorax or haemothorax. Laparotomy revealed an isolated cortical laceration of the lower pole of the right kidney with a peri-nephric hematoma. The hematoma was evacuated and a drain inserted. On the second post-operative day he developed respiratory distress, peripheral oxygen desaturation and reduced breath sounds on the right lung field. A plain film revealed complete opacity of the right lung field with tracheal shift to the right. A diagnosis of right lung collapse was made. Due to the presence of small fragments in the chest, the possibility of a haemothorax was considered. A right chest drain was inserted which drained nothing. A control film on table confirmed proper placement of the tube with collapsed right lung. The patient continued to de-saturate at 88%. Due to lack of a bronchoscope, tracheostomy was done under local anaesthesia to facilitate a good and strong cough reflex, followed by bronchial suction and lavage. Thick mucus plug was extracted, saline lavage done by instilling 10ml into the tracheostomy and suction, with good cough reflex from the patient. This was followed by a dramatic improvement in peripheral oxygen saturation to above 95%. Immediate control plain radiographs on table revealed a well expanded lung and the patient made an un-eventful recovery. Subsequent chest films showed complete resolution of the lung pathology.

### Introduction

Mucus plugging of the bronchi, causing post-operative lung collapse is well recognized complication of abdomino-thoracic surgery, and many other conditions which reduce or inhibit patient ability to expectorate or cough. Post-operative early mobilization, chest physiotherapy, and pain control are the measures used to prevent this complication. Rigid and flexible bronchoscopy, where available, is the standard treatment when the mucus plug fails to be dislodged. There are a few reports of successful suction through endotracheal tubes in patients who cannot withstand bronchoscopy. However the use of tracheostomy, inserted under local anaesthesia, provides an effective alternative to surgeons without bronchoscopy. It also offers a good chance to lavage the bronchi yet allowing the patient to assist by irritated cough reflex.

### Case presentation

An 18 year old male was hit by fragments after a mortar shelling attack on his village in an ongoing conflict situation. Multiple small fragments penetrated the patient's back, entering the chest and abdomen (Figure 1&2). The patient was fully conscious and complained of severe abdominal pain. Blood pressure, respiration and urine, were normal. The abdomen was rigid, tender and silent on auscultation. Plain films revealed small shrapnel in the chest, and larger ones across the right lumbar area. There was no clinical or radiographic evidence of haemothorax or pneumothorax.

Laparotomy was carried out revealing a cortical laceration in the lower pole of the right kidney with a perinephric hematoma that was inactive. The haematoma was evacuated, kidney area cleaned and a drain left in place. All other abdominal organs were normal and the abdomen was closed. The small entry wounds on the back were debrided and dressed. Post-operatively, he was treated with Ampicillin 1gm

four times daily, Metronidazole (Flagyl<sup>R</sup>) 500mg thrice daily, Pentazocin 30mg thrice daily and Paracetamol 1gm thrice daily. Chest exercises were started the following day while patient was on 3L of Lactated Ringer intravenously. His abdominal recovery was uneventful, drain being removed after 36hours and liquid nutrition started on the second day post-operative. On the third day post-operatively, it was noted that there were decreased breath sounds on the right lower chest and the patient could only maintain peripheral saturations of oxygen when on 4 litre of oxygen by mask. Otherwise he was tachypnoic and de-saturating to 88%. A plain radiograph was ordered, revealing a white shadow over the whole right lung field, with deviation of the trachea across the midline to the right (Figure 3). A diagnosis of lung collapse was made, with a possible haemothorax deferential diagnosis due to the shrapnel in the chest.

A chest tube was inserted into the right pleural space, and when it did not drain anything, lung collapse due to mucus plug was suspected. A plain film done on table demonstrated the lung collapse with proper tube placement (Figure 4). A tracheostomy tube size 8mm was inserted under local anaesthesia. Through the tracheostomy tube, bronchial suction was done, alternating with 10ml normal saline lavage. Thick mucus plug was extracted by suction, with dramatic improvement of the peripheral oxygen saturation of the patient, from persistently below 88%, to above 96% within few minutes of plug evacuation. An immediate radiograph demonstrated complete re-expansion of the lung with clearance of the white shadow (Figure 5). Thereafter, he made an uneventful recovery, maintaining his lung expansion in all radiographs done later (Figure 6), and clinically remaining asymptomatic. The tracheostomy and Chest tube were removed after three days and patient discharged one week later with no chest or abdominal complaints.

## Discussion

Post-operative atelectasis is probably the commonest pulmonary complication after abdominal surgery (1). Restricted respiratory movements and mucus plugging are the major causes of this condition. Most often, pain relief, and chest physiotherapy is able to prevent major segmental or lobar collapse by helping expectorate the secretions.

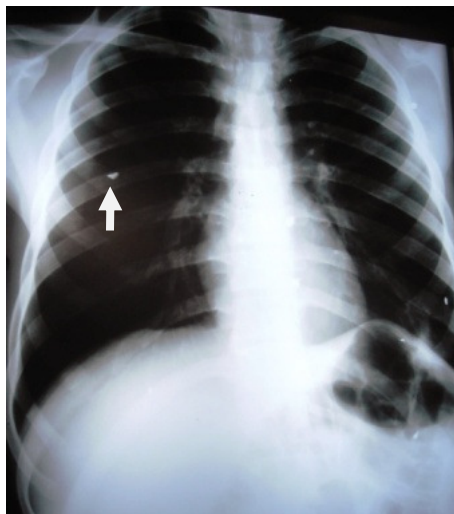
It has been reported that collapse of the lobe or whole lung is common on the left side, probably due to the obliquity of the left bronchi making clearance of secretions harder from the left lung or due to the likely intubation of the right main bronchus (2-4). In this patient however, the right lung was involved. During bronchial lavage through the tracheostomy, this is an advantage because it is anatomically easier to get the suction tube into the right main bronchus. It is also practically easier to get saline into the bronchi, and suction it out, thereby facilitating softening and suction of the mucus plug.

The role of bronchoscopy in mucus plug clearance is well established (5); however, in centres which lack this facility, simple methods like use of endotracheal tubes (6) or tracheostomy to clear the bronchus may be employed with dramatic success. It is technically challenging to lavage through endotracheal tubes and suction in quick sequence, compared to the ease of using a tracheostomy. This is important because the patient oxygenation must be closely observed as was done in this case, to prevent severe organ hypoxia. The use of local anaesthesia to insert the tracheostomy facilitated the patient to cough and expectorate the mucus through irritation by the suction tube. Obviously, if the reflex was blunted by general anaesthesia, the advantage of cough would have been missed. Once lung collapse has been detected and suspicion of mucus plugging entertained, prompt insertion of the tracheostomy and lavage through the tube is an effective method of treating this condition.

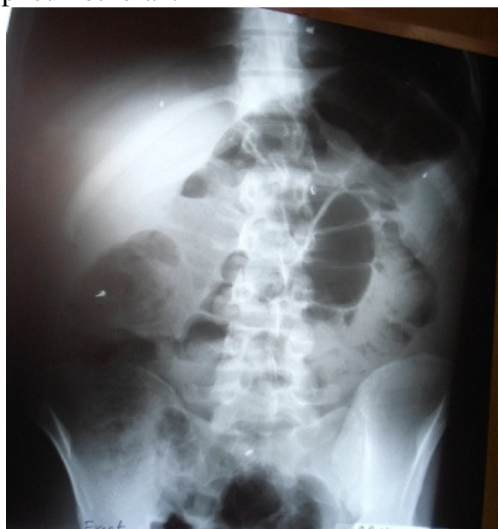Good post-operative evaluation of chest symptoms, peripheral saturation monitoring and plain film, can help detect partial or complete lung collapse. We recommend that if non-operative methods like rehydration and chest physiotherapy fail, tracheostomy, followed by bronchio-alveolar lavage, may be

considered as a good alternative to clear the mucus plug, and followed by control films to confirm lung expansion which should happen quickly if the diagnosis is correct and treatment effective. Besides, the use of tracheostomy offers chances to perform bronchial lavage in quick succession as the saturation is monitored. Alternating larger and smaller suction tubes can certainly help to remove all the secretions up to the smaller bronchi.

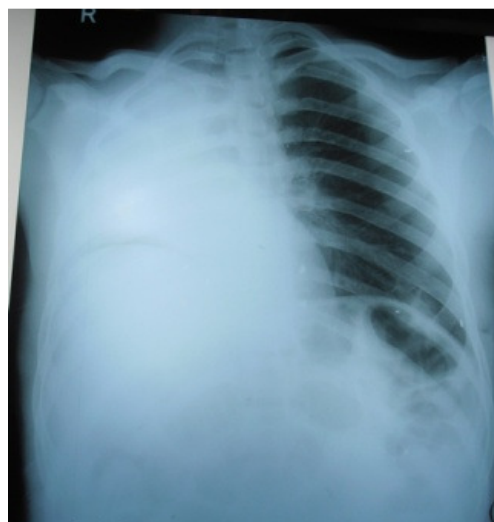It is true that due to the inability to manoeuvre the tube, blockage of upper lobes of the lung may be hard to unblock, however the good cough reflex obtained by the tracheostomy suctioning, coupled with the lavage may still dislodge the plug and enable its evacuation.



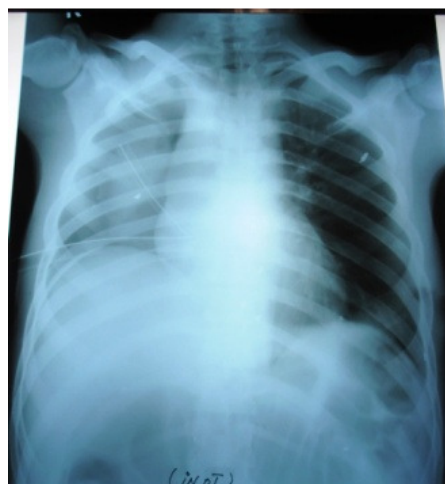**Figure 1.** Initial radiograph shows shrapnel inside chest with no haemothorax or pneumothorax.



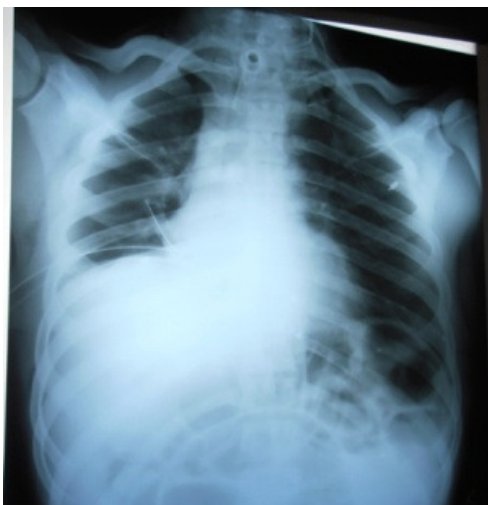**Figure 2.** Abdominal radiograph showing shrapnel inside the right upper quadrant.



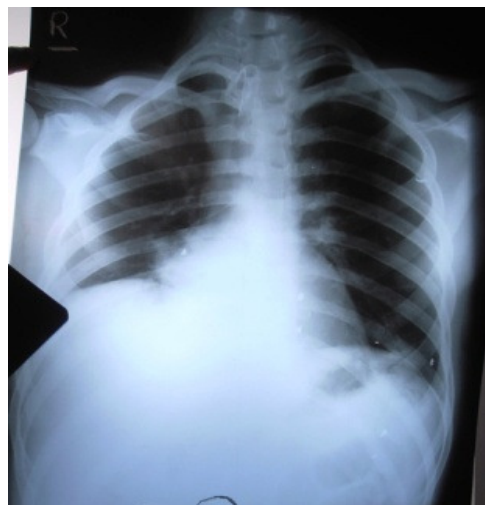**Figure 3.** Plain radiograph of chest shows complete opacity of right lung field with tracheal deviation to the right.



**Figure 4.** Radiograph on table demonstrates collapsed right lung with intra-pleural chest tube.



**Figure 5.** On table radiograph after tracheostomy and bronchial lavage shows re-expanded right lung.



**Figure 6.** Three days after, Lung still expanded.

## Conclusion

Lung collapse due to mucus plug is a common complication of abdominal and thoracic surgery. Prompt recognition of this complication is important to reverse the atelectasis that soon follows this complication. Failure to recognize this complication early may lead to partial or total lung collapse with severe respiratory distress and even death. Non operative measures including good pain relief, early mobilization, mucolytic medication and chest physiotherapy are usually successful if employed early. In some patients where this approach is not successful, bronchoscopy is still the gold standard intervention. However, this case confirms that tracheostomy is an effective and easy way to manage post-operative lung collapse due to mucous plug, and done under local anaesthesia, presents an attractive alternative to bronchoscopy in austere environments.

## References

1. Goodwin JF: Post-Operative Pulmonary Atelectasis; *Br. J. Anaesth.*20(1):11-23, 1946
2. Nevin KC, Jojoy G: Post-Operative Entire Left Lung Collapse by Mucus Plug; *The Indian Anaesthetist Forum*,2007
3. Gurjar M, Singhal S et al: Collapse of Left Lung after Endotracheal Intubation: Is it always due to misplacement of tube? *J Emerg Trauma Shock* 3:305, 2010
4. Ghosh P: Why Mucous Plugs Commonly cause Left Lung Collapse? *Ind.J Ped;*54(4):583-6, 1987
5. Kreider ME, Lipson DA: Bronchoscopy for Atelectasis in the ICU: A case report and Review of Literature; *Chest.* 124(1): 344-50, 2003
6. Muhammad S, Riaz AK et al: Bronchopulmonary Lavage and Re-expansion of the Atelectatic Lung without Bronchoscopy- Case Report. *An Int. J Anaesth. Pain Intens. Care;* 15(3), 2012